



## PATIENT

Albus Sokolov

## SPECIES

Feline

## BREED

Domestic Longhair

## SEX

Neutered male

## AGE

16 years

## WEIGHT

8.9 lbs

## INTERPRETED BY

Eric Lindquist, DMV  
DABVP, Cert. IVUSS

## IMAGING PERFORMED BY

Dr. Klein

## HOSPITAL NAME

Alison AH

## REFERRING VET

Dr. Klein

## INVOICE

75300

## DATE

5/11/26

## PRESENTING CLINICAL SIGNS

History: Pt is presented for AUS and echo. Pt has a grade II/VI HM. Diagnosed with HCM July 2025. No medication. No lethargy. No coughing.

## PRE-ANESTHETIC ECHOCARDIOGRAM

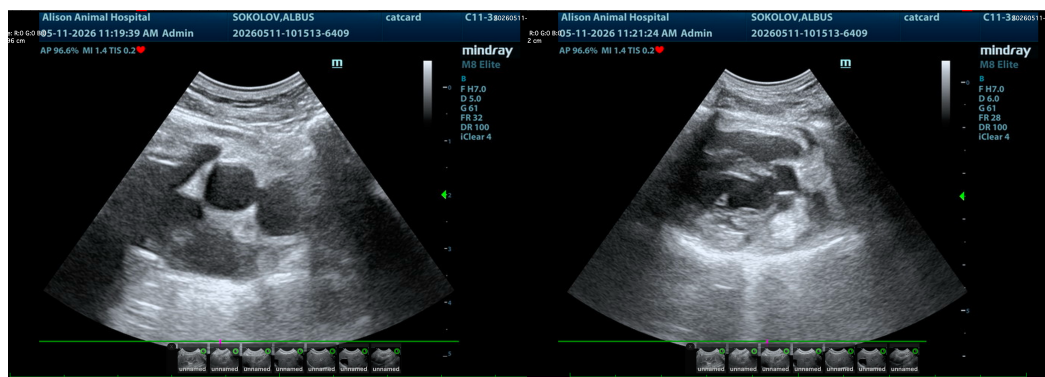
8 efficiency video clips from SDEP protocol provided.

All four chambers revealed normal volumes and contractility. No pericardial or pleural effusion noted. o gross abnormalities that would preclude anesthesia.

## INTERPRETATION OF THE FINDINGS & FURTHER RECOMMENDATIONS

Volume restitution is recommended prior to anesthesia. **Anesthetic risk is considered normal to mild:** No gross abnormalities noted on SDEP<sup>R</sup> Screening Echo to contraindicate anesthesia. Minimal to no left atrial enlargement noted on images presented.

1. However, judicious fluid administration is advised with careful RR/RE monitoring to screen for fluid overload.
2. Monitoring of blood pressure, SpO<sub>2</sub>, CO<sub>2</sub>, and auscultation of heart and lungs during anesthesia should be done during every procedure.



The information and recommendations provided are based on the images presented by the referring veterinarian/sonographer. No evaluation can be communicated regarding pathology that was not visible in the image/video clips provided.

Thank you for this referral. If the clinical or image interpretation does not parallel your findings or if I can be of any further assistance please contact me.

Eric Lindquist, DMV, DABVP (CFM), Cert. IVUSS, CEO of SonoPath.com

[info@SonoPath.com](mailto:info@SonoPath.com)