



PATIENT

Abi Thompson

SPECIES

Canine

BREED

Terrier Mix

SEX

Spayed Female

AGE

9 Years 11 Months

WEIGHT

6.48 Pounds

INTERPRETED BY

Eric Lindquist, DMV,
DABVP (Canine &
Feline), Cert. IVUSS

IMAGING PERFORMED BY

Dr. Laura Klaassen

HOSPITAL NAME

ACG of Lake Oswego

REFERRING VET

Dr. Laura Klaassen

INVOICE

37080

DATE

5/11/26

PRESENTING CLINICAL SIGNS

History: heart murmur louder - grade 5/6, chest rad show possible enlarged LA, episode of seizure like tremors. Abnormal PE/Chem/CBC/UA Results: anisocoria L sided systolic grade 5/6 murmur.

ULTRASONOGRAPHIC EXAMINATION OF THE HEART

CANINE CARDIAC PARAMETERS	MR VMAX (m/s)	TR VMAX (m/s)	LA/AO (M-Mode)	LA/AO (Heart Base; Swe)	FS (%)	EF (%)	EPSS (cm)
NORMAL PARAMETER	4.5-5.5	<2.7	1.3	Up to 1.6	28-40	40-100	<0.6
PATIENT	--	--	1.3	1.43	62	91	0.1
CANINE CARDIAC PARAMETERS	HR (BPM)	AV VMAX (m/s)	PV MAX (m/s)	BODY WEIGHT (lbs)	LAD LA MAX 4 Chamber	LVIDd Avg; 2D and m-mode short axis (cm)	LVIDs Avg; 2D and m-mode short axis (cm)
NORMAL PARAMETER	50-100	0.7-1.7	0.7-1.6				
PATIENT	--	--	--	6.48	2.7	2.77	--

Cardiac Presentation

The echocardiogram in this patient demonstrated normal **left atrial** size based on 3 different LA measurement methods. Chamber volumes and echogenicity were normal. Slight prolapse of the anterior mitral valve leaflet was noted. Doppler indicated measurable insufficiency. The **left ventricle** presented thicknesses with linear contour and was not dilated nor restricted. The **myocardium** presented normal echogenicity without subjective evidence of significant fibrotic or ischemic disease. **Contractility** of the ventricular walls was adequate and in normal range for this patient evidenced by the fractional shortening measurement and subjective evaluation of the different regions of the myocardium. The **left ventricular outflow** tract demonstrated normal laminar flow and subjective structural integrity. The **right atrium** and auricle revealed normal size, structure and content. No evidence of masses was noted or chamber overload. **Tricuspid** valvular assessment demonstrated adequate linear morphology. The **right ventricle** was of normal size (1/3 diameter of LV), chordae structure, myocardial echogenicity and thickness. **Pulmonic** tract assessment revealed normal valve structure, laminar flow, and diameter (approx. 1:1 pa/ao ratio). No visible **pericardial** or free pleura fluid was noted. No echographically detectable evidence of infiltrative disease was visible. The cranial **mediastinum and pericardial regions** were free of masses in the visible window.

ULTRASONOGRAPHIC FINDINGS



PATIENT

- Stage B-1 valvular disease with slight mitral valve prolapse

Abi Thompson

INTERPRETATION OF THE FINDINGS & FURTHER RECOMMENDATIONS

SPECIES

The seizure episodes are not likely related to the cardiac presentation. Given the patient history, skull and cervical CT with contrast is indicated.

Canine

BREED

The heart is stable without clinical disease. No overt contraindication for anesthesia of brief to moderate duration. I suggest Torbutrol premed, Propofol induction, Isoflor maintenance or similar protocol if anesthesia is desired. Blood pressure recommended if not already performed and target white coat negative systolic pressure of < 160 mmHg. If higher than this ACE-inhibitor is suggested to reach this level. Recheck echocardiogram is recommended in 6 months, earlier if murmur grade increases or clinical signs initiate.

Terrier Mix

SEX

Spayed Female

AGE

9 Years 11 Months

WEIGHT

6.48 Pounds

INTERPRETED BY

Eric Lindquist, DMV,
DABVP (Canine &
Feline), Cert. IVUSS

IMAGING PERFORMED BY

Dr. Laura Klaassen

HOSPITAL NAME

ACG of Lake Oswego

REFERRING VET

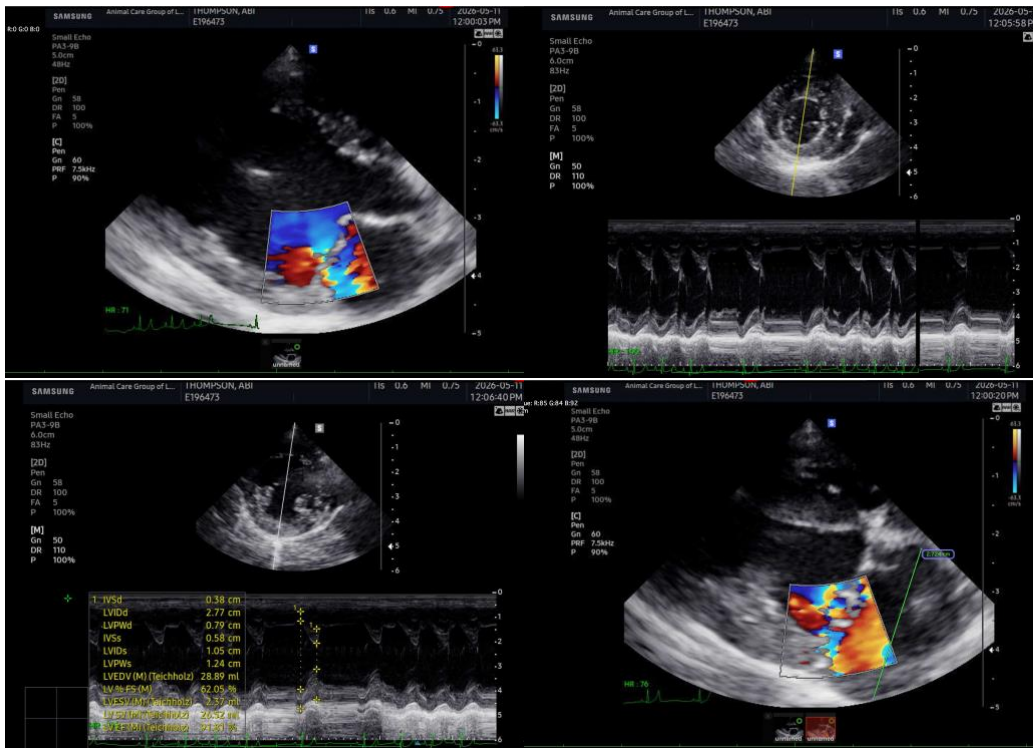
Dr. Laura Klaassen

INVOICE

37080

DATE

5/11/26





PATIENT

Abi Thompson

SPECIES

Canine

BREED

Terrier Mix

SEX

Spayed Female

AGE

9 Years 11 Months

WEIGHT

6.48 Pounds

INTERPRETED BY

Eric Lindquist, DMV,
DABVP (Canine &
Feline), Cert. IVUSS

IMAGING PERFORMED BY

Dr. Laura Klaassen

HOSPITAL NAME

ACG of Lake Oswego

REFERRING VET

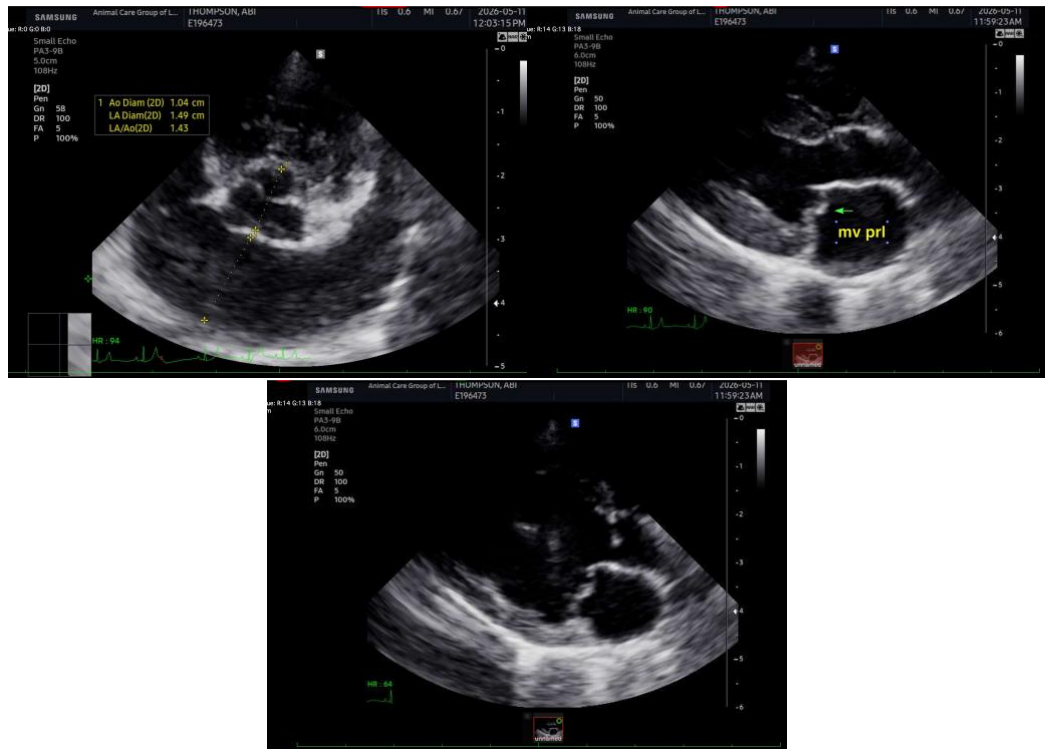
Dr. Laura Klaassen

INVOICE

37080

DATE

5/11/26



The information and recommendations provided are based on the images presented by the referring veterinarian/sonographer. No evaluation can be communicated regarding pathology that was not visible in the image/video clips provided.

Thank you for this referral. If the clinical or image interpretation does not parallel your findings or if I can be of any further assistance please contact me.

Eric Lindquist, DMV, DABVP(CFM), Cert. IVUSS,
CEO, Owner, Founder -- SonoPath.com
info@SonoPath.com