



PATIENT PRESENTING CLINICAL SIGNS

Justice Gibson Irregular, Bradycardia, HB 50/min or less

SPECIES ULTRASONOGRAPHIC EXAMINATION OF THE HEART

Canine

BREED

King Charles Spaniel

SEX

Neutered Male

AGE

10 Years

WEIGHT

30

CANINE CARDIAC PARAMETERS	MR VMAX (m/s)	TR VMAX (m/s)	LA/AO (Boon method)	LA/AO (Heart Base; Swe)	FS (%)	EF (%)	EPSS (cm)
NORMAL PARAMETER	4.5-5.5	<2.7	1.3	<1.3	28-40	40-100	<0.6
PATIENT	6.20	--	1.3	1.3	--	--	NM
CANINE CARDIAC PARAMETERS	HR (BPM)	AV VMAX (m/s)	PV MAX (m/s)	BODY WEIGHT (kg)	LA 2D short axis Base view (cm)	LVIDd Avg; 2D and m-mode short axis (cm)	LVIDs Avg; 2D and m-mode short axis (cm)
NORMAL PARAMETER	50-100	0.7-1.7	0.7-1.6				
PATIENT	--	1.87	1.10	--	3.16	3.7	--

Cardiac Presentation

The left atrium measured the upper limits of normal in this patient yet likely secondary to the bradyarrhythmia. Moderate filling of the left atrium was noted. Doppler indicated moderate mitral insufficiency. The **left ventricle** presented thicknesses with linear contour and was not dilated nor restricted. The **myocardium** presented normal echogenicity without subjective evidence of significant fibrotic or ischemic disease. **Contractility** of the ventricular walls was adequate and in normal range for this patient evidenced by the fractional shortening measurement and subjective evaluation of the different regions of the myocardium. The **left ventricular outflow** tract demonstrated normal laminar flow and subjective structural integrity. The **right atrium** and auricle revealed normal size, structure and content. No evidence of masses was noted or chamber overload. **Tricuspid** valvular assessment demonstrated adequate linear morphology. The **right ventricle** was of normal size (1/3 diameter of LV), chordae structure, myocardial echogenicity and thickness. **Pulmonic** tract assessment revealed normal valve structure, laminar flow, and diameter (approx.1:1 pa/ao ratio). No visible **pericardial** or free pleura fluid was noted. No echographically detectable evidence of infiltrative disease was visible. The cranial **mediastinum and pericardial regions** were free of masses in the visible window. Bradyarrhythmia was noted in this patient. Holter monitor is indicated, this may be obtained from our office with cardiologist review. Potential pace maker may be necessary.

ULTRASONOGRAPHIC FINDINGS

- Stage B-1 valvular disease

INTERPRETATION OF THE FINDINGS & FURTHER RECOMMENDATIONS

INVOICE

22461

DATE

5/11/23

INTERPRETED BY

Eric Lindquist, DMV
DABVP, Cert. IVUSS

IMAGING PERFORMED BY

Eric Lindquist, DMV
DABVP, Cert. IVUSS

HOSPITAL NAME

All Creatures Great and Small, Denville

REFERRING VET

Dr. Mitrovic



PATIENT

Justice Gibson

SPECIES

Canine

BREED

King Charles Spaniel

SEX

Neutered Male

AGE

10 Years

WEIGHT

30

INTERPRETED BY

Eric Lindquist, DMV
DABVP, Cert. IVUSS

IMAGING PERFORMED BY

Eric Lindquist, DMV
DABVP, Cert. IVUSS

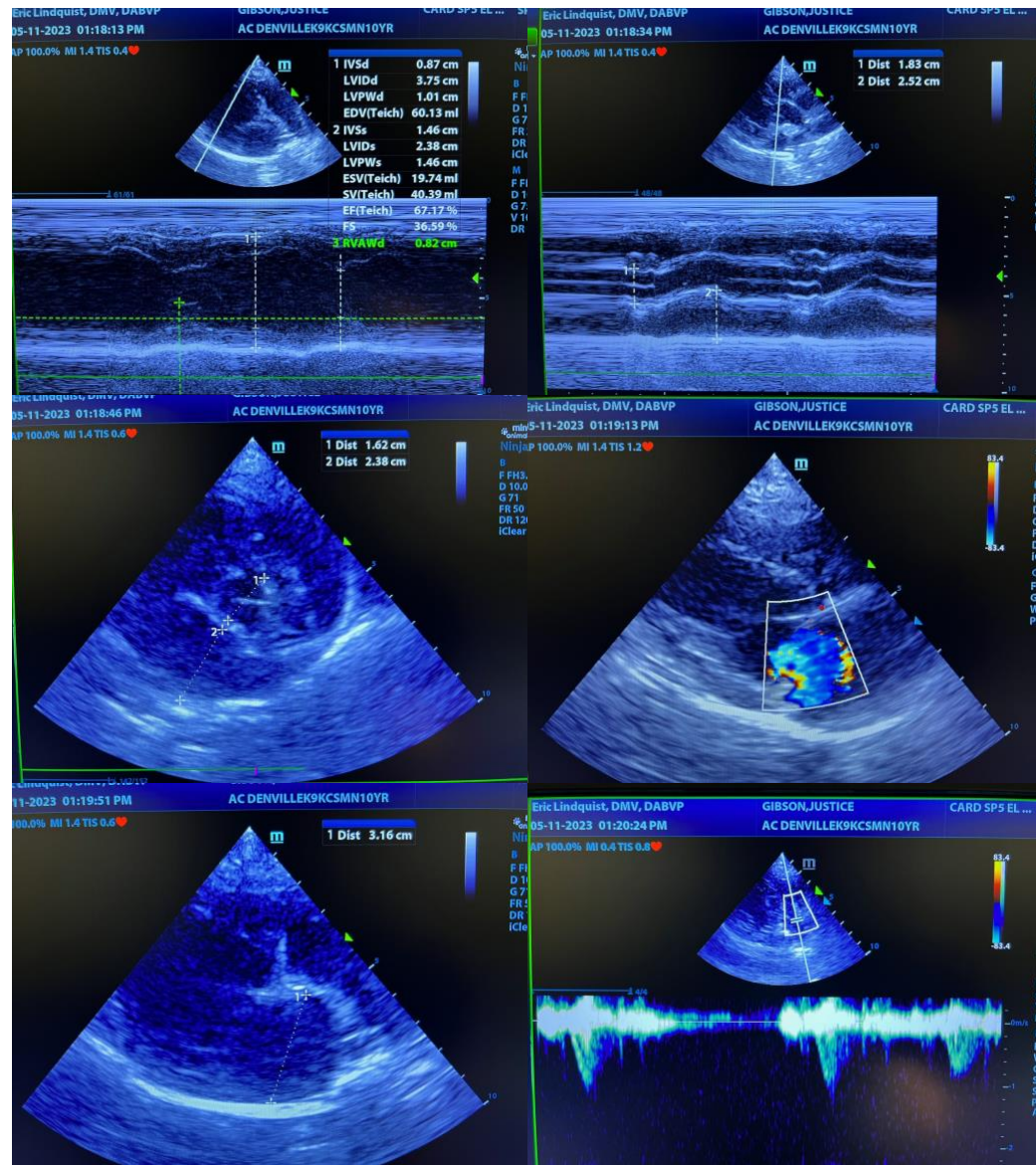
HOSPITAL NAME

All Creatures Great and
Small, Denville

REFERRING VET

Dr. Mitrovic

The heart is stable without clinical disease. No overt contraindication for anesthesia of brief to moderate duration. I suggest Torbutrol premed, Propofol induction, Isoflor maintenance or similar protocol if anesthesia is desired. Blood pressure recommended if not already performed and target white coat negative systolic pressure of < 160 mmHg. If higher than this ACE-inhibitor is suggested to reach this level. Recheck echocardiogram is recommended in 6 months, earlier if murmur grade increases or clinical signs initiate. Baseline cortisol or ACTH stimulation test is recommended to rule out Addisons that may be influencing the bradycardia.



INVOICE

22461

DATE

5/11/23



PATIENT

Justice Gibson

SPECIES

Canine

BREED

King Charles Spaniel

SEX

Neutered Male

AGE

10 Years

WEIGHT

30

INTERPRETED BY

Eric Lindquist, DMV
DABVP, Cert. IVUSS

**IMAGING
PERFORMED BY**

Eric Lindquist, DMV
DABVP, Cert. IVUSS

HOSPITAL NAME

All Creatures Great and
Small, Denville

REFERRING VET

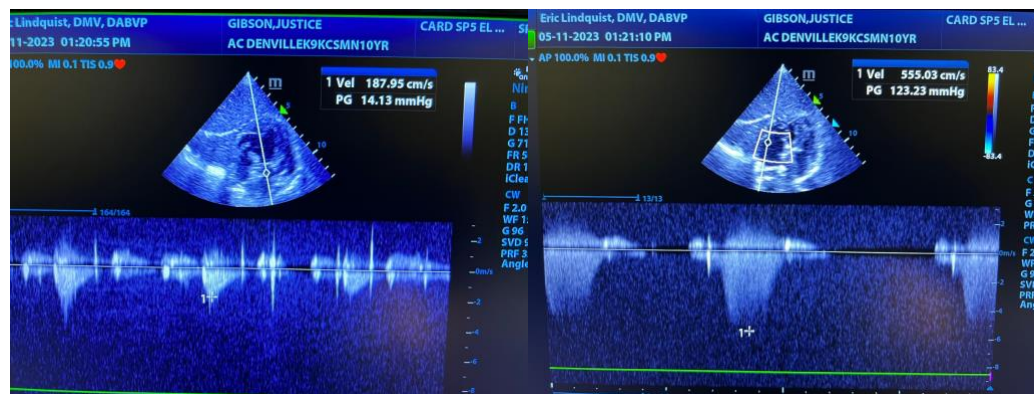
Dr. Mitrovic

INVOICE

22461

DATE

5/11/23



The information and recommendations provided are based on the images presented by the referring veterinarian. No evaluation can be communicated regarding pathology that was not visible in the image/video clips provided.

Thank you for this referral. If the clinical or image interpretation does not parallel your findings or if I can be of any further assistance please contact me.

Eric Lindquist, DMV, DABVP, Cert. IVUSS, CEO of SonoPath.com
info@SonoPath.com