



**PATIENT**

Bruno Salerno

**SPECIES**

Canine

**BREED**

Rotti/Mix

**SEX**

Neutered Male

**AGE**

6

**WEIGHT**

130

**INTERPRETED BY**

Eric Lindquist, DMV  
DABVP, Cert. IVUSS

**IMAGING PERFORMED BY**

Eric Lindquist, DMV  
DABVP, Cert. IVUSS

**HOSPITAL NAME**

Franklin lakes AH

**REFERRING VET**

Dr. Kozak

**INVOICE**

22458

**DATE**

5/11/23

**PRESENTING CLINICAL SIGNS**

Elevated liver enzymes (progressive)

CBC/Chem findings: Jan ^ALT 244/today 422 (here for dental procedure)

**ULTRASONOGRAPHIC EXAMINATION OF THE ABDOMEN**

**Urinary System**

The **urinary bladder**, trigone, and pelvic urethra presented normal thicknesses and normal tone. The ureters were not visible which is normal. No uroliths or sediment were visualized and anechoic urine was present. No evidence of inflammatory or neoplastic changes were noted. Ureteral papillae were normal.

The **kidneys** revealed normal size and structure, corticomedullary definition and ratio for this age. The cortices presented largely uniform texture with normal echogenic relationship to liver and spleen. Medullary structure differed distinctly from the cortex and no evidence of pelvic dilation was present. The capsules were acceptably uniform without significant irregularities. The left kidney measured 7.45 cm. The right kidney measured 7.16 cm.

**Adrenal Glands**

Both **adrenal glands** were visualized and recognized as having normal shape, size, position and echogenicity for this breed. The phrenic vasculature, glandular echogenicity and detail were unremarkable. Capsule, cortex, and medullary definition were normal for this age patient. The left adrenal gland measured 2.76 cm x 0.56 cm. The right adrenal gland measured 2.17 cm x 1.31 cm at the cranial pole and 0.8 cm at the caudal pole.

**Spleen**

The **spleen** was largely uniform with a hypoechoic (1.92 cm) nodule at the caudal pole of the spleen with mild disruption of architecture.

**Liver**

The **liver** presented heterogenous parenchyma with increased portal markings and coarse architecture. Slight undulating capsular contour was noted. The gallbladder and common bile duct were unremarkable. This is consistent with chronic inflammatory hepatopathy. This is a moderate change.

**Gastrointestinal**

Examination of the **gastrointestinal tract** revealed a stomach and intestine free of stasis, of normal wall thickness, acceptable curvilinear mural detail, and peristaltic activity. Small and large intestine demonstrated normal luminal chyme d stool consistency respectively. No obstructive or overt infiltrative disease was noted. No associated abnormal lymphatic activity was noted.

**Pancreas**

The base and limbs of the **pancreas** were observed to be largely isoechoic to surrounding omental fat. Pancreatic duct and capsular contour were acceptably normal and parenchyma respected normal curvilinear patterns. No overt evidence of active inflammatory or neoplastic disease was noted.

**ULTRASONOGRAPHIC FINDINGS**



**PATIENT**

Bruno Salerno

- Chronic inflammatory hepatopathy
- Splenic nodule

**SPECIES**

Canine

**BREED**

Rotti/Mix

**SEX**

Neutered Male

**AGE**

6

**WEIGHT**

130

**INTERPRETED BY**

Eric Lindquist, DMV  
DABVP, Cert. IVUSS

**IMAGING PERFORMED BY**

Eric Lindquist, DMV  
DABVP, Cert. IVUSS

**HOSPITAL NAME**

Franklin lakes AH

**REFERRING VET**

Dr. Kozak

**INVOICE**

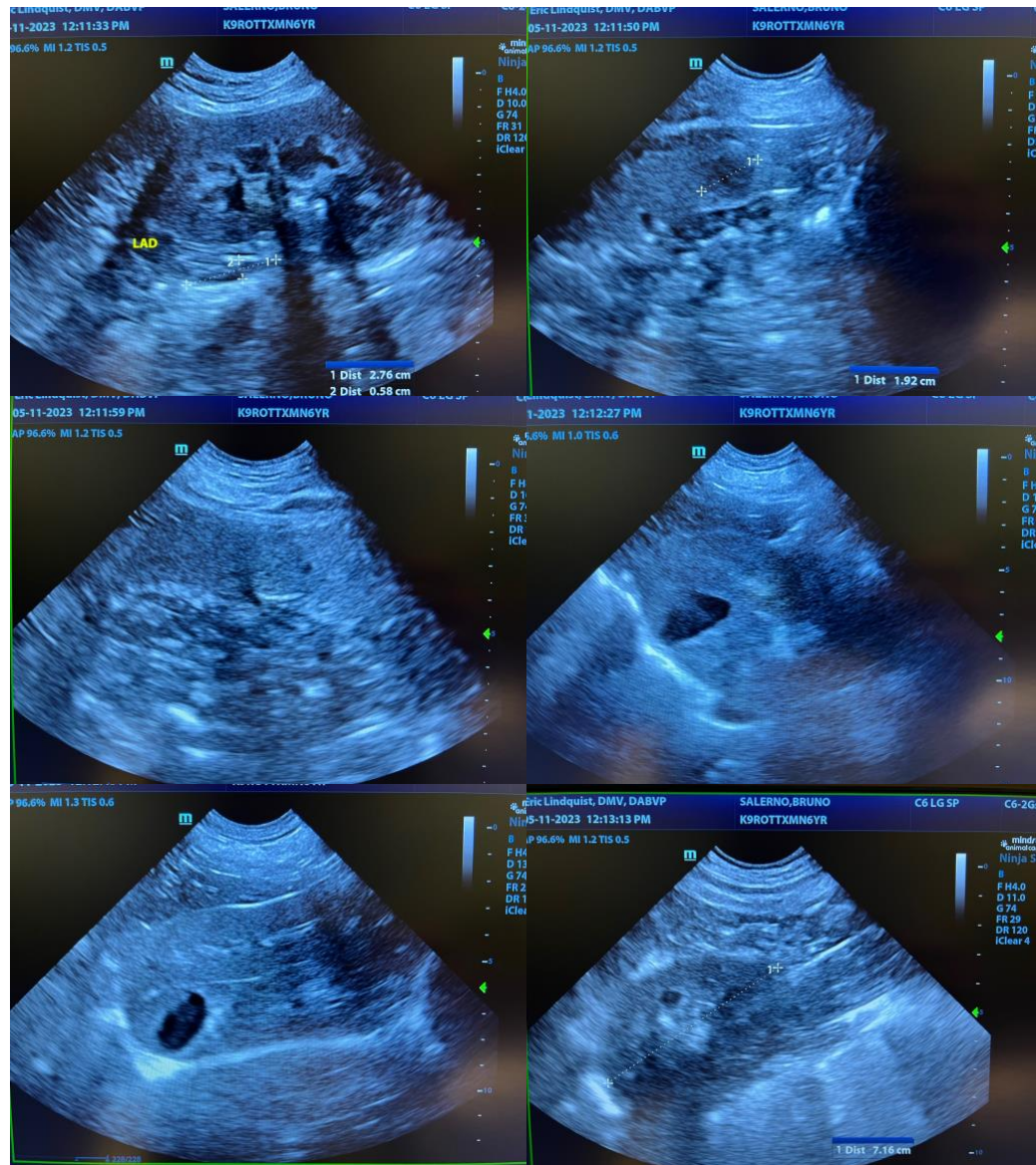
22458

**DATE**

5/11/23

**INTERPRETATION OF THE FINDINGS & FURTHER RECOMMENDATIONS**

There is potential underlying copper storage disease. Copper assessment is recommended. Underlying occult leptospirosis should be ruled out with leptospirosis titers. Coagulation panel with Von Willebrands factor evaluation is recommended with core biopsy of the liver and FNA of the splenic nodule. Bile acid profile is warranted. Liver oriented diet is warranted. No evidence of neoplasia unless the splenic nodule is an emerging neoplastic event. Differentials on the splenic nodule include emerging round cell neoplasia, hemangiosarcoma (less likely), hyperplasia or abscessation (less likely).





**PATIENT**

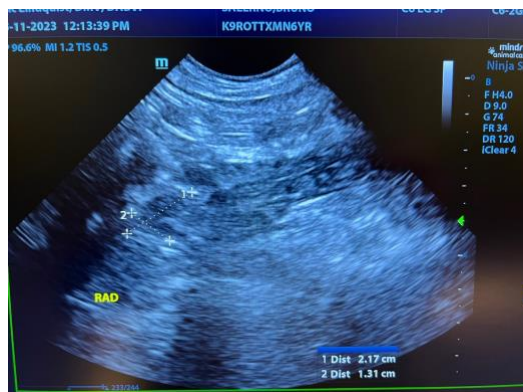Bruno Salerno

**SPECIES**

Canine

**BREED**

Rotti/Mix



**SEX**

Neutered Male

The information and recommendations provided are based on the images presented by the referring veterinarian. No evaluation can be communicated regarding pathology that was not visible in the image/video clips provided.

**AGE**

6

Thank you for this referral. If the clinical or image interpretation does not parallel your findings or if I can be of any further assistance please contact me.

**WEIGHT**

130

Eric Lindquist, DMV, DABVP, Cert. IVUSS, CEO of SonoPath.com  
info@SonoPath.com

## Canine Liver Disease & Treatment Recommendations

**INTERPRETED BY**

Eric Lindquist, DMV  
DABVP, Cert. IVUSS

<http://www.sonopath.com/K9LiverDisease>

**Description:** The etiologic causes of canine hepatic disease are vast and varied. Some cases may progress fairly rapidly, while others will remain static for a considerable length of time or even eventually reverse. Regardless of the cause, management is crucial to maintaining and optimizing quality of life. If possible, practitioners should obtain and be guided by a pathologic diagnosis so they can administer a treatment attuned to the underlying disease and arrive at a more exact prognosis.

**IMAGING PERFORMED BY**

Eric Lindquist, DMV  
DABVP, Cert. IVUSS

**Dietary Management:** A lower protein diet to support liver dysfunction should be initiated, especially in cases where hepatic encephalopathy is also present. Since dietary protein is low, the protein quality and bioavailability must conversely be high. It should be noted that a protein-restricted diet is not appropriate in all cases of hepatic disease, especially during the early phases, as protein restriction is unnecessary when there are no signs of significant hepatic dysfunction.

**HOSPITAL NAME**

Franklin lakes AH

Therapeutic diets, such as Hill's® i/d® and Royal Canin® Hepatic™, are excellent choices and contain enhanced levels of nutrients such as, but not limited to:

**REFERRING VET**

Dr. Kozak

- Branched chain amino acids, which bypass liver metabolism and are used directly for skeletal muscle accretion.
- Vitamin E, which helps minimize and reduce oxidative damage and stress from free radicals produced by stressed hepatocytes.
- Vitamin B complex, which helps drive intermediary metabolism.
- Reduced copper.
- Extremely digestible protein sources with high biologic values, which help minimize the total amount of dietary protein needed and thus reduce blood ammonia levels.

**INVOICE**

22458

**DATE**

5/11/23



**PATIENT**

Bruno Salerno

- Carnitine, which helps drive fatty acids into the mitochondria for beta-oxidation and positive cellular energy balance.

**SPECIES**

Canine

**Medical Management:** The following list of medications is commonly used in the management of various hepatopathies or in the face of hepatic failure; however, each patient should be managed as an individual, and not all of the medications listed here are appropriate for each animal. One must always consider the definitive diagnosis of one's patient when developing a therapeutic plan. What follows is an outline of medical management recommendations for cholangiohepatitis and inflammatory hepatopathy/chronic hepatitis.

**BREED**

Rotti/Mix

**Cholangiohepatitis**

**SEX**

Neutered Male

*1. Broad-spectrum antibiotics*

a) Amoxicillin: Give 20 mg/kg BID or amoxicillin/clavulanic acid (13.75 mg/kg PO BID) for potential suppurative hepatitis. Options: ampicillin: 20 mg/kg IV TID; cephalexin: 20 mg/kg IV or PO TID; enrofloxacin: 2.5-5 mg/kg PO BID if cholangiohepatitis is present or to decrease ammonia production; gentamycin: 2 mg/kg TID IM or SC for 5-7 days if sepsis or peritonitis is present. Monitor renal function if aminoglycosides are utilized.

**AGE**

6

b) Metronidazole: Give 10-20 mg/kg BID in combination with amoxicillin/clavulanic acid or enrofloxacin for cholangiohepatitis because of its efficacy against anaerobic bacteria and/or for its immunomodulating effects. The dose is decreased to 7.5 mg/kg PO TID in the face of hepatic failure and/or encephalopathy. Controls ammonia production in the colon, decreases bacteria absorbed through portal circulation, and reduces cell-mediated immune responses (anti-inflammatory properties).

**WEIGHT**

130

*2. Hepatic support*

**INTERPRETED BY**

Eric Lindquist, DMV  
DABVP, Cert. IVUSS

a) S-adenosylmethionine (SAmE): Give 20 mg/kg/day PO on an empty stomach (1-2 hours before feeding). It is available in 90 mg tablets that are not to be broken. SAmE replenishes glutathione and aids in cellular detoxification; it also has anti-arthritis effects. SAmE is an anti-inflammatory and antioxidant. It also promotes hepatocellular regeneration and rectifies RBC membrane abnormalities in dogs with liver disease or oxidative damage.

**IMAGING PERFORMED BY**

Eric Lindquist, DMV  
DABVP, Cert. IVUSS

b) Milk Thistle: Administer as silybin or silymarin extracts (a high-quality supplement is essential). Acts as an antioxidant and free radical scavenger; decreases hepatotoxin binding; improves glutathione concentrations; aids in iron chelating; and promotes cholestasis. Give 5-15 mg/kg/day PO.

**HOSPITAL NAME**

Franklin lakes AH

c) Ursodiol (Actigall): Give 10-15 mg/kg PO once daily, with food, to stimulate bile flow and decrease cholestasis. Tablets (250 mg) or capsules (300 mg) are available; however, ursodiol can also be compounded into a liquid to dose small patients. It has immunomodulatory, anti-fibrotic, and choleretic effects, anti-copper storage benefits, and stabilizes mitochondrial function.

**REFERRING VET**

Dr. Kozak

d) Vitamin E: Must be coupled with good nutrition and other antioxidants to avoid accumulation of tocopheroxyl radicals. To that end, supplementation with SAmE may help ensure that adequate GSH (mitochondrial glutathione) concentrations are achieved. Give 10-15 IU/kg/day PO (100-400 IU) in a water-soluble form twice daily, as well as with Vitamin C 25 mg/kg/day.

**INVOICE**

22458

e) Cobalamin and Thiamine (B12 and B1): Give 250ug SC weekly.

**DATE**

5/11/23



**PATIENT**

Bruno Salerno

**Inflammatory hepatopathy/chronic hepatitis**

*1. Immunosuppressive agents*

**SPECIES**

Canine

a) Prednisone or prednisolone: Administer if inflammatory disease has been diagnosed by biopsy, beginning at 2 mg/kg/day for 2-4 weeks; subsequently reduce to 1 mg/kg/day. Once remission has been achieved, taper to 0.5 mg/kg/day (or to the lowest tolerable dose) over 2-4 weeks. Steroids may be discontinued if a different immunosuppressive medication is effective at controlling inflammation (i.e., azathioprine or cyclosporine) since they are contraindicated with hepatic encephalopathy. Possible negative sequelae of corticosteroids include increased water retention and potentiation of gastrointestinal ulceration. In the face of portal hypertension and ascites, dexamethasone is preferred—it does not exhibit mineralocorticoid activity and thus does not potentiate water retention as compared to prednisone—at 0.2-0.4 mg/kg orally once daily. Taper in a similar manner.

**BREED**

Rotti/Mix

**SEX**

Neutered Male

b) Azathioprine (Imuran): Give 50 mg/m<sup>2</sup>/day or 2 mg/kg/day as a long-term alternative to prednisone. The dose can be decreased to 1 mg/kg and eventually given every other day if there is a positive response. Check CBC and platelet count biweekly for the first 2 months and then monthly thereafter. Taper every 2-4 weeks to the lowest effective dose while monitoring transaminase levels. It can often be dosed on alternate days to prednisone. Possible negative side effects include bone marrow suppression and hepatic necrosis. Cyclosporine has been proposed as an alternative immunosuppressant in the management of chronic hepatitis and may allow one to cease concurrent steroid therapy; however, this has not been thoroughly investigated as of yet.

**AGE**

6

**WEIGHT**

130

*2. Hepatic Support*

**INTERPRETED BY**

See medications listed in the previous section.

Eric Lindquist, DMV  
DABVP, Cert. IVUSS

*3. Anti-fibrotics*

**IMAGING PERFORMED BY**

Eric Lindquist, DMV  
DABVP, Cert. IVUSS

a) Colchicine: Give 0.03 mg/kg/day. Colchicine acts as an anti-inflammatory agent, stabilizes membranes, and stimulates collagenase production, thereby diminishing fibrosis. Colchicine should be used to treat hepatic fibrosis based on biopsy results; however, it can also be considered when ascites is present, and when hepatic fibrosis and cirrhosis are highly suspected based on sonographic appearance and clinical findings. It can result in adverse effects, including vomiting, diarrhea, and inappetence. Discontinue until clinical signs resolve, and reinstitute at a lower dose and up-titrate slowly.

**HOSPITAL NAME**

Franklin lakes AH

*4. Hepatic Encephalopathy*

a) Lactulose: Give 0.5 ml/kg orally 2-3 times daily to soften the stool. It helps manage hepatic encephalopathy by combining with ammonium in the GI tract and thus decreasing circulating ammonia levels. Use in conjunction with low dose metronidazole. Lactulose can also be given as a retention enema in an encephalopathic crisis.

**REFERRING VET**

Dr. Kozak

b) Metronidazole: Give at 7.5 mg/kg PO TID. Neomycin is an alternative and can be administered at 22 mg/kg PO BID-TID.

**INVOICE**

22458

c) L-Carnitine: Give 200-400 mg/day. Normally synthesized by the liver, L-Carnitine enhances ammonia elimination and is indicated in cases of hepatic encephalopathy and lipidosis. Carnitine must be in the L-form.

**DATE**

5/11/23



**PATIENT**

**5. Copper Chelation**

Bruno Salerno

Use chelation when copper toxicity has been documented on biopsy and quantification has been performed to confirm toxic levels.

**SPECIES**

Canine

a) D-penicillamine: Give 10-15 mg/kg PO BID on an empty stomach. This is a copper chelator and should only be used based on a quantitative analysis of copper. Possible side effects include vomiting and inappetence. Do not give in conjunction with zinc.

**BREED**

Rotti/Mix

b) 2,3,2 Tetramine (Syprine, Cuprid): Give 5-7 mg/kg PO BID on an empty stomach (1-2 hours before eating). An alternative to D-penicillamine for those dogs that are intolerant.

**SEX**

Neutered Male

c) Zinc gluconate, acetate, or sulfate (acetate is best tolerated): Give 15-10 mg/kg elemental zinc divided BID for 2-6 months as a loading dose. Administer on an empty stomach (30-60 minutes before eating). Reduce to half the dose during the maintenance phase. A low copper diet is preferred (i.e., therapeutic diets, such as Hill's I/d® or Royal Canin® Hepatic™, are advisable). Zinc binds with intestinal copper to avoid absorption in the gastrointestinal tract and may be used alone in mild cases of copper toxicity. The goal is to reach zinc serum levels of 200-600 ug/dl; levels should initially be measured every 2-3 months. Give this medication on an empty stomach or with tuna fish to avoid vomiting. Zinc is not as effective as D-penicillamine and is only used in mild cases. It is not used in conjunction with D-penicillamine.

**AGE**

6

**6. Portal Hypertension and Ascites**

**WEIGHT**

130

a) Spironolactone: If ascites is present secondary to portal hypertension, spironolactone can be dosed at 1-2 mg/kg PO BID; it is the diuretic of choice. Alternatively, spironolactone can be used in conjunction with furosemide (0.5-1 mg/kg PO BID) or hydrochlorothiazide; one should administer 1 mg/kg PO BID if given in conjunction with another diuretic. Monitor renal function and electrolytes diligently.

**INTERPRETED BY**

Eric Lindquist, DMV  
DABVP, Cert. IVUSS

b) Famotidine: Give 0.5 mg/kg PO BID in cases of portal hypertension that result in gastrointestinal bleeding/melena.

**IMAGING PERFORMED BY**

Eric Lindquist, DMV  
DABVP, Cert. IVUSS

**General Notes on Therapeutic Management:** Given that a primary function of the liver is to metabolize oral medications via the portal system (first past effect), numerous medications may result in higher systemic exposure to parent compounds in the face of hepatic insufficiency or failure. Drugs that are inactivated by the liver, produce hepatic damage, or require hepatic metabolism should be avoided. These include: lincomycin, clindamycin, streptomycin, chloramphenicol, sulfonamides, erythromycin, hetacillin, phenobarbital, diazepam, oxy- or chloro-tetracyclines, azole antifungals, nonsteroidal anti-inflammatory drugs (NSAIDs), theophylline or chloramphenicol, combinations of cimetidine and metronidazole, and combinations of enrofloxacin and theophylline or cisapride. In cases of hepatic lipidosis, glucocorticoids, anabolic steroids, and lipotropic agents containing methionine should be avoided as they result in the production of encephalopathic toxins (metacarpans). Glucocorticoids are indicated for cholangitis, but only after lymphoma and hepatic lipidosis have been ruled out.

**HOSPITAL NAME**

Franklin lakes AH

**REFERRING VET**

Dr. Kozak

**References:**

Bauer E. Hepatic disease, nutritional therapy, and the metabolic environment. *J Am Vet Med Assoc* 1996;209(11):1850-54.

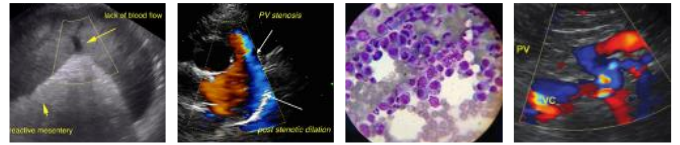
**INVOICE**

22458

Bradley AM and Twedt DC. Cyclosporine therapy for canine chronic hepatitis: a retrospective study. Proceedings from the American College of Veterinary Internal Medicine, Anaheim, CA, June 15-18, 2011.

**DATE**

5/11/23



**PATIENT**

Bruno Salerno

Center SA. Chronic hepatitis, cirrhosis, breed-specific hepatopathies, copper storage hepatopathy, suppurative hepatitis, granulomatous hepatitis, and idiopathic hepatic fibrosis. In: Guilford WG, Center SA, Strombeck DR, Williams DA, and Meyer DJ, eds: *Strombeck's Small Animal Gastroenterology 3rd ed*. Philadelphia, PA: WB Saunders; 1996:705-65.

**SPECIES**

Canine

Center S. Metabolic, antioxidant, nutraceutical, probiotic, and herbal therapies relating to the management of hepatobiliary disorders. *Vet Clin North Am Small Anim Pract* 2004;34(1):67-172.

**BREED**

Rotti/Mix

Center SA. Diagnostic and managerial pearls for selected hepatobiliary disorders. Proceedings from the American College of Veterinary Internal Medicine. New Orleans, LA, May 30-June 2, 2012.

**SEX**

Neutered Male

Davenport D. Antimicrobial therapy for gastrointestinal, pancreatic, and hepatic disorders. *Probl Vet Med* 1990;2(2):374-93.

**AGE**

6

Hackett T, Twedt D, Gustafson D. Milk thistle and its derivative compounds: a review of opportunities for treatment of liver disease. *J Vet Intern Med* 2013;27(1):10-16.

Thompson M, Meyer D, Senior D. Effects of treatment with ursodeoxycholic acid on bile acid profiles in a dog with chronic hepatic disease. *J Vet Intern Med* 1991;5(2):130.

**WEIGHT**

130

**INTERPRETED BY**

Eric Lindquist, DMV  
DABVP, Cert. IVUSS

**IMAGING  
PERFORMED BY**

Eric Lindquist, DMV  
DABVP, Cert. IVUSS

**HOSPITAL NAME**

Franklin lakes AH

**REFERRING VET**

Dr. Kozak

**INVOICE**

22458

**DATE**

5/11/23