

**DATE**

5/11/22

PRESENTING CLINICAL SIGNS

Elevated Ca+.

Current Medications: None listed.

Date of Previous IntraPet Ultrasound: No previous.

PATIENT

Sky Burnell

Sedation: Not required to complete full diagnostic ultrasound.

Stat Report: Not requested.

Imaging Performed By: Rachel Brillhart, RDMS.

SPECIES

Canine

BREED

Dachshund

SEX

Spayed Female

AGE

9/3/10

WEIGHT

11.8 lbs

INTERPRETED BYEric Lindquist, DMV
DABVP, Cert. IVUSS**HOSPITAL NAME**

Mount Airy AH

REFERRING VET

Dr. Riley

INVOICE

30306

ULTRASONOGRAPHIC EXAMINATION OF THE THYROID

The right thyroid lobe was uniform and measured 1.5 x 0.25 cm with a hypoechoic 0.44 x 0.22 cm nodule at the mid caudal body. This is consistent with parathyroid adenoma. The left thyroid lobe revealed two separate nodules measuring 0.29 cm and 0.26 cm. The left thyroid lobe measured 1.52 x 0.4 cm. Salivary glands and regional tissues were unremarkable. The trachea and esophagus were unremarkable. The right retropharyngeal lymph nodes were slightly heterogenous. Slightly enlarged left parathyroid nodules, larger caudal right parathyroid nodule.

ULTRASONOGRAPHIC FINDINGS

Right hypoechoic thyroid nodule.

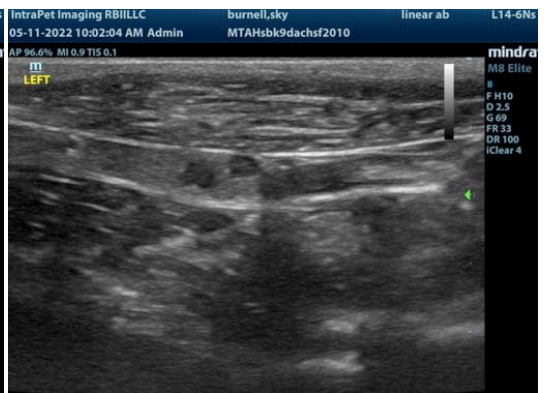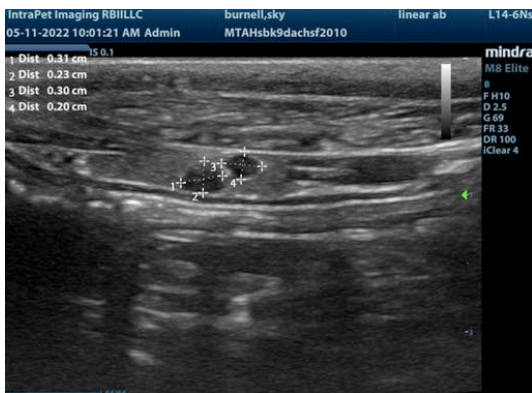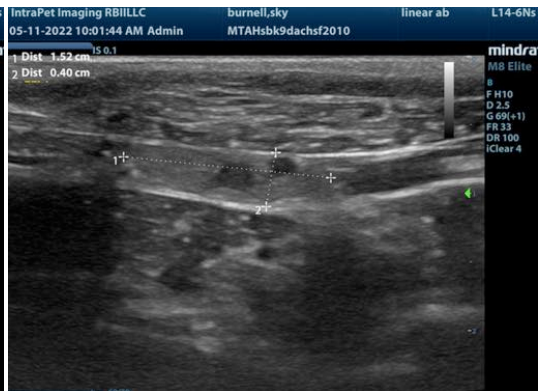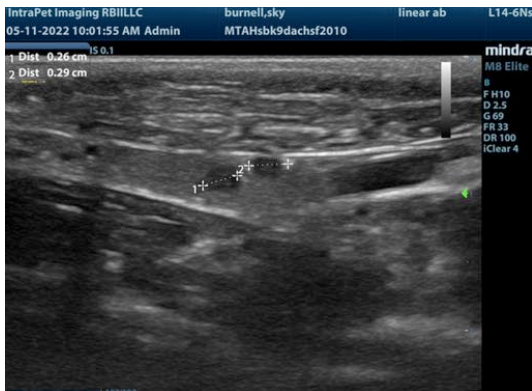
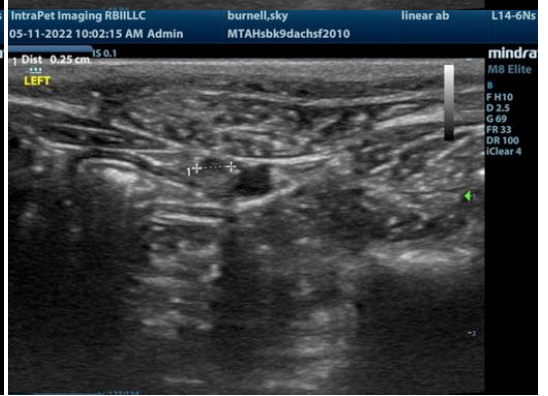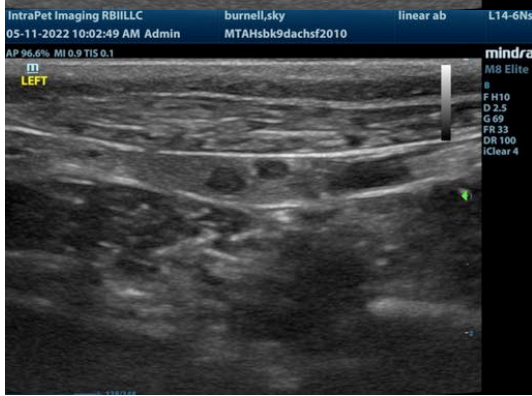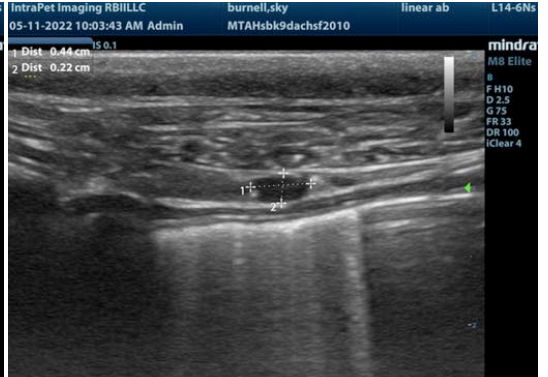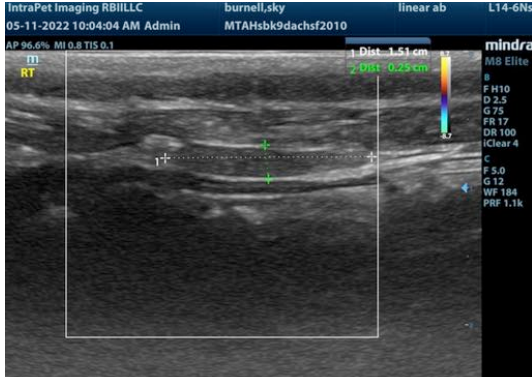
Two separate left thyroid nodules.

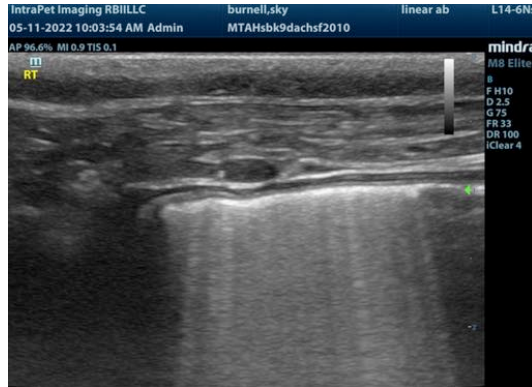INTERPRETATION OF THE FINDINGS & FURTHER RECOMMENDATIONS

I suspect the right parathyroid nodule is a functional adenoma causing hypercalcemia as capsular expansion is present. The left parathyroid nodules are likely hyperplastic; however, this is only a tendency and a subjective finding. FNA of all three lesions could be considered for further definition. Otherwise, surgical removal of the right mid to caudal parathyroid nodule could be considered and then reassess the left nodule at that time or inspection and removal of all three could also be considered assuming hypercalcemia panel supports primary hyperparathyroidism. If secondary hyperparathyroidism is supported by hypercalcemia panel then all three of these parathyroid nodules could technically be hyperplastic.

For an additional charge an internal medicine consult can be utilized through [Sonopath.com](http://sonopath.com). You can select the internal medicine drop down at <http://spa.sonopath.com/>.

One of the world's top internists & SonoPath associate Dr. Remo Lobetti BVSc, MMedVet, PhD, DECVIM can evaluate your case through SonoPath. <https://sonopath.com/resources/sonopath-services/internal-medicine-teleconsultation-services>






The information and recommendations provided are based on the images presented by the referring veterinarian. No evaluation can be communicated regarding pathology that was not visible in the image/video clips provided.

Thank you for this referral. If the clinical or image interpretation does not parallel your findings or if I can be of any further assistance please contact me.

Eric Lindquist, DMV, DABVP, Cert. IVUSS, CEO of SonoPath.com
Eric.Lindquist@SonoPath.com



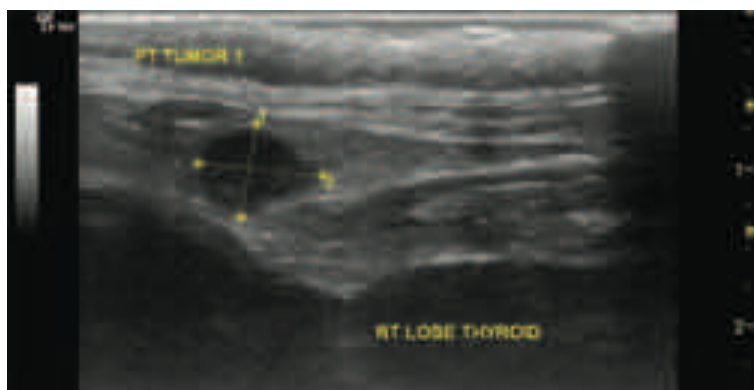
The following is an applicable excerpt from the *Curbside Guide to Diagnosis & Treatment of Sonographic Disease* offered by [SonoPath.com](http://sonopath.com) Lindquist, Frank, Lobetti, and Modler.

An essential quick guide for every general practitioner and sonographer.

<https://sonopath.com/products/curbside-guide-editing-due-release-12012015>

CANINE HYPERCALCEMIA

<http://www.sonopath.com/CanineHypercalcemia>



Long axis of the right thyroid lobe in a dog with a parathyroid adenoma. The right internal parathyroid gland (between calipers) shows severe uniform enlargement of more than 7mm.

Description: Hypercalcemia is defined as either a persistently elevated total calcium serum (> 12 mg/dl) or

ionized calcium (> 1.45 mmol/l) concentration. Clinical signs are often absent with mild hypercalcemia (< 13 mg/dl). In fact, hypercalcemia is often only discovered when serum biochemistry is done for unrelated reasons. Clinical signs are usually mild when the serum calcium concentration is less than 14 mg/dl; however, signs become more readily apparent when the concentration exceeds 15 mg/dl. Life-threatening cardiac arrhythmias can develop when the serum calcium exceeds 18 mg/dl.

Common etiologies of hypercalcemia include humoral hypercalcemia of malignancy (HHM), hypoadrenocorticism, chronic kidney disease (CKD), hypervitaminosis D, and primary hyperparathyroidism. Less common etiologies include bone neoplasia, osteomyelitis, hypertrophic osteodystrophy, granulomatous disease, calcium supplementation, and oral phosphate binders.

Clinical Signs: Common clinical signs include polyuria, polydipsia, lethargy, inappetence, and weakness. With chronic hypercalcemia, calcium oxalate and calcium phosphate uroliths can form, resulting in clinical signs suggestive of lower urinary tract disease. Systemic signs of illness are suggestive of HHM.

Diagnostics: One important etiology of hypercalcemia is laboratory error; therefore, hypercalcemia should always be confirmed before embarking on any further diagnostic evaluation. Results of a CBC, serum biochemistry panel, and urinalysis, in conjunction with a patient history and findings from a physical examination, can often provide enough information to arrive at a diagnosis. The appendicular skeleton, peripheral lymph nodes, abdominal cavity, and rectum should all be carefully palpated for masses, lymphadenopathy, hepatomegaly, splenomegaly, and/or pain in the long bones. The following diagnostic tests are helpful for identifying an underlying malignancy: thoracic and abdominal radiographs; abdominal ultrasound; cytological evaluation of aspirates of the liver, spleen, lymph nodes, and bone marrow; determination of serum ionized calcium, parathyroid hormone (PTH), and parathyroid hormone-related protein concentration (PTHrP); and ultrasound of the neck. Ascertaining the concentrations of serum ionized calcium, PTH, and PTHrP helps differentiate primary hyperparathyroidism from HHM. The finding of one or more enlarged parathyroid glands upon conducting an ultrasound of the neck supports a diagnosis of primary hyperparathyroidism.

Hypoadrenocorticism-induced hypercalcemia usually occurs in conjunction with hyponatremia, hyperkalemia, and prerenal azotemia. With HHM and primary hyperparathyroidism, serum phosphorus concentration is often in the low to low-normal reference range. If the serum phosphorus concentration is high but kidney function is normal, hypervitaminosis D or osteolysis should be suspected.

It can be difficult to determine whether kidney failure is primary or secondary to hypercalcemia when hyperphosphatemia and hypercalcemia coexist with azotemia. Serum ionized calcium concentrations are typically normal or decreased in cases of renal failure and increased in cases of hypercalcemia caused by other disorders.

Sternal and hilar lymphadenopathy is common with lymphoma-induced hypercalcemia and can be readily identified on thoracic radiographs. In cases of multiple myeloma, discrete lytic lesions in the vertebrae or long bones, hyperproteinemia, proteinuria, and plasma cell infiltration in the bone marrow may be present. Cytological evaluation of the peripheral lymph nodes, bone marrow, and spleen can be helpful in identifying lymphoma.

Increased serum ionized calcium concentrations, detectable serum PTHrP concentrations, and non-detectable serum PTH concentrations are all diagnostic for HHM. Lymphoma is the most common etiology of HHM, but other tumors, such as apocrine gland adenocarcinoma and various carcinomas (e.g. mammary gland, squamous cell, bronchogenic), can all give rise to hypercalcemia. Increased serum ionized calcium, normal to increased serum PTH, and non-detectable PTHrP concentrations are diagnostic of primary hyperparathyroidism.

Differentials for Hypercalcemia: "HARD IONS"

Hyperparathyroid
Addison's
Renal
D-toxicity
Idiopathic
Osteolytic
Neoplastic
Spurious

PTH tumor: Elevated total and ionized Ca, low PTHrP, and normal/high PTH. Keeshonds, German Shepherds, and Golden Retrievers are all predisposed.

Addison's disease: Elevated total and normal ionized Ca, elevated BUN, hypoalbuminemia and hyperkalemia.

Renal failure: Elevated to normal total Ca, low ionized Ca, low PTHrP, elevated PTH, azotemia, and low urine specific gravity.

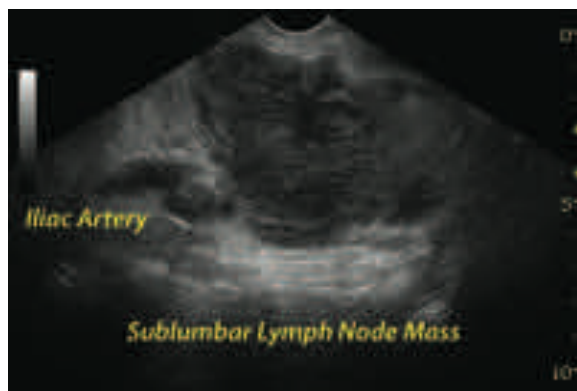
Vitamin D toxicity: Elevated total and ionized Ca, low PTHrP, and normal/low PTH.

Hypercalcemia of malignancy (HHM): Elevated total and ionized Ca, high PTHrP, and low PTH.

Granulomatous disease: Elevated total and ionized Ca, low PTHrP, and low PTH.

Renal failure: Elevated to normal total Ca, low ionized Ca, low PTHrP, elevated PTH, azotemia, and low urine specific gravity.

Treatment: Therapies for hypercalcemia are aimed at correcting the underlying etiology; however, because prolonged hypercalcemia can result in kidney damage, the use of fluid therapy, furosemide, and possibly prednisone is indicated in all cases to reduce serum calcium levels. Suggested dosages include saline (0.9% 120-180 ml/kg day IV), furosemide (1-4 mg/kg PO TID), and prednisone (0.25 mg/kg PO Q24hr).



Long axis of the left hypogastric lymph node in a hypercalcemic dog with lymphoma and hypercalcemia of malignancy. The lymph node is severely enlarged and rounded with a short-to-long-axis ratio > 0.5 indicating malignant infiltration. The regular echoarchitecture is lost, the hilus is not recognized, lymph node parenchyma is hypoechoic and heterogenous. Also note the mass effect on the external iliac artery. In light of hypercalcemia, lymphadenopathy in this region could also be owing to anal gland adenocarcinoma which can also be imaged sonographically.

References:

Chew DJ, Schenck PA, Jaeger JQ. Clinical disorders of hypercalcemia and hypocalcemia in dogs and cats. Proceedings from the American College of Veterinary Internal Medicine, Charlotte, NC, June 4-7, 2003.

Feldman EC. Disorders of the parathyroid glands. In: Ettinger SJ, Feldman EC, ed. *Textbook of Veterinary Internal Medicine*, 7th ed. St. Louis, MO: Saunders Elsevier; 2010:1722-50.

Peterson ME. Hypercalcemia in dogs & cats: differential diagnosis & treatment. Proceedings from the Western Veterinary Conference, Las Vegas, NV, February 19-23, 2012.