



PATIENT

PRESENTING CLINICAL SIGNS

Petunia Silver

chronic diarrhea, excessive hunger sister is Buttercup

SPECIES

Feline

ULTRASONOGRAPHIC EXAMINATION OF THE HEART & ABDOMEN

BREED

Bengal

SEX

Female

AGE

6 Months

WEIGHT

6 Pounds

FELINE CARDIAC PARAMETERS	BODY WEIGHT (kg)	HR (BPM)	IVSd (cm)	LVIDd (cm)	LVWd (cm)	FS (%)	EF (%)
NORMAL PARAMETER	-----	150-240	0.3-0.6	1.0-2.1	0.25-0.6	35-67	80-100
PATIENT		NM	--	--	--	--	--
FELINE CARDIAC PARAMETERS	LA/AO (Boon)	LA/AO HEART BASE (Sisson)	LA 2D 4-chamber long axis AS to FW (Sisson) (cm)	LVOT VEL. (m/s)	RVOT VEL. (m/s)	IVRT (m/)	
NORMAL PARAMETER	<1.5	0.88-1.79	0.7-1.7	<1.6	<1.3	40-60	
PATIENT	1.1	1.17	1.2	1.0	0.40	NM	
Adapted from June Boon, Veterinary Echocardiography, 1998							
Sisson D et al. JVIM 1991; 5: 232, Jacobs et al. Am J Vet Res 1985; 46:1705							

Cardiac Presentation

The echocardiogram in this patient demonstrated normal **left atrial** size based on 3 separate LA measurements. The cranial and caudal **mitral** valve leaflets presented normal linear structure and kinetics. The **left ventricle** presented normal thicknesses with linear contour and was not dilated nor restricted. The **myocardium** presented normal echogenicity without subjective evidence of significant fibrotic or ischemic disease. **Contractility** of the ventricular walls was adequate and in normal range for this patient evidenced by the fractional shortening measurement and subjective evaluation of the different regions and angles of the myocardium. The **left ventricular outflow** tract demonstrated normal laminar flow and subjective structural integrity. The **right atrium** and auricle revealed normal size, structure and content. No evidence of masses was noted or chamber overload. **Tricuspid** valvular assessment demonstrated adequate linear morphology and kinetics. The **right ventricle** was of normal size (1/3 diameter of LV), chordae structure, myocardial echogenicity and thickness. **Pulmonic** tract assessment revealed normal valve structure, laminar flow, and diameter (approx. 1:1 pa/ao ratio). No visible **pericardial** or free pleura fluid was noted or extra cardiac pathology in the visible planes. The cranial **mediastinum and pericardial regions** were free of masses in the visible window. EPSS = 0.14.

Urinary System

The **urinary bladder**, trigone, and pelvic urethra presented normal thicknesses and normal tone. The ureters were not visible which is normal. No uroliths or sediment were visualized and anechoic urine was present. No evidence of inflammatory or neoplastic changes were noted. Ureteral papillae were normal.

The **kidneys** revealed normal size and structure, corticomedullary definition and ratio for this age. The cortices presented largely uniform texture with normal echogenic relationship to liver and spleen.

Medullary structure differed distinctly from the cortex. The capsules were acceptably uniform without

INTERPRETED BY

Eric Lindquist, DMV

DABVP, Cert. IVUSS

IMAGING PERFORMED BY

Jenn

HOSPITAL NAME

Rockaway AH

REFERRING VET

Dr. Kahn

INVOICE

37605

DATE

5/11/22



PATIENT

significant irregularities. The right kidney measured 3.6 cm with trace pyelectasia noted. The left kidney measured 3.9 cm.

Petunia Silver

Adrenal Glands

SPECIES

The regions of the **adrenal glands** were unremarkable.

Feline

Spleen

BREED

The **spleen** presented a smooth homogeneous parenchyma hyperechoic to liver and renal cortical parenchyma. The capsule was smooth without noticeable expansion or deviation from within the spleen or adjacent pathology. The splenic vasculature demonstrated normal volume without signs of congestion or thrombosis. No sonographic evidence of acute or chronic inflammatory, neoplastic, or infarctual changes were noted.

Bengal

SEX

Liver

Female

The **liver** images submitted revealed subjectively normal liver size, contour, and structure. Parenchymal echogenicity was naturally coarse and hypoechoic to the spleen. Vascular and biliary tracts were of normal volume with no evidence of congestion. Duplicated gallbladder noted, idiopathic finding.

AGE

6 Months

Gastrointestinal

WEIGHT

The **stomach** was mildly thickened in this patient with a minor amount of anechoic luminal fluid. Minor intestinal thickening present without evidence of obstruction.

6 Pounds

Pancreas

INTERPRETED BY

The base and limbs of the **pancreas** were observed to be largely isoechoic to surrounding omental fat. Pancreatic duct and capsular contour were acceptably normal and parenchyma respected normal curvilinear patterns. No overt evidence of active inflammatory or neoplastic disease was noted.

Eric Lindquist, DMV

ULTRASONOGRAPHIC FINDINGS

DABVP, Cert. IVUSS

IMAGING PERFORMED BY

- Normal echocardiogram
- Mild gastritis pattern
- Mild idiopathic renal pyelectasia
- Duplicated gallbladder, incidental finding

Jenn

HOSPITAL NAME

INTERPRETATION OF THE FINDINGS & FURTHER RECOMMENDATIONS

Rockaway AH

No evidence of cardiac pathology. Given the breed and the clinical signs, periodic monitoring of this patient and the litter would be recommended to ensure an emerging FIP is not an issue. Even though structurally the abdomen is unremarkable at this time, the vague, non-explainable clinical signs are a concern if non-responsive to therapy. Antiparasitic protocol warranted as well as diet change.

REFERRING VET

Dr. Kahn

INVOICE

37605

DATE

5/11/22



PATIENT

Petunia Silver

SPECIES

Feline

BREED

Bengal

SEX

Female

AGE

6 Months

WEIGHT

6 Pounds

INTERPRETED BY

Eric Lindquist, DMV

DABVP, Cert. IVUSS

IMAGING PERFORMED BY

Jenn

HOSPITAL NAME

Rockaway AH

REFERRING VET

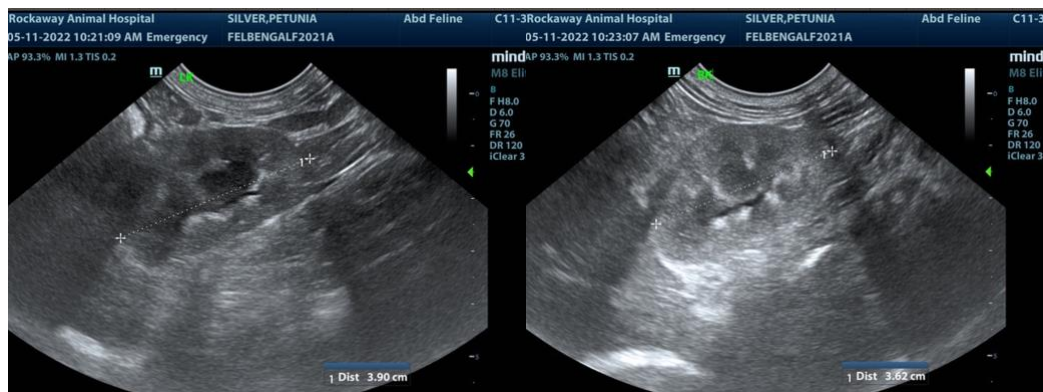
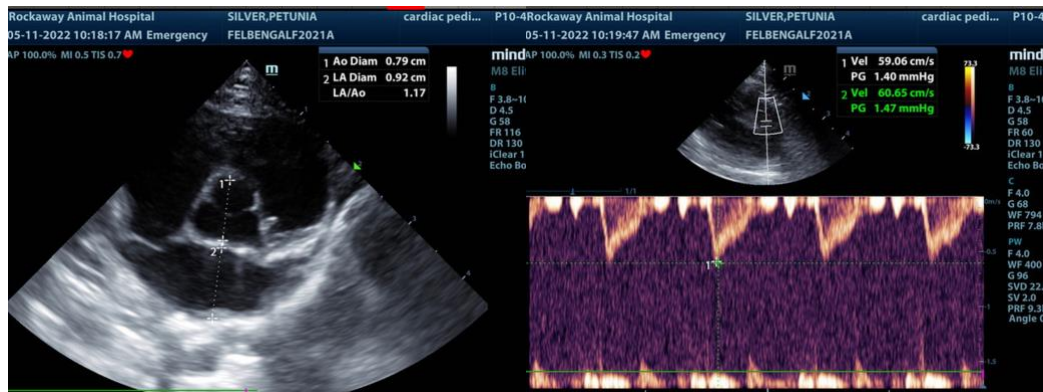
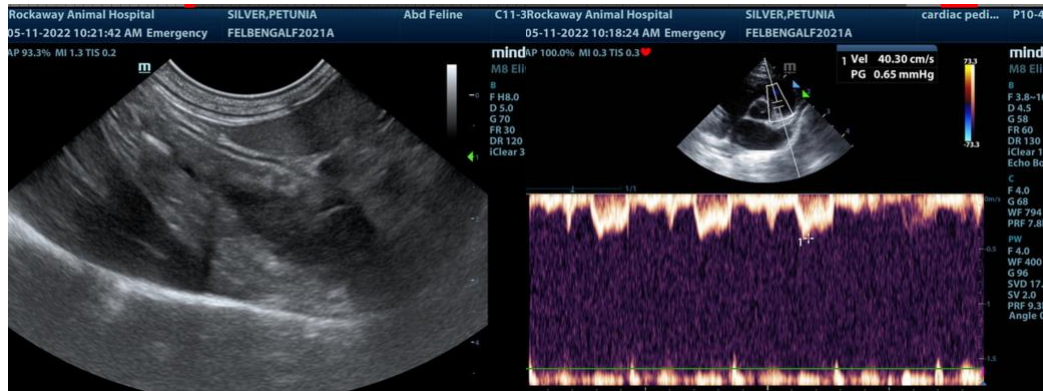
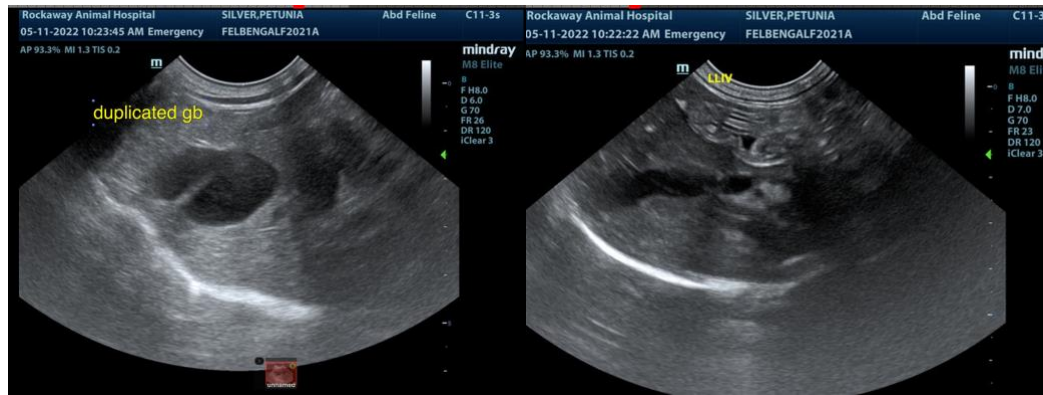
Dr. Kahn

INVOICE

37605

DATE

5/11/22





PATIENT

Petunia Silver

SPECIES

Feline

BREED

Bengal

SEX

Female

AGE

6 Months

WEIGHT

6 Pounds

INTERPRETED BY

Eric Lindquist, DMV

DABVP, Cert. IVUSS

IMAGING PERFORMED BY

Jenn

HOSPITAL NAME

Rockaway AH

REFERRING VET

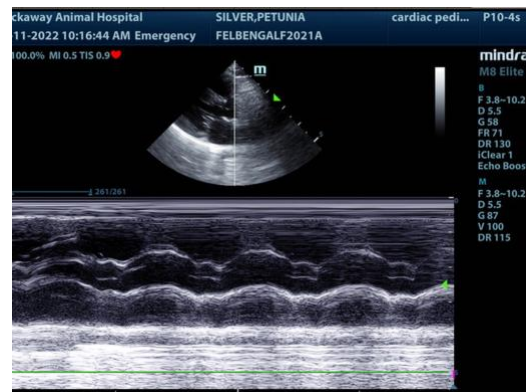
Dr. Kahn

INVOICE

37605

DATE

5/11/22



The information and recommendations provided are based on the images presented by the referring veterinarian/sonographer. No evaluation can be communicated regarding pathology that was not visible in the image/video clips provided.

Thank you for this referral. If the clinical or image interpretation does not parallel your findings or if I can be of any further assistance please contact me.

Eric Lindquist, DMV, DABVP, Cert. IVUSS, CEO of SonoPath.com

info@SonoPath.com