



**PATIENT**

Howie Northem

**SPECIES**

Feline

**BREED**

Russian Blue

**SEX**

Neutered male

**AGE**

11 years

**WEIGHT**

10.8 lbs

**INTERPRETED BY**

Eric Lindquist, DMV  
DABVP, Cert. IVUSS

**IMAGING PERFORMED BY**

Jessica Miller, RDMS

**HOSPITAL NAME**

Budd Lake AH

**REFERRING VET**

Dr. Horn

**INVOICE**

30279

**DATE**

5/11/22

**PRESENTING CLINICAL SIGNS**

History: Grade II/VI left parasternal murmur. Needs dental - safe for anesthesia? No current meds.  
Abnormal PE/Chem/CBC/UA Results: All normal 2/3/22

**ULTRASONOGRAPHIC EXAMINATION OF THE ABDOMEN**

The echocardiogram in this patient demonstrated normal **left atrial** size based on 3 separate LA measurements. Minor **mitral** insufficiency was noted and centralized. The **left ventricle** presented normal thicknesses with linear contour and was not dilated nor restricted. The **myocardium** presented normal echogenicity without subjective evidence of significant fibrotic or ischemic disease. **Contractility** of the ventricular walls was adequate and in normal range for this patient evidenced by the fractional shortening measurement and subjective evaluation of the different regions and angles of the myocardium. The **left ventricular outflow** tract demonstrated normal laminar flow and subjective structural integrity. The **right atrium** and auricle revealed normal size, structure and content. No evidence of masses was noted or chamber overload. **Tricuspid** valvular assessment demonstrated adequate linear morphology and kinetics. The **right ventricle** was of normal size (1/3 diameter of LV), chordae structure, myocardial echogenicity and thickness. **Pulmonic** tract assessment revealed normal valve structure, laminar flow, and diameter (approx. 1:1 pa/ao ratio). No visible **pericardial** or free pleura fluid was noted or extra cardiac pathology in the visible planes. The cranial **mediastinum** and **pericardial regions** were free of masses in the visible window.

FELINE CARDIAC PARAMETERS	BODY WEIGHT (kg)	HR (BPM)	IVSd (cm)	LVIDd (cm)	LVWd (cm)	FS (%)	EF (%)
NORMAL PARAMETER	-----	150-240	0.3-0.6	1.0-2.1	0.25-0.6	35-67	80-100
PATIENT		81	0.38	1.47		57	89
FELINE CARDIAC PARAMETERS	LA/AO (Boon)	LA/AO HEART BASE (Sisson)	LA 2D 4-chamber long axis AS to FW (Sisson) (cm)	LVOT VEL. (m/s)	RVOT VEL. (m/s)	IVRT (m/)	
NORMAL PARAMETER	<1.5	0.88-1.79	0.7-1.7	<1.6	<1.3	40-60	
PATIENT	1.43	1.42		1.3	0.71	NM	
Adapted from June Boon, Veterinary Echocardiography, 1998 Sisson D et al. JVIM 1991; 5: 232, Jacobs et al. Am J Vet Res 1985; 46:1705							

**ULTRASONOGRAPHIC FINDINGS**

Normal echocardiogram with mitral insufficiency, not clinically significant.



**PATIENT**

Howie Northem

**SPECIES**

Feline

**BREED**

Russian Blue

**SEX**

Neutered male

**AGE**

11 years

**WEIGHT**

10.8 lbs

**INTERPRETED BY**

Eric Lindquist, DMV  
DABVP, Cert. IVUSS

**IMAGING PERFORMED BY**

Jessica Miller, RDMS

**HOSPITAL NAME**

Budd Lake AH

**REFERRING VET**

Dr. Horn

**INVOICE**

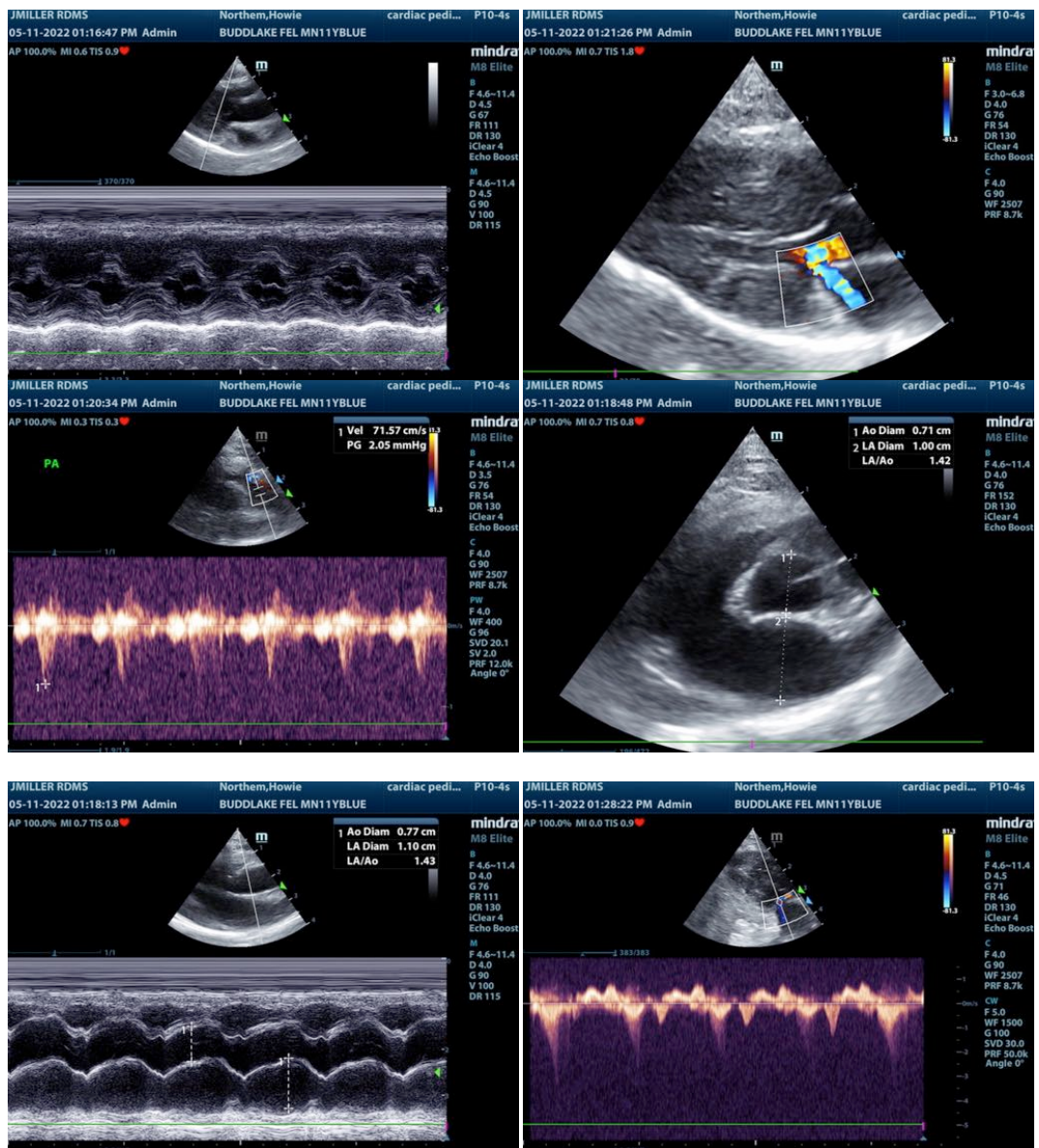
30279

**DATE**

5/11/22

**INTERPRETATION OF THE FINDINGS & FURTHER RECOMMENDATIONS**

There is no contraindication to anesthetic procedure as long as blood pressure measurements and thyroid assessments are normal. A recheck echocardiogram is recommended in a year or earlier if any clinical signs initiate. However, this defect is well compensated at this time. Torbutrol premed, Propofol induction, and Isoflurane maintenance or equivalent is recommended.





**PATIENT**

Howie Northem

**SPECIES**

Feline

**BREED**

Russian Blue

**SEX**

Neutered male

**AGE**

11 years

**WEIGHT**

10.8 lbs

**INTERPRETED BY**

Eric Lindquist, DMV  
DABVP, Cert. IVUSS

**IMAGING PERFORMED BY**

Jessica Miller, RDMS

**HOSPITAL NAME**

Budd Lake AH

**REFERRING VET**

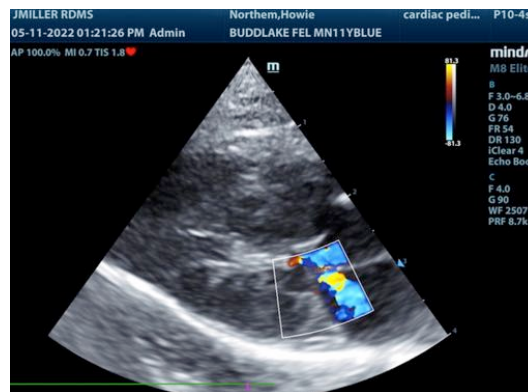
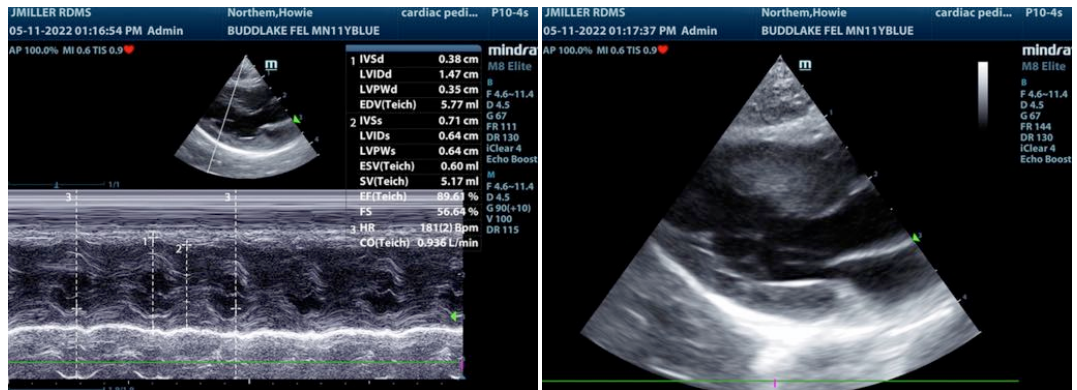
Dr. Horn

**INVOICE**

30279

**DATE**

5/11/22



The information and recommendations provided are based on the images presented by the referring veterinarian/sonographer. No evaluation can be communicated regarding pathology that was not visible in the image/video clips provided.

Thank you for this referral. If the clinical or image interpretation does not parallel your findings or if I can be of any further assistance please contact me.

**Eric Lindquist**, DMV, DABVP, Cert. IVUSS, CEO of SonoPath.com  
info@SonoPath.com