



## PATIENT

Hobbes Parker

## SPECIES

Feline

## BREED

DSH

## SEX

Neutered Male

## AGE

10.5 Years

## WEIGHT

15.34 Pounds

## PRESENTING CLINICAL SIGNS

History: Elevated proBNP on routine preventative bloodwork Fluoxetine 10mg 1/2T SID, Gabapentin 100mg 1 capsule BID

Abnormal PE/Chem/CBC/UA Results: SDMA 18, BUN 49, Cardiopet BNP 309 UA SG: 1.022

## ULTRASONOGRAPHIC EXAMINATION OF THE HEART

FELINE CARDIAC PARAMETERS	BODY WEIGHT (kg)	HR (BPM)	IVSd (cm)	LVIDd (cm)	LVWd (cm)	FS (%)	EF (%)
NORMAL PARAMETER	-----	150-240	0.3-0.6	1.0-2.1	0.25-0.6	35-67	80-100
PATIENT	--	217	0.49	1.59	0.45	57	90
FELINE CARDIAC PARAMETERS	LA/AO (Boon)	LA/AO HEART BASE (Sisson)	LA 2D 4-chamber long axis AS to FW (Sisson) (cm)	LVOT VEL. (m/s)	RVOT VEL. (m/s)	IVRT (m/)	
NORMAL PARAMETER	<1.5	0.88-1.79	0.7-1.7	<1.6	<1.3	40-60	
PATIENT	1.3	1.22	--	1.30	.99	NM	
Adapted from June Boon, Veterinary Echocardiography, 1998 Sisson D et al. JVIM 1991; 5: 232, Jacobs et al. Am J Vet Res 1985; 46:1705							

## INTERPRETED BY

Eric Lindquist, DMV  
DABVP, Cert. IVUSS

## IMAGING PERFORMED BY

Jessica Miller

## HOSPITAL NAME

Long Valley AH

## REFERRING VET

Dr. Earl

## INVOICE

22442

## DATE

5/10/23

## Cardiac Presentation

The echocardiogram in this patient demonstrated normal **left atrial** size based on 3 separate LA measurements. The cranial and caudal **mitral** valve leaflets presented normal linear structure and kinetics. The **left ventricle** presented normal thicknesses with linear contour and was not dilated nor restricted. The **myocardium** presented normal echogenicity without subjective evidence of significant fibrotic or ischemic disease. **Contractility** of the ventricular walls was adequate and in normal range for this patient evidenced by the fractional shortening measurement and subjective evaluation of the different regions and angles of the myocardium. The **left ventricular outflow** tract demonstrated normal laminar flow and subjective structural integrity. The **right atrium** and auricle revealed normal size, structure and content. No evidence of masses was noted or chamber overload. **Tricuspid** valvular assessment demonstrated adequate linear morphology and kinetics. The **right ventricle** was of normal size (1/3 diameter of LV), chordae structure, myocardial echogenicity and thickness. **Pulmonic** tract assessment revealed normal valve structure, laminar flow, and diameter (approx.1:1 pa/ao ratio). No visible **pericardial** or free pleura fluid was noted or extra cardiac pathology in the visible planes. The cranial **mediastinum and pericardial regions** were free of masses in the visible window.

## ULTRASONOGRAPHIC FINDINGS

- Normal echocardiogram

## INTERPRETATION OF THE FINDINGS & FURTHER RECOMMENDATIONS



**PATIENT**

Hobbes Parker

No evidence of structural or functional pathology. Other causes of BNP elevations should be considered, such as hypertension or systemic disease yet structurally and functionally, the heart is normal.

**SPECIES**

Feline

**BREED**

DSH

**SEX**

Neutered Male

**AGE**

10.5 Years

**WEIGHT**

15.34 Pounds

**INTERPRETED BY**

Eric Lindquist, DMV  
DABVP, Cert. IVUSS

**IMAGING PERFORMED BY**

Jessica Miller

**HOSPITAL NAME**

Long Valley AH

**REFERRING VET**

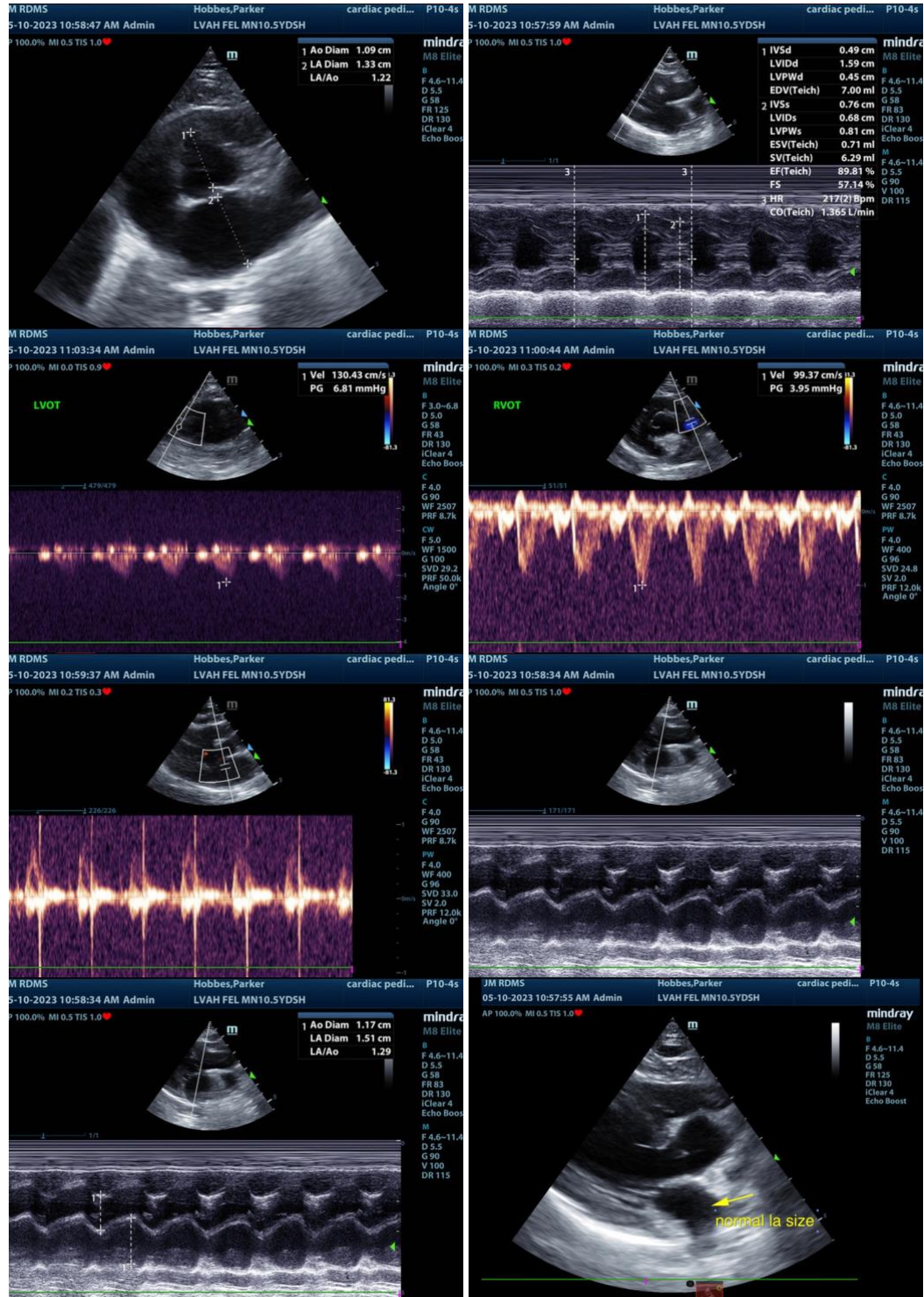
Dr. Earl

**INVOICE**

22442

**DATE**

5/10/23





**PATIENT**

Hobbes Parker

**The information and recommendations provided are based on the images presented by the referring veterinarian. No evaluation can be communicated regarding pathology that was not visible in the image/video clips provided.**

**SPECIES**

Feline

Thank you for this referral. If the clinical or image interpretation does not parallel your findings or if I can be of any further assistance please contact me.

**BREED**

DSH

**Eric Lindquist**, DMV, DABVP, Cert. IVUSS, CEO of SonoPath.com  
info@SonoPath.com

**SEX**

Neutered Male

**AGE**

10.5 Years

**WEIGHT**

15.34 Pounds

**INTERPRETED BY**

Eric Lindquist, DMV  
DABVP, Cert. IVUSS

**IMAGING  
PERFORMED BY**

Jessica Miller

**HOSPITAL NAME**

Long Valley AH

**REFERRING VET**

Dr. Earl

**INVOICE**

22442

**DATE**

5/10/23