



PATIENT

Gus Mandelbaum

PRESENTING CLINICAL SIGNS

Post prandial V+.

SPECIES

Feline

ULTRASONOGRAPHIC EXAMINATION OF THE ABDOMEN

Urinary System

BREED

DSH

The **urinary bladder**, trigone, and pelvic urethra presented normal thicknesses and normal tone. The ureters were not visible which is normal. No uroliths or sediment were visualized and anechoic urine was present. No evidence of inflammatory or neoplastic changes were noted. Ureteral papillae were normal. The pelvic urethra was imaged 2.0 cm beyond the cystourethral junction.

SEX

Neutered Male

The **kidneys** revealed normal size and structure, corticomedullary definition and ratio for this age. The cortices presented largely uniform texture with normal echogenic relationship to liver and spleen. Medullary structure differed distinctly from the cortex and no evidence of pelvic dilation was present. The capsules were acceptably uniform without significant irregularities. The left kidney measured 3.55 cm. The right kidney measured 3.66 cm.

AGE

2 Years

Adrenal Glands

WEIGHT

10.6 Pounds

Both **adrenal glands** were visualized and recognized as having normal shape, size, position and echogenicity for this breed. The phrenic vasculature, glandular echogenicity and detail were unremarkable. Capsule, cortex, and medullary definition were normal for this age patient. The right adrenal gland measured 0.42 cm. The left adrenal gland measured 0.31 cm.

INTERPRETED BY

Eric Lindquist, DMV

Spleen

DABVP, Cert. IVUSS

The **spleen** presented a smooth homogeneous parenchyma hyperechoic to liver and renal cortical parenchyma. The capsule was smooth without noticeable expansion or deviation from within the spleen or adjacent pathology. The splenic vasculature demonstrated normal volume without signs of congestion or thrombosis. No sonographic evidence of acute or chronic inflammatory, neoplastic, or infarctual changes were noted.

IMAGING PERFORMED BY

Shari Reffi, CVT

Liver

HOSPITAL NAME

Rockaway AH

The **liver** images submitted revealed subjectively normal liver size, contour, and structure. Parenchymal echogenicity was naturally coarse and hypoechoic to the spleen. Vascular and biliary tracts were of normal volume with no evidence of congestion. The gallbladder presented acceptably thin walls with primarily anechoic content. The cystic and common bile ducts were normal. No pathological hepatic lymphadenopathy was evident. No overt structural evidence of inflammatory, infiltrative or regenerative pathology was evident.

REFERRING VET

Dr. Maniar

INVOICE

47273

Gastrointestinal

DATE

5/10/23

The **stomach** was dilated with anechoic fluid. The upper duodenum revealed a 2.0 cm shadowing foreign body followed by empty small intestine. The foreign body was hard and curved, such as an almond, pistachio nut, or similar, and was obstructive.

Pancreas

The **pancreas** was hypoechoic with undulating contour. Dilated duct noted. Consistent with pancreatitis. Reactive mesentery noted.

ULTRASONOGRAPHIC FINDINGS

- Duodenal hard shadowing foreign body followed by empty small intestine



PATIENT

Gus Mandelbaum

SPECIES

Feline

BREED

DSH

SEX

Neutered Male

AGE

2 Years

WEIGHT

10.6 Pounds

INTERPRETED BY

Eric Lindquist, DMV

DABVP, Cert. IVUSS

IMAGING PERFORMED BY

Shari Reffi, CVT

HOSPITAL NAME

Rockaway AH

REFERRING VET

Dr. Maniar

INVOICE

47273

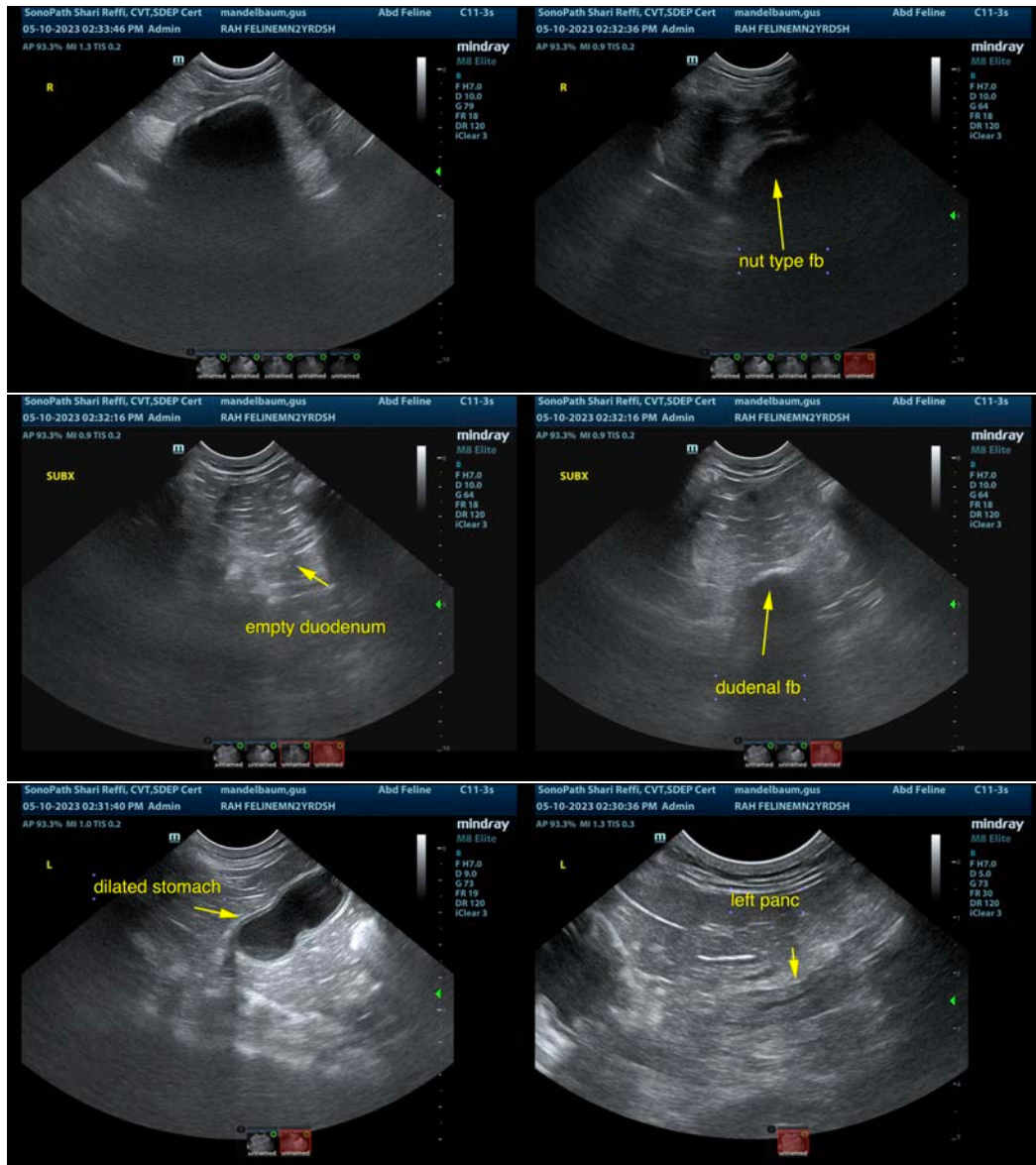
DATE

5/10/23

- Concurrent pancreatitis

INTERPRETATION OF THE FINDINGS & FURTHER RECOMMENDATIONS

Surgical intervention with duodenotomy +/- J-tube placement warranted in this patient, given the concurrent pancreatitis. This is a surgical urgency.





PATIENT

Gus Mandelbaum

SPECIES

Feline

BREED

DSH

SEX

Neutered Male

AGE

2 Years

WEIGHT

10.6 Pounds

INTERPRETED BY

Eric Lindquist, DMV

DABVP, Cert. IVUSS

IMAGING PERFORMED BY

Shari Reffi, CVT

HOSPITAL NAME

Rockaway AH

REFERRING VET

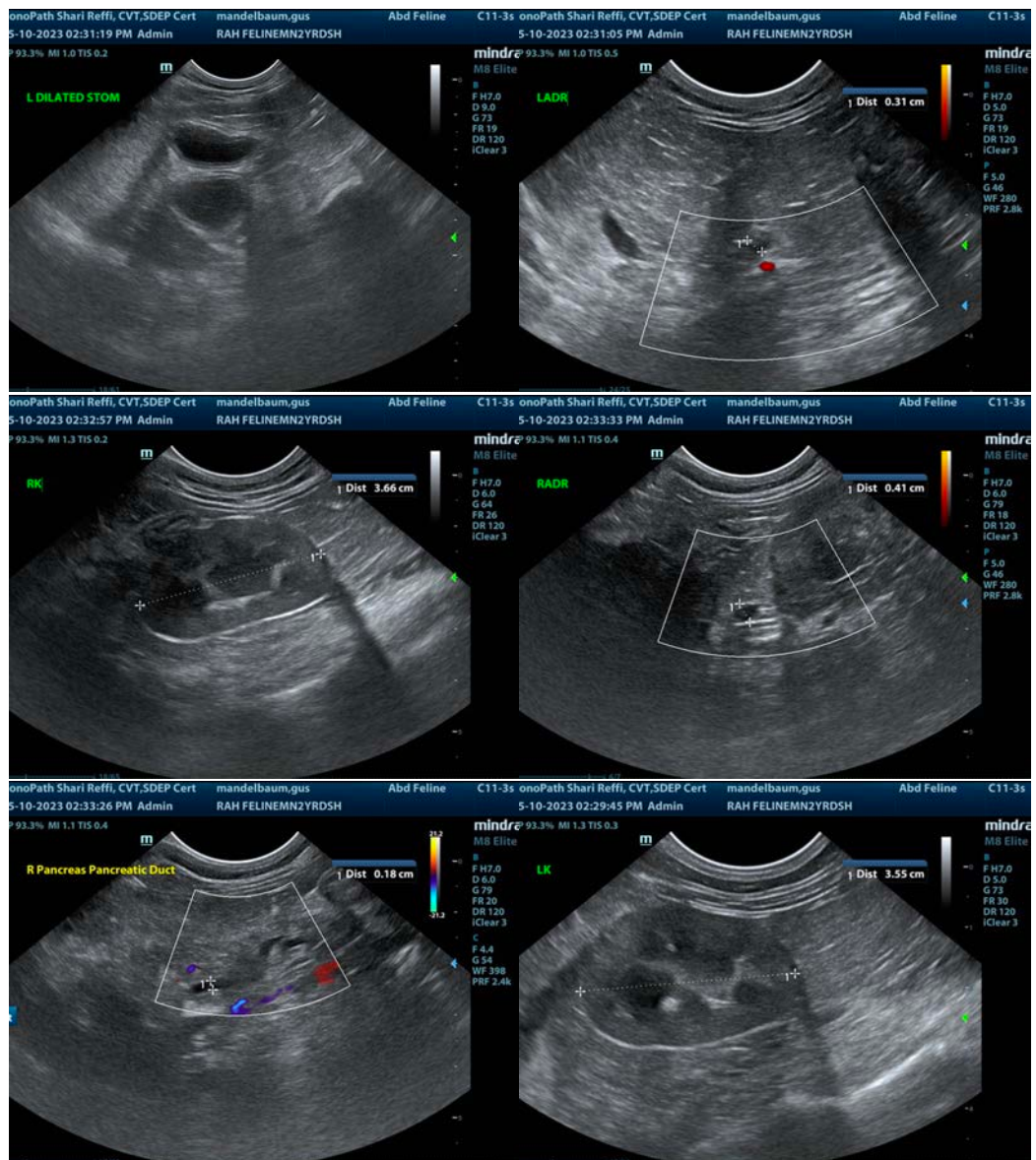
Dr. Maniar

INVOICE

47273

DATE

5/10/23



The information and recommendations provided are based on the images presented by the referring veterinarian/sonographer. No evaluation can be communicated regarding pathology that was not visible in the image/video clips provided.

Thank you for this referral. If the clinical or image interpretation does not parallel your findings or if I can be of any further assistance please contact me.

Eric Lindquist, DMV, DABVP, Cert. IVUSS, CEO of SonoPath.com

info@SonoPath.com