



**PATIENT**

Beau Chabot

**SPECIES**

Canine

**BREED**

German Shepherd X

**SEX**

Neutered Male

**AGE**

14 Months

**WEIGHT**

31.5 kg

**INTERPRETED BY**

Eric Lindquist, DMV  
DABVP, Cert. IVUSS

**IMAGING PERFORMED BY**

Dr. Wood

**HOSPITAL NAME**

Windermere VH

**REFERRING VET**

Dr. Dani Wood

**INVOICE**

22452

**DATE**

5/10/23

**PRESENTING CLINICAL SIGNS**

History: Dribbling urine last 2 weeks, accidents in bed (sleeping and awake). U/A normal. Concerned for ectopic ureter.

\*2 AVI videos and 7 still BMP images were submitted. Please send in dicom format.

**LIMITED ULTRASONOGRAPHIC EXAMINATION**

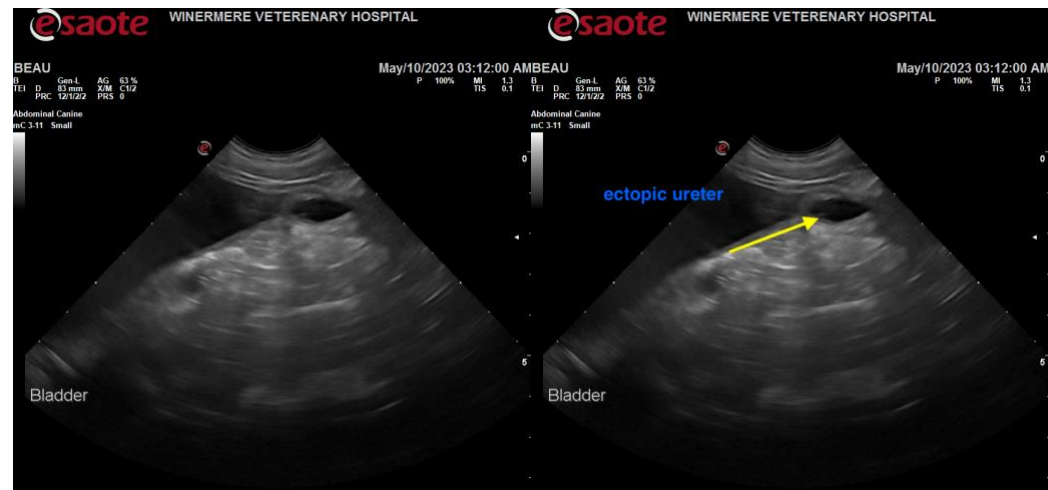
2 videos of the bladder were submitted, one of which revealed what appeared to be an abnormal ectopic ureter, measuring approximately 5.0 m in width. This appeared to bypass the ureteral papilla and likely enters into the deep pelvic urethra. The urinary bladder wall and urine appeared unremarkable.

**ULTRASONOGRAPHIC FINDINGS**

- Ectopic ureter

**INTERPRETATION OF THE FINDINGS & FURTHER RECOMMENDATIONS**

Further definition through exploratory surgery is indicated. IVP radiograph series or CT with contrast is recommended. Surgical consult is recommended. The exact type of ectopic ureter cannot be ascertained (whether intra- or extramural), but subjectively appears extramural and likely terminates in the pelvic urethra. However, further imaging would be necessary to define this further.



**The information and recommendations provided are based on the images presented by the referring veterinarian. No evaluation can be communicated regarding pathology that was not visible in the image/video clips provided.**

Thank you for this referral. If the clinical or image interpretation does not parallel your findings or if I can be of any further assistance please contact me.

**Eric Lindquist**, DMV, DABVP, Cert. IVUSS, CEO of SonoPath.com  
info@SonoPath.com