



PATIENT PRESENTING CLINICAL SIGNS

Parsus Shreve
History of nasal discharge, sneezing, wheezing and coughing. Per O, these symptoms seem worse in the mornings and when outside. There is some improvement with Baytril but symptoms always come back. He is still e/d normal and u/d normal per O. Bloodwork done on 5/2/22 showed neutrophilia, elevated pancreatic values as well as ALT, AST, and Alk phos. There were also decreased electrolytes, increased glucose and abnormal protein levels. There was no sign of a UTI but there was proteinuria but was concentrating still. His abdomen is tense and appears bloated.
Abnormal PE/Chem/CBC/UA Results: Attached are the most recent bloodwork results from 5/2/22 and the radiograph taken that day as well.

SPECIES

Canine

BREED

Jack Russell Mix

ULTRASONOGRAPHIC EXAMINATION OF THE ABDOMEN

Urinary System

SEX

Male

The **urinary bladder**, trigone, and pelvic urethra presented normal thicknesses and normal tone. The ureters were not visible which is normal. No uroliths or sediment were visualized and anechoic urine was present. No evidence of inflammatory or neoplastic changes was noted. Ureteral papillae were normal.

AGE

10 years

The **kidneys** revealed normal size and structure, corticomedullary definition and ratio for this age. The cortices presented largely uniform texture with normal echogenic relationship to liver and spleen. Medullary structure differed distinctly from the cortex and no evidence of pelvic dilation was present. The capsules were acceptably uniform without significant irregularities. The left kidney measured 4.5 cm.

WEIGHT

16.4 lbs

INTERPRETED BY

Eric Lindquist, DMV
DABVP, Cert. IVUSS

Adrenal Glands

The regions of the **adrenal glands** were imaged, yet there was no evidence of pathology.

IMAGING PERFORMED BY

Sammy Burmeister and
Dr. Faith

Spleen

The **spleen** in this patient was mildly enlarged with uniform parenchyma and was folded upon itself cranially. This is a positional variant and is not pathological. There was no evidence of significant disease.

HOSPITAL NAME

Faith Animal Care

Liver

REFERRING VET

Dr. Faith

The **liver** images from right and left intercostal as well as subcostal views revealed subjectively normal liver size, contour, and structure. Some age-related parenchymal remodeling was noted but likely not clinically significant at this time. Vascular and biliary tracts were of normal volume and no evidence of congestion was noted. Minor gallbladder polyps were noted.

INVOICE

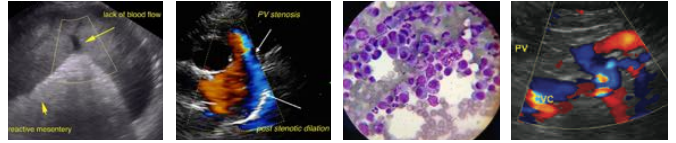
30255

Gastrointestinal

DATE

5/10/22

Examination of the **gastrointestinal tract** revealed a stomach and intestine free of stasis, of normal wall thickness, acceptable curvilinear mural detail, and peristaltic activity. Small and large intestine



PATIENT

demonstrated normal luminal chyme and stool consistency respectively. No obstructive or overt infiltrative disease was noted. No associated abnormal lymphatic activity was noted.

Parsus Shreve

SPECIES

Pancreas

Canine

The base and limbs of the **pancreas** were observed to be largely isoechoic to surrounding omental fat. Pancreatic duct and capsular contour were acceptably normal and parenchyma respected normal curvilinear patterns. No overt evidence of active inflammatory or neoplastic disease was noted.

BREED

Jack Russell Mix

Free Abdomen

SEX

A large amount of abdominal fat was noted in this patient particularly in the sublumbar area. This is consisting of a large lipoma and measures approximately 8.0 x 5.0cm.

Male

AGE

ULTRASONOGRAPHIC FINDINGS

10 years

Sublumbar/caudal abdominal lipoma subjectively benign only space occupying.

Benign hepatopathy with gallbladder polyps.

WEIGHT

Age related renal changes.

16.4 lbs

Folded spleen.

INTERPRETED BY

INTERPRETATION OF THE FINDINGS & FURTHER RECOMMENDATIONS

Eric Lindquist, DMV
DABVP, Cert. IVUSS

FNA of the liver could be considered for further definition.

IMAGING PERFORMED BY

Sammy Burmeister and
Dr. Faith

HOSPITAL NAME

Faith Animal Care

REFERRING VET

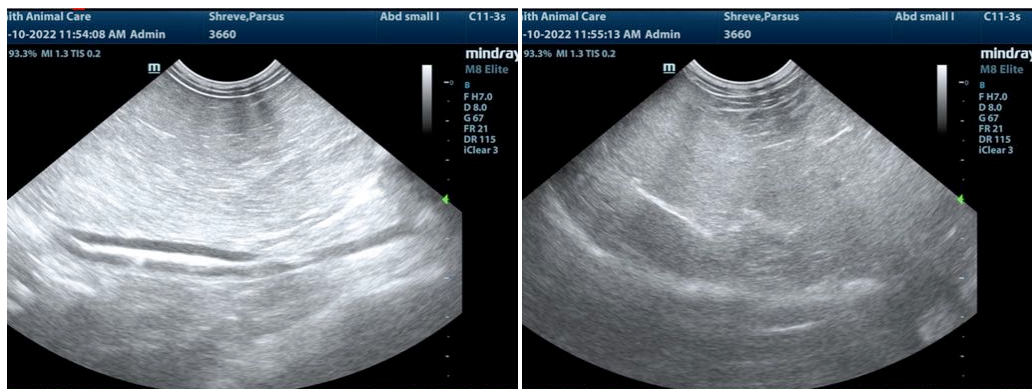
Dr. Faith

INVOICE

30255

DATE

5/10/22





PATIENT

Parsus Shreve

SPECIES

Canine

BREED

Jack Russell Mix

SEX

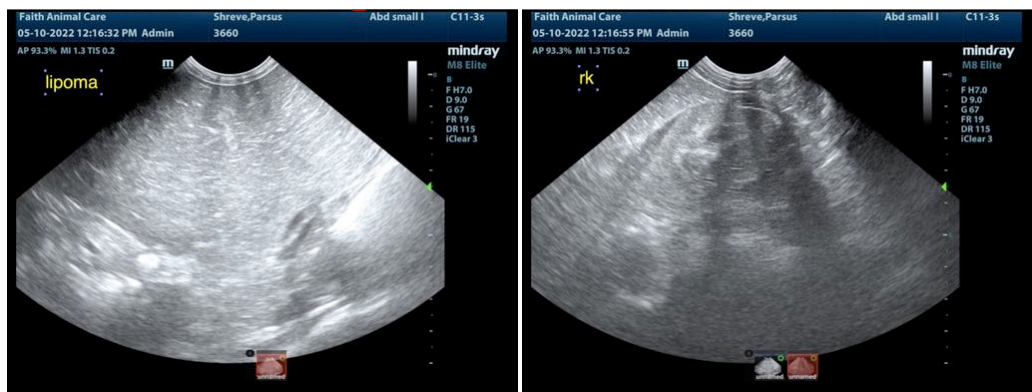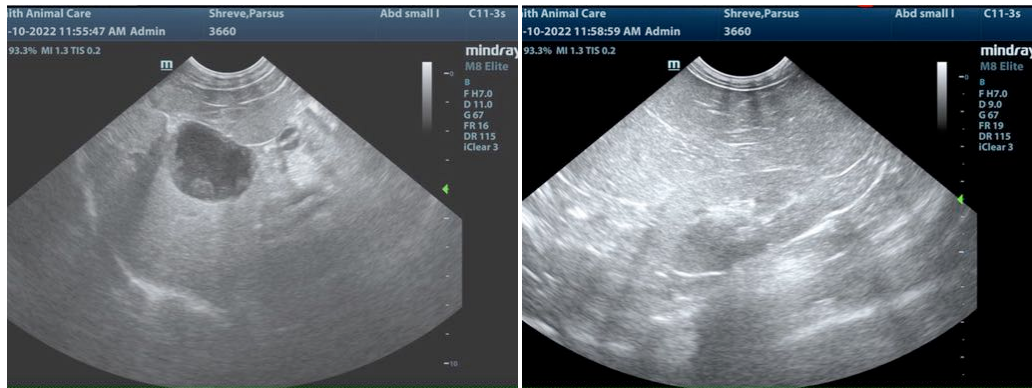
Male

AGE

10 years

WEIGHT

16.4 lbs



INTERPRETED BY

Eric Lindquist, DMV
DABVP, Cert. IVUSS

IMAGING PERFORMED BY

Sammy Burmeister and
Dr. Faith

HOSPITAL NAME

Faith Animal Care

REFERRING VET

Dr. Faith

INVOICE

30255

DATE

5/10/22

The information and recommendations provided are based on the images presented by the referring veterinarian/sonographer. No evaluation can be communicated regarding pathology that was not visible in the image/video clips provided.

Thank you for this referral. If the clinical or image interpretation does not parallel your findings or if I can be of any further assistance please contact me.

Eric Lindquist, DMV, DABVP, Cert. IVUSS, CEO of SonoPath.com
info@SonoPath.com