



**PATIENT PRESENTING CLINICAL SIGNS**

Patient: Leo Cabrera  
 History: Periapical abscess, newly appreciate heart murmur. Echo pre-anesthesia. History of diabetes, cataracts, severe dental disease

**SPECIES BREED SEX AGE WEIGHT ULTRASONOGRAPHIC EXAMINATION OF THE HEART**

Canine

Pomeranian

Neutered male

13 years

16 lbs

The echocardiogram in this patient demonstrated normal **left atrial** size based on 3 different LA measurement methods. Moderate filling of the left atrium was noted on color flow assessment. Chamber volumes and echogenicity were normal. The cranial and caudal **mitral** valve leaflets presented vegetative thickening consistent with endocardiosis. Doppler indicated measurable insufficiency. The **left ventricle** presented thicknesses with linear contour and was not dilated nor restricted. The **myocardium** presented normal echogenicity without subjective evidence of significant fibrotic or ischemic disease. **Contractility** of the ventricular walls was adequate and in normal range for this patient evidenced by the fractional shortening measurement and subjective evaluation of the different regions of the myocardium. The **left ventricular outflow** tract demonstrated normal laminar flow and subjective structural integrity. The **right atrium** and auricle revealed normal size, structure and content. No evidence of masses was noted or chamber overload. **Tricuspid** valvular assessment demonstrated adequate linear morphology. The **right ventricle** was of normal size (1/3 diameter of LV), chordae structure, myocardial echogenicity and thickness. **Pulmonic** tract assessment revealed normal valve structure, laminar flow, and diameter (approx. 1:1 pa/ao ratio). No visible **pericardial** or free pleura fluid was noted. No echographically detectable evidence of infiltrative disease was visible. The cranial **mediastinum and pericardial regions** were free of masses in the visible window.

**INTERPRETED BY**

Eric Lindquist, DMV  
 DABVP, Cert. IVUSS

**IMAGING PERFORMED BY**

Dr. Petrone

**HOSPITAL NAME**

Long Branch AH

**REFERRING VET**

Dr. Petrone

**INVOICE**

30232

**DATE**

5/10/22

CANINE	MR	TR	LA/AO	LA/AO	FS	EF	EPSS
<b>CARDIAC PARAMETERS</b>	<b>VMAX</b> (m/s)	<b>VMAX</b> (m/s)	(Boon method)	(Heart Base; Swe)	(%)	(%)	(cm)
<b>NORMAL PARAMETER</b>	4.5-5.5	<2.7	1.3	<1.3	28-40	40-100	<0.6
<b>PATIENT</b>	6.0		NM	1.4	40	80	0.1
CANINE	HR	AV	PV	BODY WEIGHT	LA	LVIDd	LVIDs
<b>CARDIAC PARAMETERS</b>	(BPM)	<b>VMAX</b> (m/s)	<b>MAX</b> (m/s)		2D short axis Base view (cm)	Avg; 2D and m-mode short axis (cm)	Avg; 2D and m-mode short axis (cm)
<b>NORMAL PARAMETER</b>	50-100	0.7-1.7	0.7-1.6				
<b>PATIENT</b>		NM	NM	16 lbs	3.03 max	2.5	



**PATIENT                      ULTRASONOGRAPHIC FINDINGS**

Leo Cabrera                      Stage B1 valvular disease.

**SPECIES                      INTERPRETATION OF THE FINDINGS & FURTHER RECOMMENDATIONS**

Canine                      No appreciable atrial enlargement was noted.

**BREED**                      B1: The heart is stable without clinical disease. No overt contraindication for anesthesia of brief to moderate duration. I suggest Torbutrol premed, Propofol induction, Isoflurane maintenance or similar protocol if anesthesia is desired. Blood pressure recommended if not already performed and target white coat negative systolic pressure of < 160 mmHg. If higher than this ACE-inhibitor is suggested to reach this level. Recheck echocardiogram is recommended in 6 months, earlier if murmur grade increases or clinical signs initiate.

**SEX**  
Neutered male

**AGE**  
13 years

**WEIGHT**  
16 lbs

**INTERPRETED BY**  
Eric Lindquist, DMV  
DABVP, Cert. IVUSS

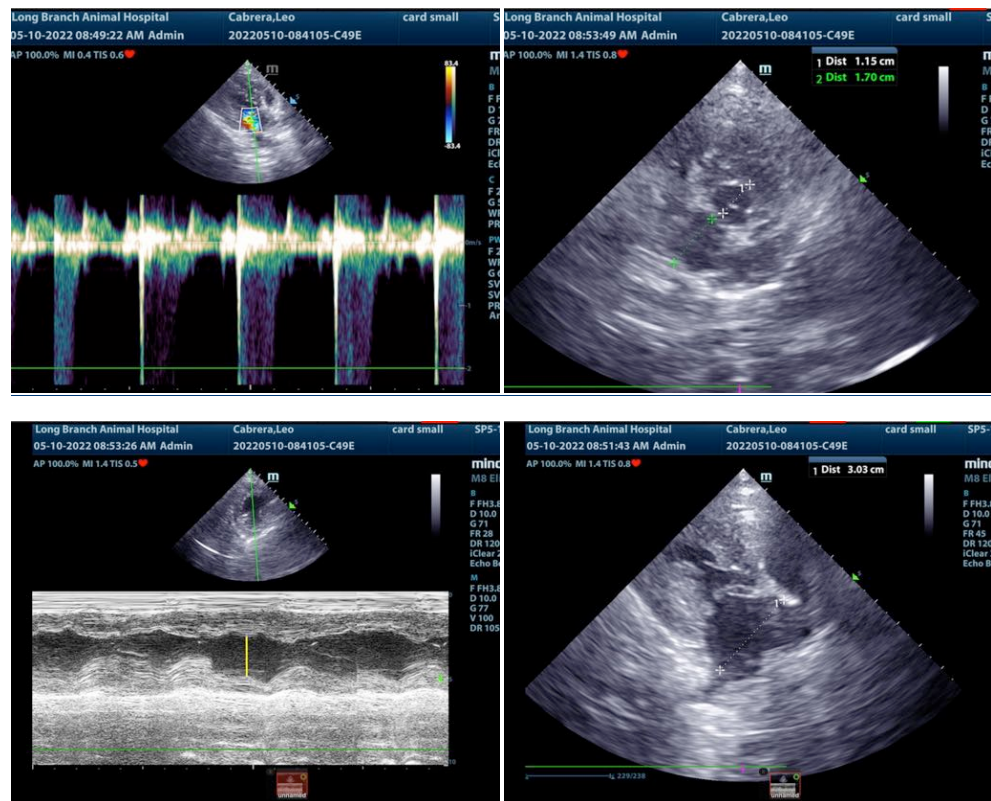
**IMAGING PERFORMED BY**  
Dr. Petrone

**HOSPITAL NAME**  
Long Branch AH

**REFERRING VET**  
Dr. Petrone

**INVOICE**  
30232

**DATE**  
5/10/22





**PATIENT**

Leo Cabrera

**SPECIES**

Canine

**BREED**

Pomeranian

**SEX**

Neutered male

**AGE**

13 years

**WEIGHT**

16 lbs

**INTERPRETED BY**

Eric Lindquist, DMV  
DABVP, Cert. IVUSS

**IMAGING PERFORMED BY**

Dr. Petrone

**HOSPITAL NAME**

Long Branch AH

**REFERRING VET**

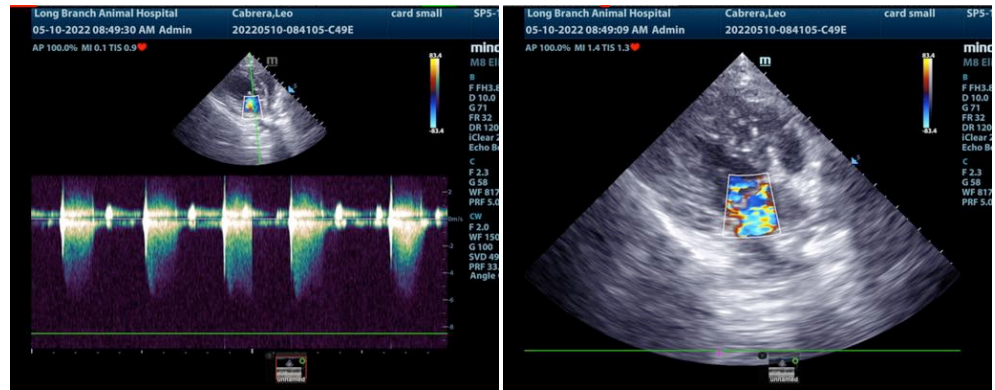
Dr. Petrone

**INVOICE**

30232

**DATE**

5/10/22



The information and recommendations provided are based on the images presented by the referring veterinarian/sonographer. No evaluation can be communicated regarding pathology that was not visible in the image/video clips provided.

Thank you for this referral. If the clinical or image interpretation does not parallel your findings or if I can be of any further assistance please contact me.

Eric Lindquist, DMV, DABVP, Cert. IVUSS, CEO of SonoPath.com  
info@SonoPath.com