



PATIENT PRESENTING CLINICAL SIGNS

Hans Hynes Vomiting blood.

SPECIES ULTRASONOGRAPHIC EXAMINATION OF THE ABDOMEN
Urinary System

Feline

BREED

Domestic Shorthair

The **urinary bladder**, trigone, and pelvic urethra presented normal thicknesses and normal tone. The ureters were not visible which is normal. No uroliths or sediment were visualized and anechoic urine was present. No evidence of inflammatory or neoplastic changes was noted. Ureteral papillae were normal.

SEX

Neutered male

AGE

13 years

The **kidneys** revealed largely normal size and structure, corticomedullary definition and ratio (cortex 1/3 of medulla) were essentially maintained with some age-related loss of curvilinear patterns regarding the capsule and C/M junction. The cortices presented largely uniform texture with some increased echogenicity expected for this age patient. Medullary structure differed distinctly from that of the cortex and no evidence of pelvic dilation was present. The left kidney measured 4.43 cm. The right kidney measured 4.11 cm.

WEIGHT

14 lbs

Adrenal Glands

Both **adrenal glands** were visualized and recognized as having normal shape, size, position and echogenicity for this breed. The phrenic vasculature, glandular echogenicity and detail were unremarkable. Capsule, cortex, and medullary definition were normal for this age patient. The right adrenal gland measured 0.48 cm. The left adrenal gland measured 0.48 cm.

INTERPRETED BY

Eric Lindquist, DMV
DABVP, Cert. IVUSS

Spleen

IMAGING

PERFORMED BY

Diane McFadden, RVT

The **spleen** presented a smooth homogeneous parenchyma hyperechoic to liver and renal cortical parenchyma. The capsule was smooth without noticeable expansion or deviation from within the spleen or adjacent pathology. The splenic vasculature demonstrated normal volume without signs of congestion or thrombosis. No sonographic evidence of acute or chronic inflammatory, neoplastic, or infarctual changes was noted.

HOSPITAL NAME

Rockaway AH

Liver

REFERRING VET

Dr. Maniar

The **liver** images submitted revealed subjectively normal liver size, contour, and structure. Parenchymal echogenicity was naturally coarse and hypoechoic to the spleen. Vascular and biliary tracts were of normal volume with no evidence of congestion. The gallbladder presented acceptably thin walls with primarily anechoic content. The cystic and common bile ducts were normal. No pathological hepatic lymphadenopathy was evident. No overt structural evidence of inflammatory, infiltrative or regenerative pathology was evident.

INVOICE

30244

DATE

5/10/22



PATIENT

Gastrointestinal

Hans Hynes

SPECIES

Feline

BREED

Domestic Shorthair

SEX

Neutered male

AGE

13 years

WEIGHT

14 lbs

INTERPRETED BY

Eric Lindquist, DMV
DABVP, Cert. IVUSS

IMAGING PERFORMED BY

Diane McFadden, RVT

HOSPITAL NAME

Rockaway AH

REFERRING VET

Dr. Maniar

INVOICE

30244

DATE

5/10/22

The **gastrointestinal** presentation revealed mild uniform prominence of the gastric mucosa as well as areas of "ropey" small intestinal wall with slight disruption of the normal 1:3 muscularis/mucosal ratio. The intestinal submucosa was slightly irregular, thickened and hyperechoic suggestive of low grade, chronic disease. No concerning lymphadenopathy was visible. No evidence of obstruction was present. Chronic inflammatory bowel disease is likely with a low possibility of an early neoplastic event such as lymphoma. Full thickness tissue biopsies via open laparotomy, ideally guided by intraoperative ultrasound in order to obtain the most representative mural sample, would be necessary to rule out this possibility.

Pancreas

The **pancreas** revealed a 1.0 cm coalesced cyst at the left limb and left base.

ULTRASONOGRAPHIC FINDINGS

IBD GI pattern.

Geriatric abdomen with benign pancreatic cysts.

INTERPRETATION OF THE FINDINGS & FURTHER RECOMMENDATIONS

A clinical trial of the following may prove effective. If clinical signs persist then full thickness intestinal biopsies are warranted for long term management.

Triaditis/Pancreatitis protocol

Part or all of this protocol may be considered based on your clinical impression of the patient:

Recommend pain management when anorexic with **Buprenorphine** (0.01-0.02 mg/kg IM or SC), clinical trial of **Zithromax** (50 mg sid/cat x 10 days, 3 weeks if bartonella +), **Prednisolone** (0.5-2 mg/kg tapering over 1 week to minimal effective dose), and **B12 injections** if weight loss (Cyanobalamine 250 mcg sub-q once-weekly x six weeks, then every other week for six weeks and then once-monthly, long-term if necessary), **novel-protein or hydrolyzed diet** (*Hydrolyzed diets have been shown to be more effective in dietary intolerance case management compared to hypoallergenic diets*) or the **magical Purina DM** (changing protein source is crucial and may need rotation every 6 months if clinical signs recur) Diet trials is a whatever works phenomenon. If vomiting becomes a persistent issue then endoscopy would be warranted and/or recheck sonogram to assess more emerging disease. One diet does not work for all patients so different trials may be necessary or protein source rotation every 6 months as new sensitivities develop.



PATIENT

Hans Hynes

SPECIES

Feline

BREED

Domestic Shorthair

SEX

Neutered male

AGE

13 years

WEIGHT

14 lbs

INTERPRETED BY

Eric Lindquist, DMV
DABVP, Cert. IVUSS

IMAGING PERFORMED BY

Diane McFadden, RVT

HOSPITAL NAME

Rockaway AH

REFERRING VET

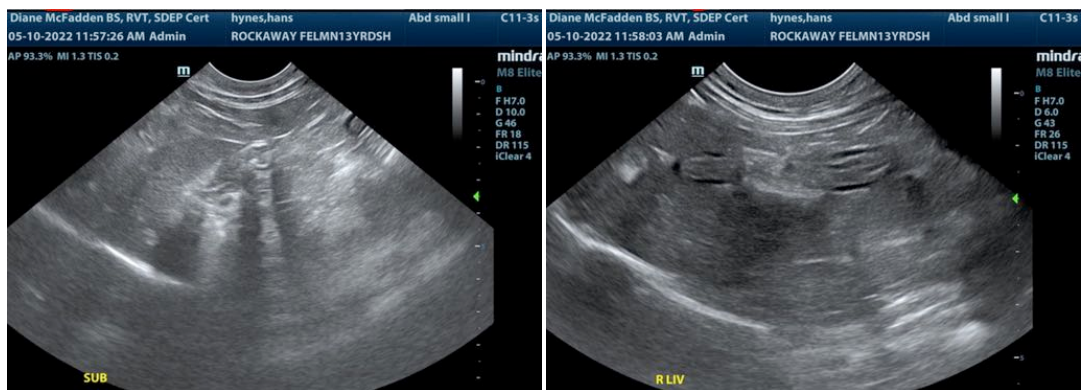
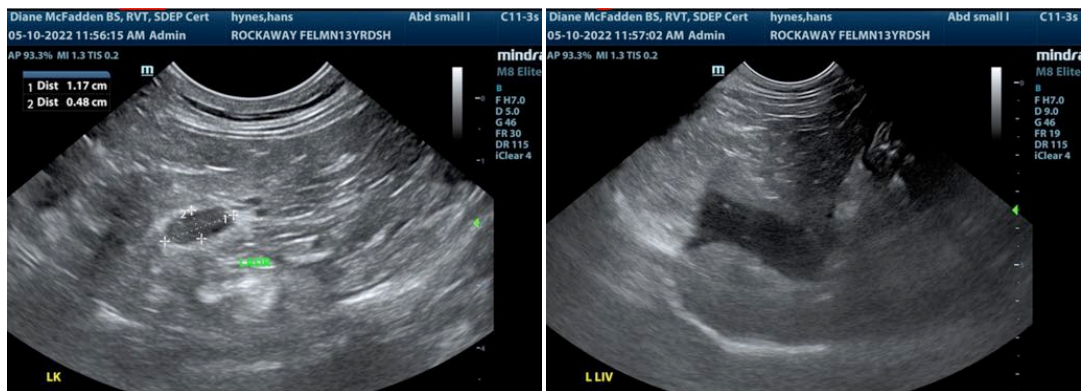
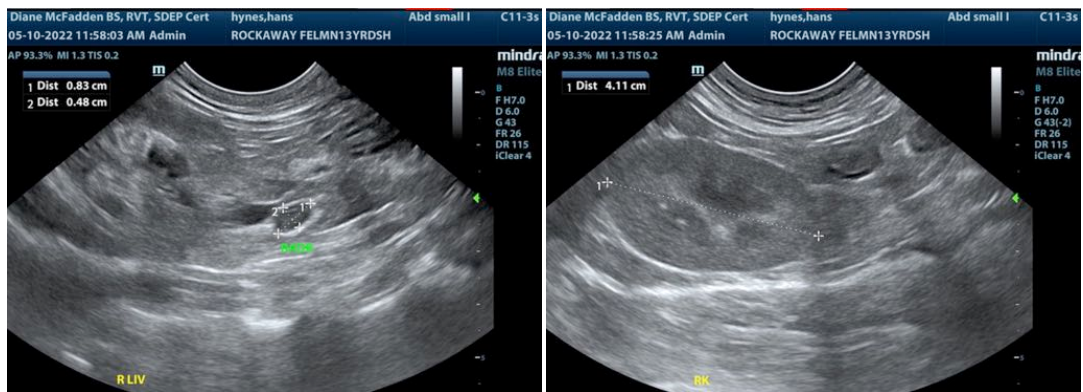
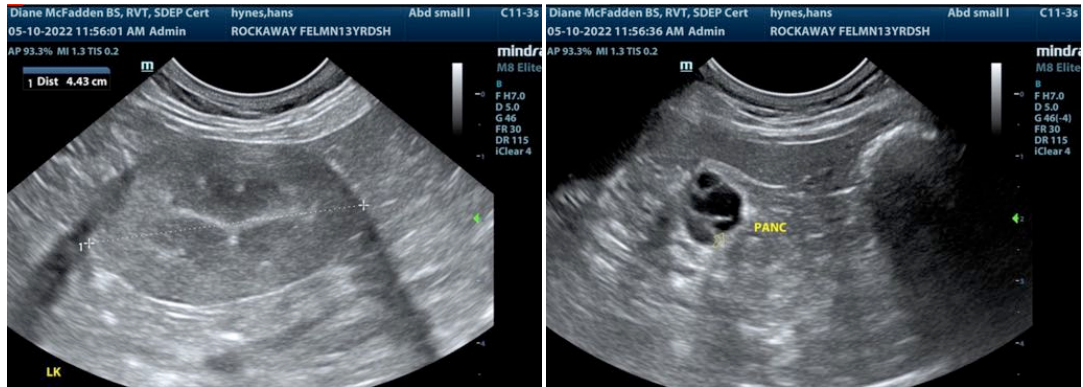
Dr. Maniar

INVOICE

30244

DATE

5/10/22





PATIENT

Hans Hynes

SPECIES

Feline

BREED

Domestic Shorthair

SEX

Neutered male

AGE

13 years

WEIGHT

14 lbs

INTERPRETED BY

Eric Lindquist, DMV
DABVP, Cert. IVUSS

IMAGING PERFORMED BY

Diane McFadden, RVT

HOSPITAL NAME

Rockaway AH

REFERRING VET

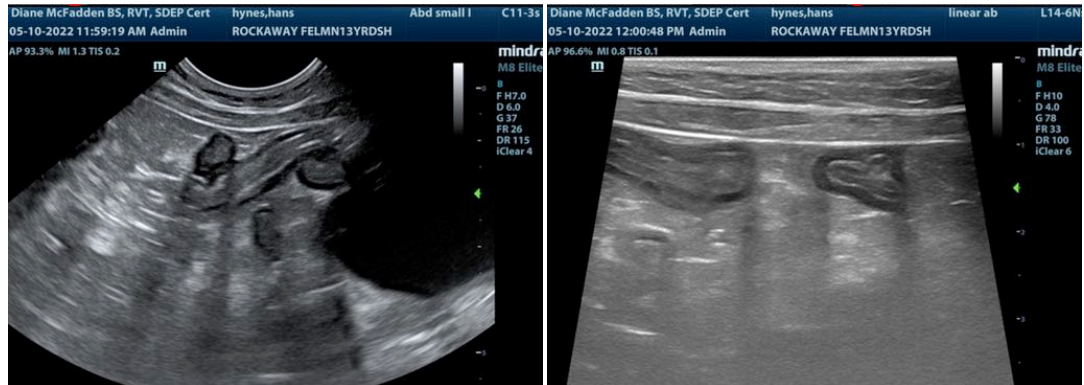
Dr. Maniar

INVOICE

30244

DATE

5/10/22



The information and recommendations provided are based on the images presented by the referring veterinarian/sonographer. No evaluation can be communicated regarding pathology that was not visible in the image/video clips provided.

Thank you for this referral. If the clinical or image interpretation does not parallel your findings or if I can be of any further assistance please contact me.

Eric Lindquist, DMV, DABVP, Cert. IVUSS, CEO of SonoPath.com
Info@SonoPath.com