



PATIENT

Ginger Pierce

SPECIES

Canine

BREED

Lab mix

SEX

Spayed Female

AGE

7 years

WEIGHT

72 lbs

INTERPRETED BY

Eric Lindquist, DMV
DABVP, Cert. IVUSS

IMAGING PERFORMED BY

Dr. Rodriguez

HOSPITAL NAME

Foxfield VS

REFERRING VET

Dr. Rodriguez

INVOICE

30262

DATE

5/10/22

PRESENTING CLINICAL SIGNS

History: Recently dx diabetic. O reports lethargy and decreased appetite while on insulin. Decreased appetite.

Abnormal PE/Chem/CBC/UA Results: Pending

ULTRASONOGRAPHIC EXAMINATION OF THE ABDOMEN

Urinary System

The **bladder** in this patient was mildly thickened with slight echogenic mural changes. No calculi or masses were noted. Slight micropolypoid changes were noted. This is a frequent finding in older animals and may be linked to a history of chronic urinary tract infection or active urinary tract infection.

Urinalysis would be recommended with culture if any evidence of inflammatory sediment is present.

The region of the trigone and visible pelvic urethra were normal.

The **kidneys** were normal in size and contour; however, a minor hyperechoic ring was noted at the corticomedullary junction. This is consistent with diabetic nephropathy. This is likely from glucosuria. However, assessment for proteinuria is also warranted. This is an idiopathic finding, but an expected finding in diabetic patients. The left kidney measured 8.44 cm. The right kidney measured 8.0 cm.

Adrenal Glands

Both **adrenal glands** were visualized and recognized as having normal shape, size, position and echogenicity for this breed. The phrenic vasculature, glandular echogenicity and detail were unremarkable. Capsule, cortex, and medullary definition were normal for this age patient. The right adrenal gland measured 2.78 x 0.76 cm. The left adrenal gland measured 1.65 x 0.68 cm.

Spleen

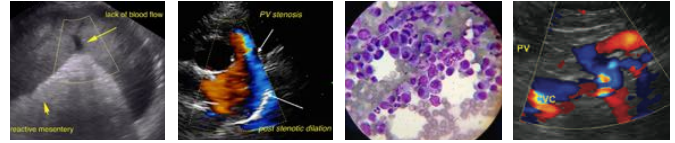
The **spleen** presented a smooth homogeneous parenchyma hyperechoic to liver and renal cortical parenchyma. The capsule was smooth without noticeable expansion or deviation from within the spleen or adjacent pathology. The splenic vasculature demonstrated normal volume without signs of congestion or thrombosis. No sonographic evidence of acute or chronic inflammatory, neoplastic, or infarctual changes was noted.

Liver

The **liver** in this patient was mildly enlarged and uniform with hyperechoic parenchymal changes. There were subtle, hypoechoic heterogenous nodular changes. The gallbladder and common bile duct were unremarkable other than a minor amount of gallbladder sludge/debris.

Gastrointestinal

Examination of the **gastrointestinal tract** revealed a stomach and intestine free of stasis, of normal wall thickness, acceptable curvilinear mural detail, and peristaltic activity. Small and large intestine



PATIENT

Ginger Pierce

demonstrated normal luminal chyme and stool consistency respectively. No obstructive or overt infiltrative disease was noted. No associated abnormal lymphatic activity was noted.

SPECIES

Canine

Pancreas

The base and limbs of the **pancreas** were observed to be largely isoechoic to surrounding omental fat. Pancreatic duct and capsular contour were acceptably normal and parenchyma respected normal curvilinear patterns. No overt evidence of active inflammatory or neoplastic disease was noted.

BREED

Lab mix

ULTRASONOGRAPHIC FINDINGS

SEX

Spayed Female

Diabetic hepatopathy, diabetic nephropathy.
Minor bladder thickening.

AGE

7 years

INTERPRETATION OF THE FINDINGS & FURTHER RECOMMENDATIONS

Assessment for UTI, bile acids profile and ultrasound-guided hepatic FNA are all indicated as well as culture of the hepatic FNA to rule out suppurative hepatitis.

WEIGHT

72 lbs

Potential Causes of Diabetic Dysregulation

This is a suggestive checkoff list when faced with an unregulated diabetic patient:

INTERPRETED BY

Eric Lindquist, DMV
DABVP, Cert. IVUSS

UTI

Dietary indiscretion/intolerance

IMAGING PERFORMED BY

Dr. Rodriguez

Pancreatitis

Hyperthyroidism/hypothyroidism

HOSPITAL NAME

Foxfield VS

Exogenous steroids (including topical eye meds)

Cushing's

Acromegaly

REFERRING VET

Dr. Rodriguez

Owner compliance

Insulin quality issues

Antibodies to insulin

INVOICE

30262

Underlying Neoplasia

Diffuse liver disease

DATE

5/10/22



PATIENT

Ginger Pierce

SPECIES

Canine

BREED

Lab mix

SEX

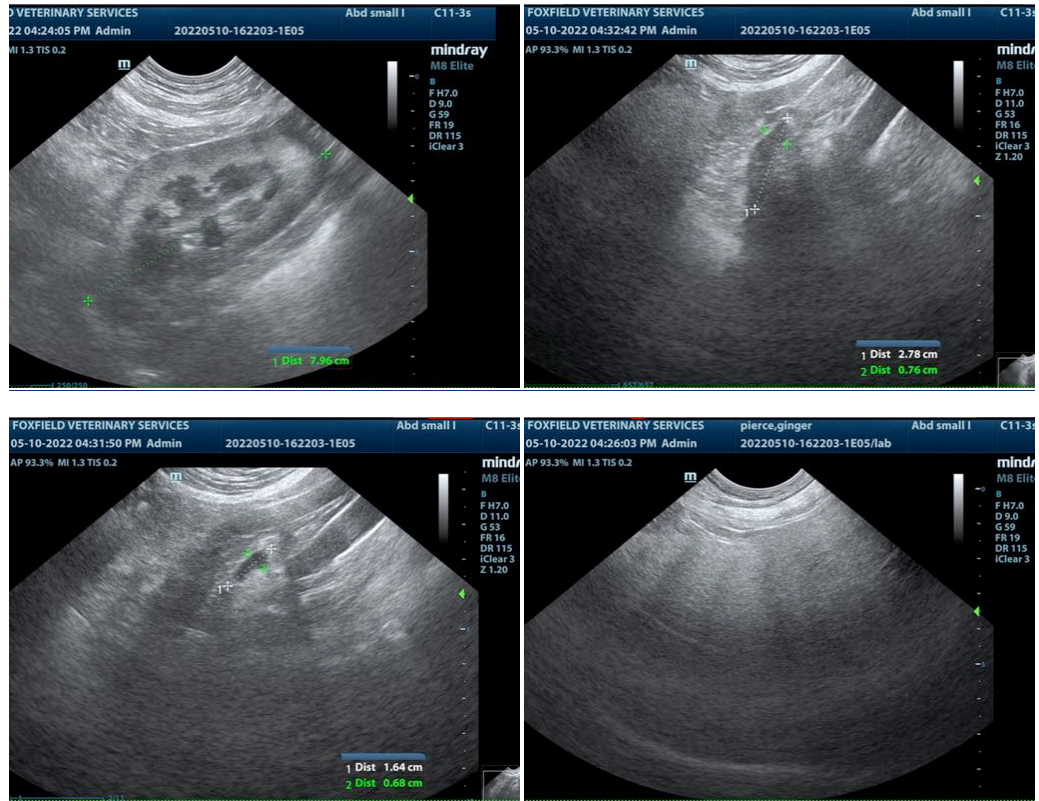
Spayed Female

AGE

7 years

WEIGHT

72 lbs



INTERPRETED BY

Eric Lindquist, DMV
DABVP, Cert. IVUSS

The information and recommendations provided are based on the images presented by the referring veterinarian/sonographer. No evaluation can be communicated regarding pathology that was not visible in the image/video clips provided.

IMAGING PERFORMED BY

Dr. Rodriguez

Thank you for this referral. If the clinical or image interpretation does not parallel your findings or if I can be of any further assistance please contact me.

HOSPITAL NAME

Foxfield VS

Eric Lindquist, DMV, DABVP, Cert. IVUSS, CEO of SonoPath.com
info@SonoPath.com

REFERRING VET

Dr. Rodriguez

INVOICE

30262

DATE

5/10/22