



**PATIENT**

Falkor Guzman

**SPECIES**

Canine

**BREED**

Lab X

**SEX**

Neutered Male

**AGE**

6 Years

**WEIGHT**

37 kg

**INTERPRETED BY**

Eric Lindquist, DMV

DABVP, Cert. IVUSS

**IMAGING PERFORMED BY**

Dr. Belan

**HOSPITAL NAME**

Legacy Vet Clinic

**REFERRING VET**

Dr. Jajouei

**INVOICE**

37600

**DATE**

5/10/22

**PRESENTING CLINICAL SIGNS**

Pyrexia of unknown origin last 3 days  
Abnormal PE/Chem/CBC/UA Results: 4DX negative mild elevation of liver enzymes and Addison's negative.

**ULTRASONOGRAPHIC EXAMINATION OF THE ABDOMEN**

**Urinary System**

The **urinary bladder**, trigone, and pelvic urethra presented normal thicknesses and normal tone. The ureters were not visible which is normal. No uroliths or sediment were visualized and anechoic urine was present. No evidence of inflammatory or neoplastic changes were noted. Ureteral papillae were normal. The residual prostate measured 1.02 cm.

The **kidneys** revealed normal size and structure, corticomedullary definition and ratio for this age. The cortices presented largely uniform texture with normal echogenic relationship to liver and spleen. Medullary structure differed distinctly from the cortex and no evidence of pelvic dilation was present. The capsules were acceptably uniform without significant irregularities. Slight pinpoint mineralizations noted. The right kidney measured 7.2 cm. The left kidney measured 7.2 cm.

**Adrenal Glands**

Both **adrenal glands** were visualized and recognized as having normal shape, size, position and echogenicity for this breed. The phrenic vasculature, glandular echogenicity and detail were unremarkable. Capsule, cortex, and medullary definition were normal for this age patient. The left adrenal gland measured 0.64 cm at the caudal pole and 0.75 cm at the cranial pole.

**Spleen**

The **spleen** was uniformly enlarged with relatively uniform parenchyma without evidence of masses. The capsule was mildly swollen. This is most consistent with hypersplenism and reactive hyperplasia deriving from splenic white or red pulp. However, early infiltrative disease, such as lymphoma or mast cell neoplasia can, at times, present in this manner but not suspected. 25g US-guided FNA would be best in order to ensure only reactive hyperplasia is present. If clinical signs fit with potential neoplasia or mast cell disease, then Benadryl injection (1 mg/pound IM) 15 minutes prior to FNA would be recommended.

Accessory spleen noted in the left cranial abdomen, measuring 1.6 cm, round, uniform.

**Liver**

The **liver** in this patient was irregular and revealed diffuse mixed hypoechoic nodular changes up to 1.2 cm in both the left and right liver. Enhanced surrounding mesentery noted. The gallbladder was mildly congested. Right cranial hepatic nodular changes impinged upon and deviated the gallbladder.

**Gastrointestinal**

Examination of the **gastrointestinal tract** revealed a stomach and intestine free of stasis, of normal wall thickness, acceptable curvilinear mural detail, and peristaltic activity. Small and large intestine demonstrated normal luminal chyme and stool consistency respectively. No obstructive or overt infiltrative disease was noted. No associated abnormal lymphatic activity was noted.



**PATIENT**

**Pancreas**

Falkor Guzman

The left pancreatic limb presented mixed hypoechoic parenchymal changes with regional hyperechoic enhanced mesentery.

**SPECIES**

Canine

**ULTRASONOGRAPHIC FINDINGS**

- Aggressive multifocal hepatic nodular changes – metastatic or round cell neoplasia, carcinoma, fungal granulomatous disease possible.
- Concurrent ectopic spleen
- Minor renal mineralization

**BREED**

Lab X

**INTERPRETATION OF THE FINDINGS & FURTHER RECOMMENDATIONS**

**SEX**

Ultrasound guided FNA recommended. Guarded prognosis depending upon FNA. Echinococcosis possible, yet less likely, as the structures are not cystic. Fungal disease is a strong potential.

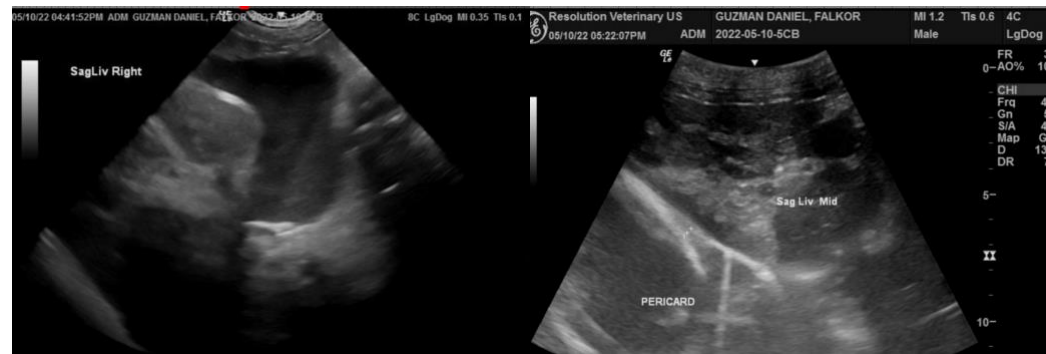Neutered Male

**AGE**

6 Years

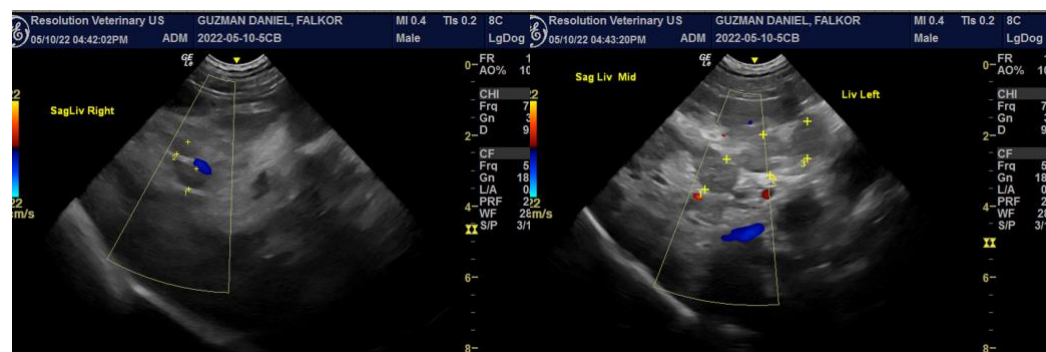
**WEIGHT**

37 kg



**INTERPRETED BY**

Eric Lindquist, DMV



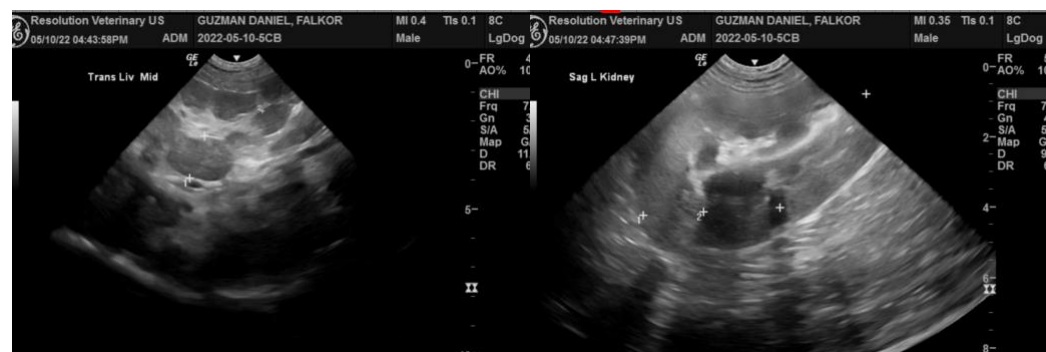DABVP, Cert. IVUSS

**IMAGING PERFORMED BY**

Dr. Belan

**HOSPITAL NAME**

Legacy Vet Clinic



**REFERRING VET**

Dr. Jajouei

**INVOICE**

37600

**DATE**

5/10/22



**PATIENT**

Falkor Guzman

**SPECIES**

Canine

**BREED**

Lab X

**SEX**

Neutered Male

**AGE**

6 Years

**WEIGHT**

37 kg

**INTERPRETED BY**

Eric Lindquist, DMV  
DABVP, Cert. IVUSS

**IMAGING PERFORMED BY**

Dr. Belan

**HOSPITAL NAME**

Legacy Vet Clinic

**REFERRING VET**

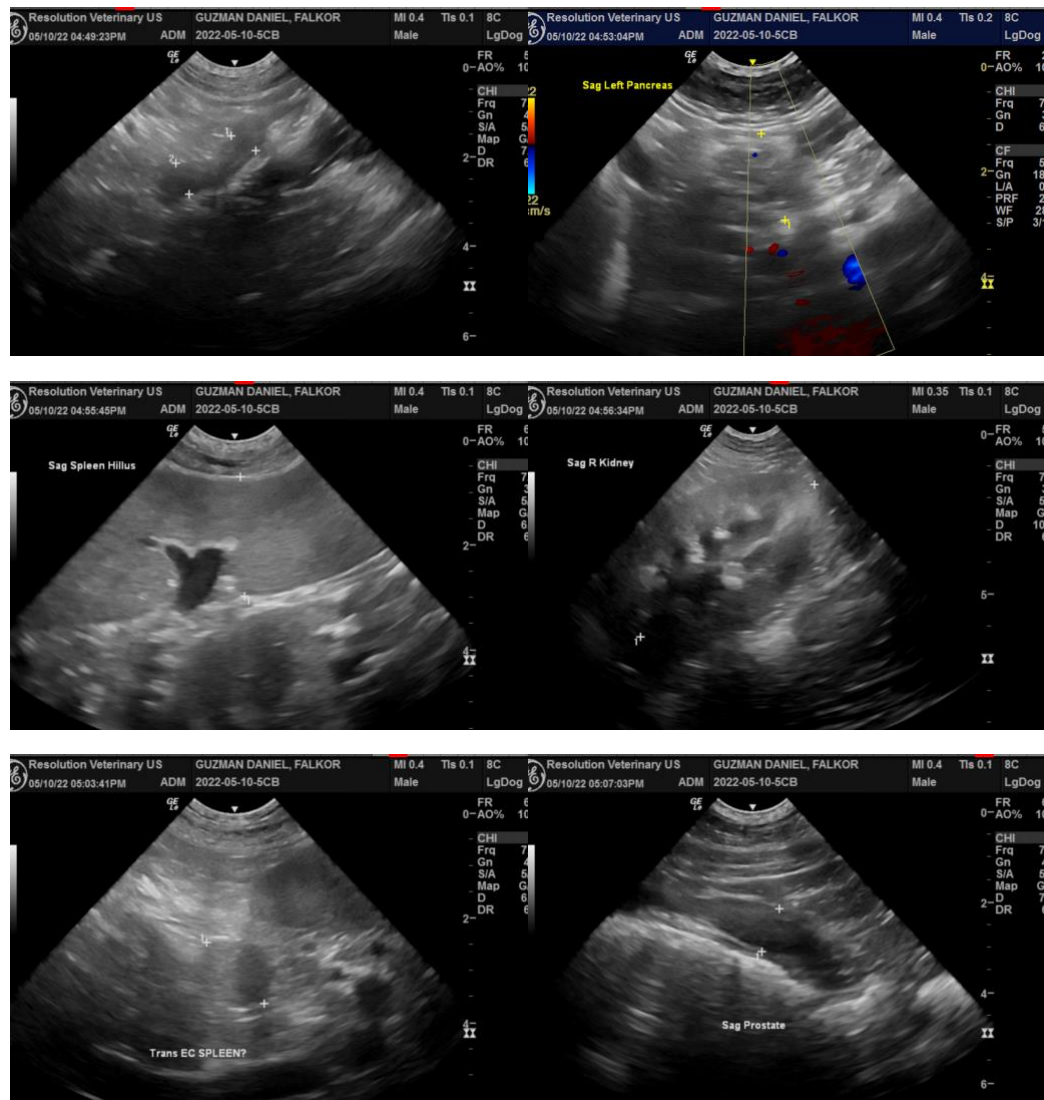
Dr. Jajouei

**INVOICE**

37600

**DATE**

5/10/22



The information and recommendations provided are based on the images presented by the referring veterinarian/sonographer. No evaluation can be communicated regarding pathology that was not visible in the image/video clips provided.

Thank you for this referral. If the clinical or image interpretation does not parallel your findings or if I can be of any further assistance please contact me.

Eric Lindquist, DMV, DABVP, Cert. IVUSS, CEO of SonoPath.com

[info@SonoPath.com](mailto:info@SonoPath.com)



**PATIENT**

Falkor Guzman

**Fever of Unknown Origin**

<http://www.sonopath.com/FUO>

**SPECIES**

Canine

**BREED**

Lab X

**SEX**

Neutered Male

**AGE**

6 Years

**WEIGHT**

37 kg

**INTERPRETED BY**

Eric Lindquist, DMV

DABVP, Cert. IVUSS

**IMAGING PERFORMED BY**

Dr. Belan

**HOSPITAL NAME**

Legacy Vet Clinic

**REFERRING VET**

Dr. Jajouei

**INVOICE**

37600

**DATE**

5/10/22

**Description:** The definition of a fever of unknown origin (FUO) has not been clearly defined for animals. Currently, it is either understood to be a fever that does not resolve within the period one would expect for a “self-limiting infection” being treated with appropriate antimicrobial therapy, or that for which an underlying diagnosis has not been determined despite considerable diagnostic effort. The common causes of FUO were summarized concisely in a presentation at the American College of Veterinary Internal Medicine 2004 Forum. The presenters synthesized information from three veterinary papers on the subject, which suggested the following:

Final Diagnosis	Bennett (dogs & cats)	Dunn and Dunn (dogs only)	Lunn (dogs & one cat)	Total
Infection	21	16	10	47
Immune	18	22	6	46
Bone marrow disease	4	22	2	28
Neoplasia (outside marrow)	0	10	2	12
Miscellaneous	2	12	2	16
No diagnosis	0	19	2	21
<b>TOTALS</b>	<b>45</b>	<b>101</b>	<b>24</b>	<b>170</b>

The types of infection diagnosed in this case series were varied, ranging from discospondylitis (8 cases), blastomycosis (6), and bacterial endocarditis (4), to leishmaniasis (1), prostatitis (1), and *Ehrlichia canis* infection (1); a multitude of other infectious causes also fell within the spectrum. Of the cases in which immune-mediated disease was found, 44% had immune-mediated polyarthritis. Bone marrow diseases included myeloproliferative disease, myelodysplasia (8), lymphocytic leukemia (8), myeloma (3), chronic granulocytic leukemia (3), lymphoblastic leukemia, and malignant histiocytosis. The types of neoplasia located outside the bone marrow included lymphoma (6), metastatic disease (2), and neoplasms of the lung, spleen, and stomach. Finally, miscellaneous diseases included hypertrophic osteodystrophy (6), meningitis (3), portosystemic shunt (3), lymphadenitis (2), panosteitis, and intervertebral disc disease. Overall, the most common causes across all cases were polyarthritis (44), lymphoid neoplasia (15), discospondylitis (8), myelodysplasia (8), hypertrophic osteodystrophy (6), and blastomycosis (6).



**PATIENT**

Falkor Guzman

**Clinical Signs:** Animals usually present with either persistent or waxing and waning fevers ranging from 103°F to 106°F. Other clinical signs depend on the underlying cause of the fever. Careful and thorough physical examination is required to assess potential causes.

**SPECIES**

Canine

**Diagnostics:** FUO etiologies are partly related to geography, and thus locale or travel history should factor into a practitioner's diagnostic approach. A patient's lifestyle may also provide clues regarding exposure to certain etiologic agents. Therefore, conducting a thorough history can unveil important pieces of the diagnostic puzzle. Physical examination is especially important and should include an inspection of all accessible lymph nodes, palpation and movement of the joints, a fundic examination, a neurological evaluation, spinal and limb palpation and range of motion tests, and a rectal examination.

**BREED**

Lab X

**SEX**

Neutered Male

A minimum database should include a CBC reviewed by a clinical pathologist, as well as a biochemical profile and urinalysis. Retroviral testing should also be considered in cats. In areas where tick-borne disease is prevalent, in-house testing should be performed early. Advanced laboratory work can include: urine culture, blood culture, and infectious disease panels (PCR and/or serology). In dogs, one may screen for the following infectious agents: *Ehrlichia* spp., *Borrelia burgdorferi*, Rock Mountain Spotted Fever, *Bartonella* spp. (culture and PCR), and *Leptospira* spp. in cases of hepatic or renal involvement. In cats, one should evaluate for FeLV, FIV, feline infectious peritonitis (FIP) virus, toxoplasmosis, *Hemoplasma* spp. (*Mycoplasma*), and *Bartonella* spp. (culture and PCR). Testing for *Ehrlichia* spp., *Rickettsia* spp., and *Anaplasma phagocytophilum* can also be considered. A fungal assay is indicated if the patient lives in or has had exposure to a region with a higher incidence of fungal disease. Other infectious disease tests may be performed depending on the geographical location of the pet. Screening for *Brucella* should be done in breeding dogs. Immune-mediated disease screening can include a Coomb's test, a slide agglutination test (if the patient is anemic), and an antinuclear antibody (ANA) test. Immune disease is often a diagnosis of exclusion.

**AGE**

6 Years

**WEIGHT**

37 kg

**INTERPRETED BY**

Eric Lindquist, DMV

DABVP, Cert. IVUSS

**IMAGING PERFORMED BY**

Dr. Belan

**HOSPITAL NAME**

Legacy Vet Clinic

**REFERRING VET**

Dr. Jajouei

Imaging should include thoracic radiographs, abdominal ultrasound, and/or abdominal radiographs. Ultrasound can be very useful for assessing evidence of cholangiohepatitis, pyelonephritis, chronic urinary tract infection, abscess formation, peritonitis, and neoplasia; it also permits an examination of the intra-abdominal lymph nodes. An echocardiogram can offer assessment for vegetative endocarditis, whereas spinal radiographs offer assessment for discospondylitis. In cases where all other testing has proven negative and the patient has not responded to broad-spectrum antibiotics and supportive care, arthrocentesis should be considered to evaluate for septic joint disease, immune-mediated polyarthritis, and infectious disease. Finally, one can consider assessing the cerebrospinal fluid for meningoencephalitis, GME, and meningitis/arteritis. A bone marrow exam should be performed if blood dyscrasias are noted on the CBC.

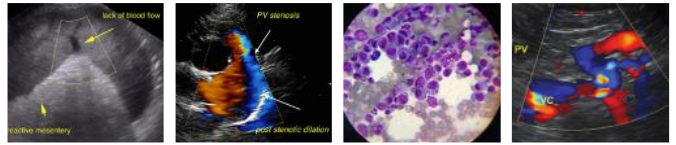
**INVOICE**

37600

**DATE**

5/10/22

**Treatment:** Treatment of the fever depends entirely on the underlying cause. Ideally, a thorough diagnostic plan will yield a diagnosis that will guide the appropriate therapeutic course. However, if an exhaustive approach has not produced a definitive diagnosis and there is no response to broad-spectrum antibiotics, trial therapy with immunosuppressive agents such as prednisolone can be considered to treat presumed immune-mediated diseases. Given the potential for negative



**PATIENT**

Falkor Guzman

sequelae should an underlying infection be present, one must be certain that the investigation is thorough and monitor the patient's response carefully.

**SPECIES**

Canine

**Conclusion:** If a documented fever has not responded to antibiotics, antipyretics, or general nursing care, it is important to obtain a diagnosis to guide more specific treatment. A systematic physical examination and thorough history-taking will help inform further diagnostics in addition to what is revealed by the minimum database.

**BREED**

Lab X

**References:**

Bennet D. Diagnosis of pyrexia of unknown origin. *In Practice* 1995;17(10):470-81.

**SEX**

Neutered Male

Dunn KJ, Dunn JK. Diagnostic investigations in 101 dogs with pyrexia of unknown origin. *J Sm Anim Pract* 1998;39(12):574-80.

**AGE**

6 Years

Flood J. The diagnostic approach to fever of unknown origin in cats. *Compend Contin Educ Vet* 2009;31(1):26-31.

Flood J. The diagnostic approach to fever of unknown origin in dogs. *Compend Contin Educ Vet* 2009;31(1):14-21.

**WEIGHT**

37 kg

Lappin MR. The role of blood borne pathogens in feline fever of unknown origin. Proceedings from the American College of Veterinary Internal Medicine, Denver, CO, June 15-18, 2011.

**INTERPRETED BY**

Eric Lindquist, DMV

Lunn KF. Fever of unknown origin: a systematic approach to diagnosis. *Compend Contin Educ Vet* 2001;23(11):976-92.

DABVP, Cert. IVUSS

Lunn KF. Fever of unknown origin: appropriate choice of diagnostic tests. Proceedings from the American College of Veterinary Internal Medicine, Minneapolis, MN, June 9-12, 2004.

**IMAGING PERFORMED BY**

Dr. Belan

**HOSPITAL NAME**

Legacy Vet Clinic

**REFERRING VET**

Dr. Jajouei

**INVOICE**

37600

**DATE**

5/10/22