

**PATIENT**

Daisy Ruddell

**SPECIES**

Canine

**BREED**

Boxer

**SEX**

Spayed Female

**AGE**

7 Years

**WEIGHT**

63 Pounds

**INTERPRETED BY**

Eric Lindquist, DMV

DABVP, Cert. IUUSS

**IMAGING PERFORMED BY**

Sarah Pender, CVT

**HOSPITAL NAME**

SVS Imaging QC

**REFERRING VET**

Dr. Joe Westerhof

**INVOICE**

37597

**DATE**

5/10/22

**PRESENTING CLINICAL SIGNS**

Wakes up in morning hacking and coughing. Seeing occasional blood  
 Abnormal PE/Chem/CBC/UA Results: Rads: opacity seen between rib space 7-10 (RT) side of thorax; same opacity as heart on V/D; lateral: mass extends dorsal caudal from base of heart

**LIMITED ULTRASONOGRAPHIC EXAMINATION**

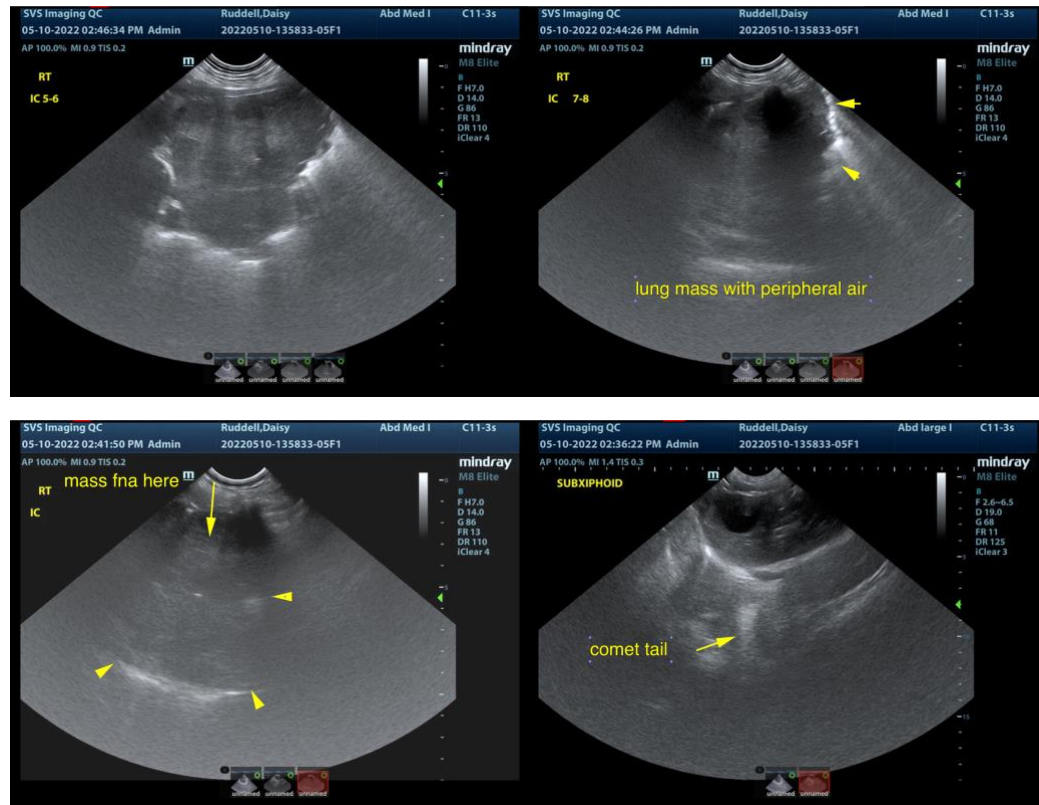
Variable intercostal views submitted with subjectively normal heart. The right auricle and heart base were unremarkable. However, the right intercostal view revealed a 10 cm undifferentiated, hypoechoic mass with peripheral air involvement, consistent with lung origin. Comet tail lung pattern also noted through the diaphragm, which would suggest for a multicentric process. Chest CT would be indicated. Ultrasound guided FNA indicated. Suspect lung sarcoma, possibility of carcinoma, mild potential for non-neoplastic necrosis.

**ULTRASONOGRAPHIC FINDINGS**

- Large lung mass – lung sarcoma likely.

**INTERPRETATION OF THE FINDINGS & FURTHER RECOMMENDATIONS**

CT evaluation for distribution assessment and abdominal sonogram recommended to assess for primary disease.





**PATIENT**

Daisy Ruddell

**SPECIES**

Canine

**BREED**

Boxer

**SEX**

Spayed Female

**AGE**

7 Years

**WEIGHT**

63 Pounds

**INTERPRETED BY**

Eric Lindquist, DMV

DABVP, Cert. IVUSS

**IMAGING PERFORMED BY**

Sarah Pender, CVT

**HOSPITAL NAME**

SVS Imaging QC

**REFERRING VET**

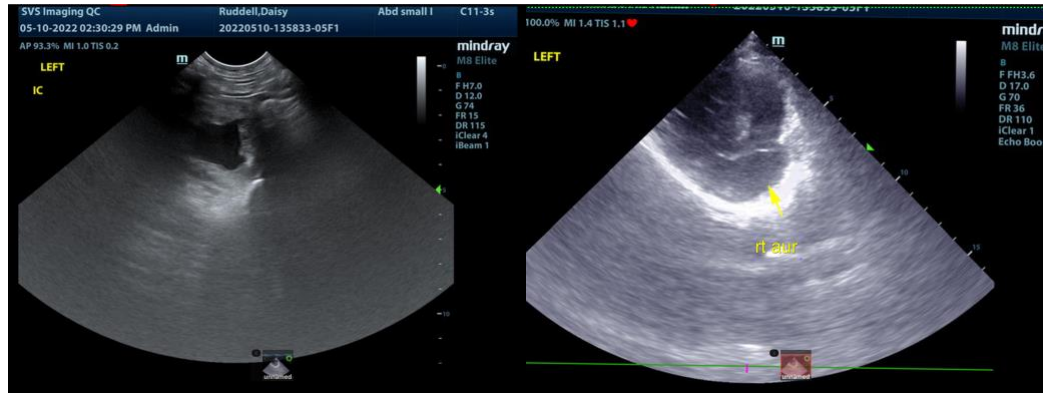
Dr. Joe Westerhof

**INVOICE**

37597

**DATE**

5/10/22



The information and recommendations provided are based on the images presented by the referring veterinarian/sonographer. No evaluation can be communicated regarding pathology that was not visible in the image/video clips provided.

Thank you for this referral. If the clinical or image interpretation does not parallel your findings or if I can be of any further assistance please contact me.

Eric Lindquist, DMV, DABVP, Cert. IVUSS, CEO of SonoPath.com

[info@SonoPath.com](mailto:info@SonoPath.com)