



PATIENT

Bors Borsberry

SPECIES

Canine

BREED

Labrador Retriever

SEX

Intact male

AGE

2020

WEIGHT

64 lbs

INTERPRETED BY

Eric Lindquist, DMV
DABVP, Cert. IVUSS

IMAGING PERFORMED BY

Amanda Lacey-Crook
SDEP Certified
Sonographer

HOSPITAL NAME

Rivers Edge Pet
Medical Center

REFERRING VET

Dr. Bernier

INVOICE

30221

DATE

5/10/22

PRESENTING CLINICAL SIGNS

For the past 2-3 days decreased eating, decreased activity, lethargic P was fine yesterday until the evening when became lethargic and weak in the rear end, today lethargic and not wanting to move alot, drinking but not interested in eating, is a field trial dog but has not been out for a bit. Only in the fenced back yard, may have eaten some moldy grass? Likes to jump off, often jumps off 3ft+ things Vomited 1x on Sunday (white foam) UTD on vxs per O (owner unsure if has had lepto vx)
Abnormal PE/Chem/CBC/UA Results: See attached lab work - RBC 9.99++++, HCT 61.8, HGB 23.2, Neu Band suspected, Mono 3.12, Eos 0.01 CHEM: Crea 2.0, BUN 59, Phos 9.2, TP 8.9, ALB 4.2, GLob 4.7, ALT 463, Na 134, Cl 100. See attached radiographs - abnormal GI pattern

ULTRASONOGRAPHIC EXAMINATION OF THE ABDOMEN

Urinary System

The **urinary bladder**, trigone, and pelvic urethra presented normal thicknesses and normal tone. The ureters were not visible which is normal. No uroliths or sediment were visualized and anechoic urine was present. No evidence of inflammatory or neoplastic changes was noted. Ureteral papillae were normal.

The prostate was normal and uniform measuring 2.7 cm.

The **kidneys** revealed normal size and structure, corticomedullary definition and ratio for this age. The cortices presented largely uniform texture with normal echogenic relationship to liver and spleen. Medullary structure differed distinctly from the cortex and no evidence of pelvic dilation was present. The capsules were acceptably uniform without significant irregularities. The left kidney measured 7.93 cm.

Adrenal Glands

Both **adrenal glands** were visualized and recognized as having normal shape, size, position and echogenicity for this breed. The phrenic vasculature, glandular echogenicity and detail were unremarkable. Capsule, cortex, and medullary definition were normal for this age patient. The left adrenal gland measured 3.13 x 0.71 cm at the cranial pole and 0.64 cm at the caudal pole. The right adrenal gland measured 2.84 x 1.38 cm at the cranial pole and 0.66 cm at the caudal pole.

Spleen

The **spleen** presented a smooth homogeneous parenchyma hyperechoic to liver and renal cortical parenchyma. The capsule was smooth without noticeable expansion or deviation from within the spleen or adjacent pathology. The splenic vasculature demonstrated normal volume without signs of congestion or thrombosis. No sonographic evidence of acute or chronic inflammatory, neoplastic, or infarctual changes was noted.

Liver

The **liver** images submitted revealed subjectively normal liver size, contour, and structure. Parenchymal echogenicity was naturally coarse and hypoechoic to the spleen. Vascular and biliary tracts were of normal volume with no evidence of congestion. The gallbladder presented acceptably thin walls with primarily anechoic content. The cystic and common bile ducts were normal. No pathological hepatic



PATIENT

lymphadenopathy was evident. No overt structural evidence of inflammatory, infiltrative or regenerative pathology was evident.

Bors Borsberry

SPECIES

Gastrointestinal

Canine

The visible upper gastrointestinal tract was empty. However, the cecum and colon appeared to be dilated with fluid. No overt foreign body or obstruction was noted.

BREED

Labrador Retriever

Pancreas

The base and limbs of the **pancreas** were observed to be largely isoechoic to surrounding omental fat. Pancreatic duct and capsular contour were acceptably normal and parenchyma respected normal curvilinear patterns. No overt evidence of active inflammatory or neoplastic disease was noted.

SEX

Intact male

AGE

2020

ULTRASONOGRAPHIC FINDINGS

Cecum and colon dilated with fluid, yet no overt evidence of foreign body or obstruction.

WEIGHT

64 lbs

INTERPRETATION OF THE FINDINGS & FURTHER RECOMMENDATIONS

I recommend IV fluid support, plasma expanders and treatment for enterotoxins/GI upset and a recheck sonogram in 12 hours after n.p.o. status.

INTERPRETED BY

Eric Lindquist, DMV
DABVP, Cert. IVUSS

IMAGING PERFORMED BY

Amanda Lacey-Crook
SDEP Certified
Sonographer

HOSPITAL NAME

Rivers Edge Pet
Medical Center

REFERRING VET

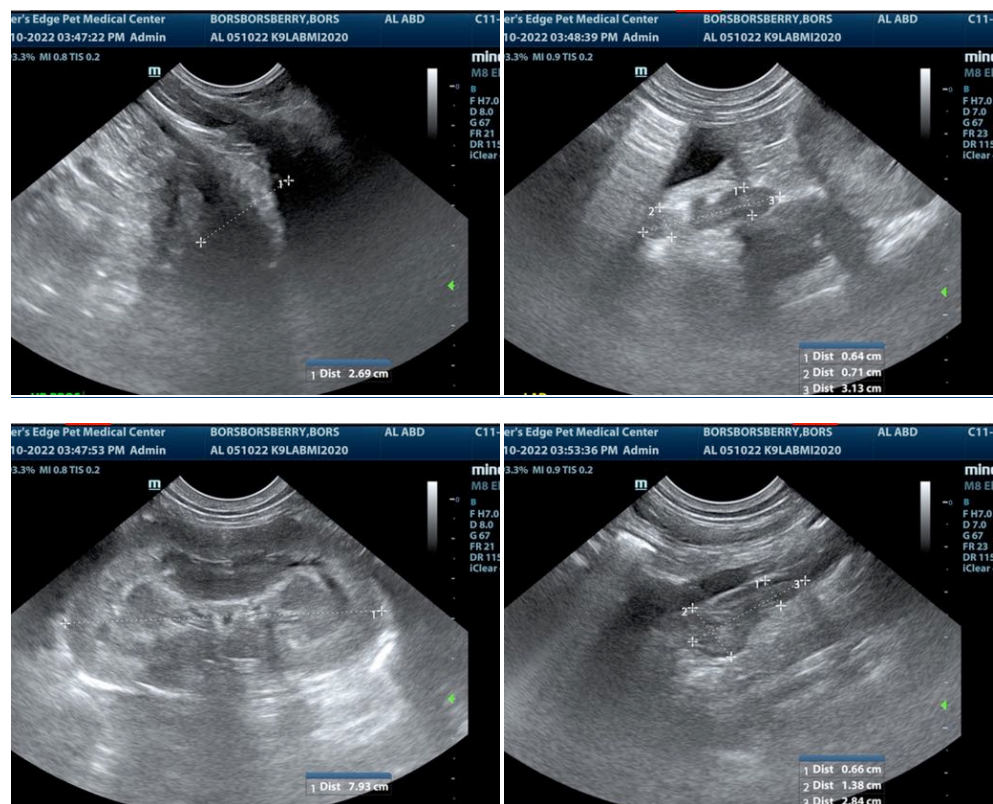
Dr. Bernier

INVOICE

30221

DATE

5/10/22





PATIENT

Bors Borsberry

SPECIES

Canine

BREED

Labrador Retriever

SEX

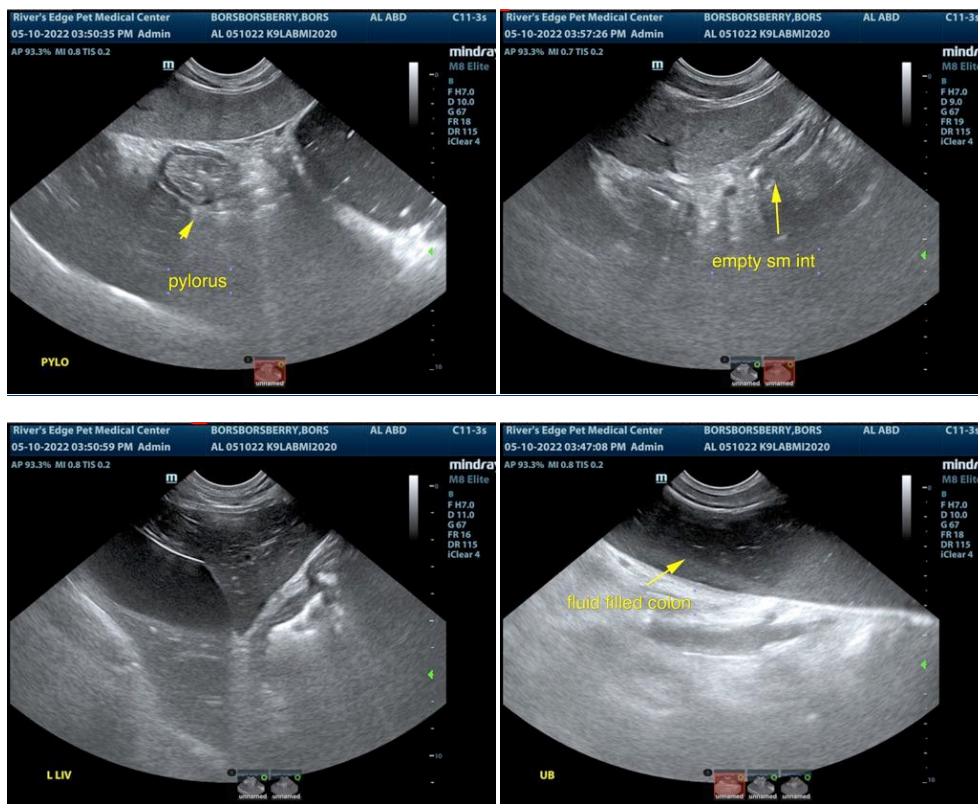
Intact male

AGE

2020

WEIGHT

64 lbs



INTERPRETED BY

Eric Lindquist, DMV
DABVP, Cert. IVUSS

IMAGING PERFORMED BY

Amanda Lacey-Crook
SDEP Certified
Sonographer

HOSPITAL NAME

Rivers Edge Pet
Medical Center

REFERRING VET

Dr. Bernier

INVOICE

30221

DATE

5/10/22

The information and recommendations provided are based on the images presented by the referring veterinarian/sonographer. No evaluation can be communicated regarding pathology that was not visible in the image/video clips provided.

Thank you for this referral. If the clinical or image interpretation does not parallel your findings or if I can be of any further assistance please contact me.

Eric Lindquist, DMV, DABVP, Cert. IVUSS, CEO of SonoPath.com
info@SonoPath.com