



## PATIENT

Scooby Lehmann

## SPECIES

Canine

## BREED

Beagle

## SEX

Neutered male

## AGE

9 years

## WEIGHT

34.5 lbs

## INTERPRETED BY

Eric Lindquist, DMV  
DABVP, Cert. IVUSS

## IMAGING PERFORMED BY

Arielle Roldan, CVT

## HOSPITAL NAME

Milford AH

## REFERRING VET

Dr. Ascione

## INVOICE

75124

## DATE

5/1/26

## PRESENTING CLINICAL SIGNS

History: Patient came in for initial wellness visit - bloodwork shows hypercalcemia and kidney changes, concerned about tumor/ neoplasia, recommended Abd U/S and owner elected to add in thyroid U/S since concerned about parathyroid involvement. Patient is obese.

## ULTRASONOGRAPHIC EXAMINATION OF THE ABDOMEN

### Urinary System

The **urinary bladder**, trigone, and pelvic urethra presented normal thicknesses and normal tone. The pelvic urethra was imaged 2.0 cm beyond the cystourethral junction and appeared normal. The ureters were not visible which is normal. No uroliths or sediment were visualized and anechoic urine was present. No evidence of inflammatory or neoplastic changes was noted. Ureteral papillae were normal.

The **kidneys** revealed largely normal size and structure, corticomedullary definition and ratio (cortex 1/3 of medulla) were essentially maintained with some age-related loss of curvilinear patterns regarding the capsule and C/M junction. The cortices presented largely uniform texture with some increased echogenicity expected for this age patient. Medullary structure differed distinctly from that of the cortex and no evidence of pelvic dilation was present. The left kidney measured 5.0 cm. The right kidney measured 5.6 cm.

### Adrenal Glands

The **adrenal glands** were not visualized.

### Spleen

The **spleen** was largely smooth with subtle heterogeneous parenchymal changes while maintaining normal echogenic relationship to the liver and kidney. These changes are consistent with normal age-related alteration. The capsule was smooth without noticeable impingement from within the spleen or from pathology in the adjacent abdomen. The splenic vasculature demonstrated normal volume without signs of congestion or significant contraction. No evidence of active acute or chronic inflammatory, neoplastic, or infarctual changes was noted.

### Liver

The **liver** images submitted revealed subjectively normal liver size, contour, and structure. Parenchymal echogenicity was naturally coarse and hypoechoic to the spleen. Vascular and biliary tracts were of normal volume with no evidence of congestion. The gallbladder presented acceptably thin walls with primarily anechoic content. The cystic and common bile ducts were normal. No pathological hepatic lymphadenopathy was evident. No overt structural evidence of inflammatory, infiltrative or regenerative pathology was evident.



## PATIENT

Scooby Lehmann

## SPECIES

Canine

## BREED

Beagle

## SEX

Neutered male

## AGE

9 years

## WEIGHT

34.5 lbs

## INTERPRETED BY

Eric Lindquist, DMV  
DABVP, Cert. IVUSS

## IMAGING PERFORMED BY

Arielle Roldan, CVT

## HOSPITAL NAME

Milford AH

## REFERRING VET

Dr. Ascione

## INVOICE

75124

## DATE

5/1/26

## Gastrointestinal

Examination of the **gastrointestinal tract** revealed a stomach and intestine free of stasis, of normal wall thickness, acceptable curvilinear mural detail, and peristaltic activity. Small and large intestine demonstrated normal luminal chyme and stool consistency respectively. No obstructive or overt infiltrative disease was noted. No associated abnormal lymphatic activity was noted.

## Pancreas

The base and limbs of the **pancreas** were observed to be largely isoechoic to surrounding omental fat. Pancreatic duct and capsular contour were acceptably normal and parenchyma respected normal curvilinear patterns. No overt evidence of active inflammatory or neoplastic disease was noted.

## Thyroids

The thyroid regions were imaged. The esophagus, trachea and regional tissues were unremarkable. The visible thyroid tissue was unremarkable. There was no gross evidence of parathyroid adenoma, yet I cannot rule this out. There was no evidence of masses.

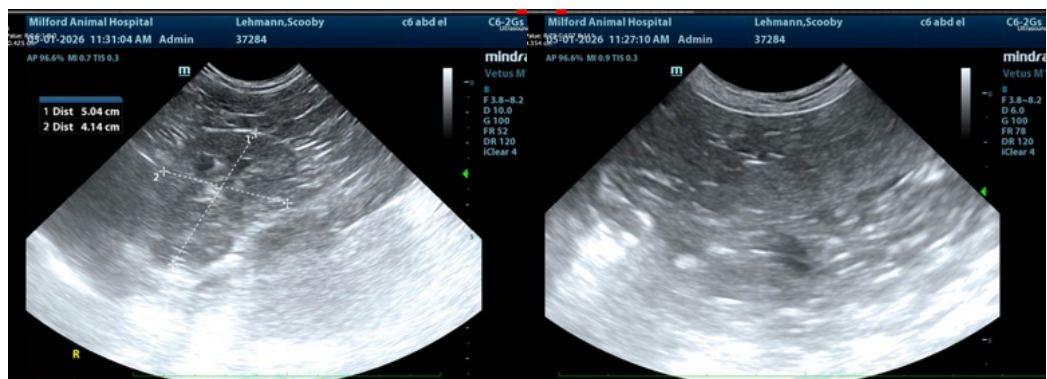
## ULTRASONOGRAPHIC FINDINGS

Age related abdominal changes.

Regions of thyroids were unremarkable.

## INTERPRETATION OF THE FINDINGS & FURTHER RECOMMENDATIONS

Sedation and further imaging may be necessary for best results.





## PATIENT

Scooby Lehmann

## SPECIES

Canine

## BREED

Beagle

## SEX

Neutered male

## AGE

9 years

## WEIGHT

34.5 lbs

## INTERPRETED BY

Eric Lindquist, DMV  
DABVP, Cert. IVUSS

## IMAGING PERFORMED BY

Arielle Roldan, CVT

## HOSPITAL NAME

Milford AH

## REFERRING VET

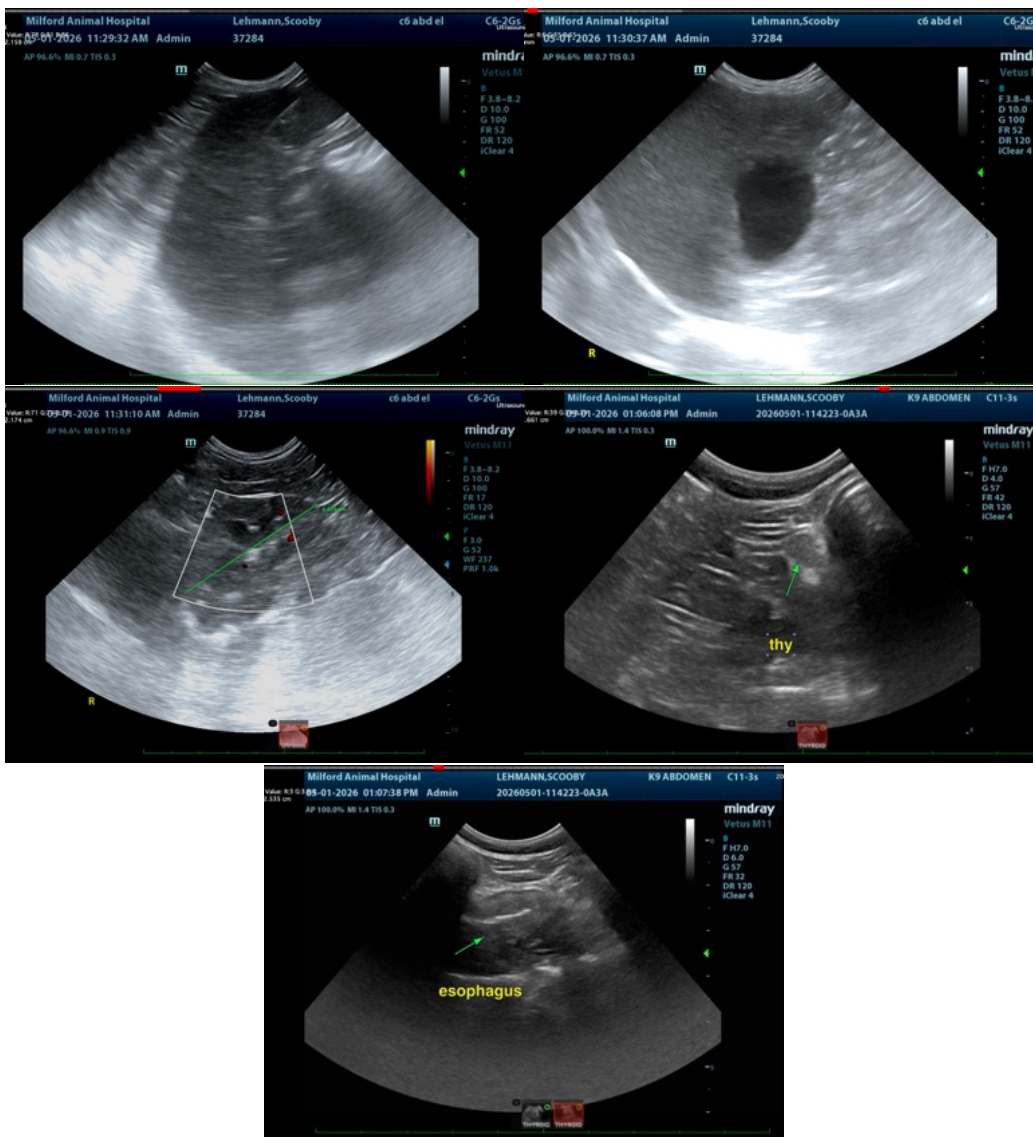
Dr. Ascione

## INVOICE

75124

## DATE

5/1/26



The information and recommendations provided are based on the images presented by the referring veterinarian/sonographer. No evaluation can be communicated regarding pathology that was not visible in the image/video clips provided.

Thank you for this referral. If the clinical or image interpretation does not parallel your findings or if I can be of any further assistance please contact me.

Eric Lindquist, DMV, DABVP (CFM), Cert. IVUSS, CEO of SonoPath.com

[info@SonoPath.com](mailto:info@SonoPath.com)



## PATIENT

Scooby Lehmann

## SPECIES

Canine

## BREED

Beagle

## SEX

Neutered male

## AGE

9 years

## WEIGHT

34.5 lbs

## INTERPRETED BY

Eric Lindquist, DMV  
DABVP, Cert. IVUSS

## IMAGING PERFORMED BY

Arielle Roldan, CVT

## HOSPITAL NAME

Milford AH

## REFERRING VET

Dr. Ascione

## INVOICE

75124

## DATE

5/1/26

## CANINE HYPERCALCEMIA

<http://www.sonopath.com/CanineHypercalcemia>

**Description:** Hypercalcemia is defined as either a persistently elevated total calcium serum (> 12 mg/dl) or ionized calcium (> 1.45 mmol/l) concentration. Clinical signs are often absent with mild hypercalcemia (< 13 mg/dl). In fact, hypercalcemia is often only discovered when serum biochemistry is done for unrelated reasons. Clinical signs are usually mild when the serum calcium concentration is less than 14 mg/dl; however, signs become more readily apparent when the concentration exceeds 15 mg/dl. Life-threatening cardiac arrhythmias can develop when the serum calcium exceeds 18 mg/dl.

Common etiologies of hypercalcemia include humoral hypercalcemia of malignancy (HHM), hypoadrenocorticism, chronic kidney disease (CKD), hypervitaminosis D, and primary hyperparathyroidism. Less common etiologies include bone neoplasia, osteomyelitis, hypertrophic osteodystrophy, granulomatous disease, calcium supplementation, and oral phosphate binders.

**Clinical Signs:** Common clinical signs include polyuria, polydipsia, lethargy, inappetence, and weakness. With chronic hypercalcemia, calcium oxalate and calcium phosphate uroliths can form, resulting in clinical signs suggestive of lower urinary tract disease. Systemic signs of illness are suggestive of HHM.

**Diagnostics:** One important etiology of hypercalcemia is laboratory error; therefore, hypercalcemia should always be confirmed before embarking on any further diagnostic evaluation. Results of a CBC, serum biochemistry panel, and urinalysis, in conjunction with a patient history and findings from a physical examination, can often provide enough information to arrive at a diagnosis. The appendicular skeleton, peripheral lymph nodes, abdominal cavity, and rectum should all be carefully palpated for masses, lymphadenopathy, hepatomegaly, splenomegaly, and/or pain in the long bones. The following diagnostic tests are helpful for identifying an underlying malignancy: thoracic and abdominal radiographs; abdominal ultrasound; cytological evaluation of aspirates of the liver, spleen, lymph nodes, and bone marrow; determination of serum ionized calcium, parathyroid hormone (PTH), and parathyroid hormone-related protein concentration (PTHrP); and ultrasound of the neck. Ascertaining the concentrations of serum ionized calcium, PTH, and PTHrP helps differentiate primary hyperparathyroidism from HHM. The finding of one or more enlarged parathyroid glands upon conducting an ultrasound of the neck supports a diagnosis of primary hyperparathyroidism.

Hypoadrenocorticism-induced hypercalcemia usually occurs in conjunction with hyponatremia, hyperkalemia, and prerenal azotemia. With HHM and primary hyperparathyroidism, serum phosphorus concentration is often in the low to low-normal reference range. If the serum phosphorus concentration is high but kidney function is normal, hypervitaminosis D or osteolysis should be suspected.



## PATIENT

Scooby Lehmann

## SPECIES

Canine

## BREED

Beagle

## SEX

Neutered male

## AGE

9 years

## WEIGHT

34.5 lbs

It can be difficult to determine whether kidney failure is primary or secondary to hypercalcemia when hyperphosphatemia and hypercalcemia coexist with azotemia. Serum ionized calcium concentrations are typically normal or decreased in cases of renal failure and increased in cases of hypercalcemia caused by other disorders.

Sternal and hilar lymphadenopathy is common with lymphoma-induced hypercalcemia and can be readily identified on thoracic radiographs. In cases of multiple myeloma, discrete lytic lesions in the vertebrae or long bones, hyperproteinemia, proteinuria, and plasma cell infiltration in the bone marrow may be present. Cytological evaluation of the peripheral lymph nodes, bone marrow, and spleen can be helpful in identifying lymphoma.

Increased serum ionized calcium concentrations, detectable serum PTHrP concentrations, and non-detectable serum PTH concentrations are all diagnostic for HHM. Lymphoma is the most common etiology of HHM, but other tumors, such as apocrine gland adenocarcinoma and various carcinomas (e.g. mammary gland, squamous cell, bronchogenic), can all give rise to hypercalcemia. Increased serum ionized calcium, normal to increased serum PTH, and non-detectable PTHrP concentrations are diagnostic of primary hyperparathyroidism.

## INTERPRETED BY

Eric Lindquist, DMV  
DABVP, Cert. IVUSS

## Differentials for Hypercalcemia: "HARD IONS"

Hyperparathyroid

Addison's

Renal

D-toxicity

Idiopathic

Osteolytic

Neoplastic

Spurious

## IMAGING PERFORMED BY

Arielle Roldan, CVT

## HOSPITAL NAME

Milford AH

## REFERRING VET

Dr. Ascione

## INVOICE

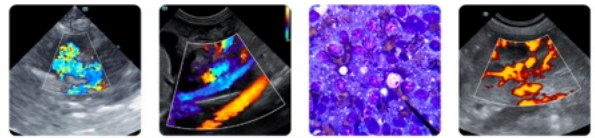
75124

## DATE

5/1/26

**PTH tumor:** Elevated total and ionized Ca, low PTHrP, and normal/high PTH. Keeshonds, German Shepherds, and Golden Retrievers are all predisposed.

**Addison's disease:** Elevated total and normal ionized Ca, elevated BUN, hypoalbuminemia and hyperkalemia.



## PATIENT

Scooby Lehmann

## SPECIES

Canine

## BREED

Beagle

## SEX

Neutered male

## AGE

9 years

## WEIGHT

34.5 lbs

## INTERPRETED BY

Eric Lindquist, DMV  
DABVP, Cert. IVUSS

## IMAGING PERFORMED BY

Arielle Roldan, CVT

## HOSPITAL NAME

Milford AH

## REFERRING VET

Dr. Ascione

## INVOICE

75124

## DATE

5/1/26

**Renal failure:** Elevated to normal total Ca, low ionized Ca, low PTHrP, elevated PTH, azotemia, and low urine specific gravity.

**Vitamin D toxicity:** Elevated total and ionized Ca, low PTHrP, and normal/low PTH.

**Hypercalcemia of malignancy (HHM):** Elevated total and ionized Ca, high PTHrP, and low PTH.

**Granulomatous disease:** Elevated total and ionized Ca, low PTHrP, and low PTH.

**Renal failure:** Elevated to normal total Ca, low ionized Ca, low PTHrP, elevated PTH, azotemia, and low urine specific gravity.

**Treatment:** Therapies for hypercalcemia are aimed at correcting the underlying etiology; however, because prolonged hypercalcemia can result in kidney damage, the use of fluid therapy, furosemide, and possibly prednisone is indicated in all cases to reduce serum calcium levels. Suggested dosages include saline (0.9% 120-180 ml/kg day IV), furosemide (1-4 mg/kg PO TID), and prednisone (0.25 mg/kg PO Q24hr).

## References:

Chew DJ, Schenck PA, Jaeger JQ. Clinical disorders of hypercalcemia and hypocalcemia in dogs and cats. Proceedings from the American College of Veterinary Internal Medicine, Charlotte, NC, June 4-7, 2003.

Feldman EC. Disorders of the parathyroid glands. In: Ettinger SJ, Feldman EC, ed. *Textbook of Veterinary Internal Medicine, 7th ed.* St. Louis, MO: Saunders Elsevier; 2010:1722-50.

Peterson ME. Hypercalcemia in dogs & cats: differential diagnosis & treatment. Proceedings from the Western Veterinary Conference, Las Vegas, NV, February 19-23, 2012.