



PATIENT

Robot Waldenburg

SPECIES

Feline

BREED

DSH

SEX

Neutered Male

AGE

15 Years 5 Months

WEIGHT

12.8 lbs

INTERPRETED BY

Eric Lindquist, DMV,
DABVP(CFM), Cert.
IVUSS

IMAGING PERFORMED BY

Kerri Becker

HOSPITAL NAME

Packanack Animal
Hospital

REFERRING VET

Dr. Gonzaga

INVOICE

15630

DATE

05/01/26

PRESENTING CLINICAL SIGNS

3-4 d acute lethargy, recent vomiting, recent a/g infection, mm pale pk, grade 3-4/6 hm, decr. bms, healing wound L perianal area

Abnormal PE/Chem/CBC/UA Results: hct-24.1 rbc-6.0 hemaglob-8.7 neut-14.27 glob-5.6

ULTRASONOGRAPHIC EXAMINATION OF THE ABDOMEN

Urinary System

The **urinary bladder**, trigone, and pelvic urethra presented normal thicknesses and normal tone. The ureters were not visible which is normal. No uroliths or sediment were visualized, and anechoic urine was present. No evidence of inflammatory or neoplastic changes were noted. Ureteral papillae were normal.

The **kidneys** revealed largely normal size and structure, corticomedullary definition and ratio (cortex 1/3 of medulla) were essentially maintained with some mild age-related loss of curvilinear patterns regarding the capsule and C/M junction. The cortices presented largely uniform texture with some increased echogenicity expected for his age patient. Medullary structure differed distinctly from that of the cortex and no evidence of pelvic dilation was present. The left kidney measured 3.04 cm in length. The right kidney measured 4.28 cm in length.

Adrenal Glands

Both **adrenal glands** were visualized and recognized as having normal shape, size, position and echogenicity for this breed. The phrenic vasculature, glandular echogenicity and detail were unremarkable. Capsule, cortex, and medullary definition were normal for this age patient. The left adrenal gland measured 0.36 cm width. The right adrenal gland measured 0.42 cm width.

Spleen

The **spleen** presented a smooth homogeneous parenchyma hyperechoic to liver and renal cortical parenchyma. The capsule was smooth without noticeable expansion or deviation from within the spleen or adjacent pathology. The splenic vasculature demonstrated normal volume without signs of congestion or thrombosis. No sonographic evidence of acute or chronic inflammatory, neoplastic, or infarctual changes were noted.

Liver

The **liver** images from right and left intercostal as well as subcostal views revealed subjectively normal liver size, contour, and structure. Some mild age-related parenchymal remodeling was noted but likely not clinically significant at this time. Vascular and biliary tracts were of normal volume and no evidence of congestion was noted. The gallbladder presented some dependent debris with essentially normal contour. The cystic and common bile ducts were normal. No overt evidence of active inflammatory, infiltrative or regenerative pathology was noted but should be paired with current or past LE elevations regarding any clinical significance to this presentation. The hepatic lymph nodes were unremarkable.

Gastrointestinal



PATIENT

Robot Waldenburg

SPECIES

Feline

BREED

DSH

SEX

Neutered Male

AGE

15 Years 5 Months

WEIGHT

12.8 lbs

INTERPRETED BY

Eric Lindquist, DMV,
DABVP(CFM), Cert.
IVUSS

IMAGING PERFORMED BY

Kerri Becker

HOSPITAL NAME

Packanack Animal
Hospital

REFERRING VET

Dr. Gonzaga

INVOICE

15630

DATE

05/01/26

The **stomach** in this patient presented normal structure, yet progressively shadowing material that is consistent with hairball density or similar. Foreign matter cannot be ruled out. However, the pattern is most consistent with hairball. The small and large intestine were unremarkable but given that hairball issues in cats is often associated with underlying GI disease then this should be considered in the medical or surgical management. The remainder of the gastrointestinal tract was unremarkable.

Pancreas

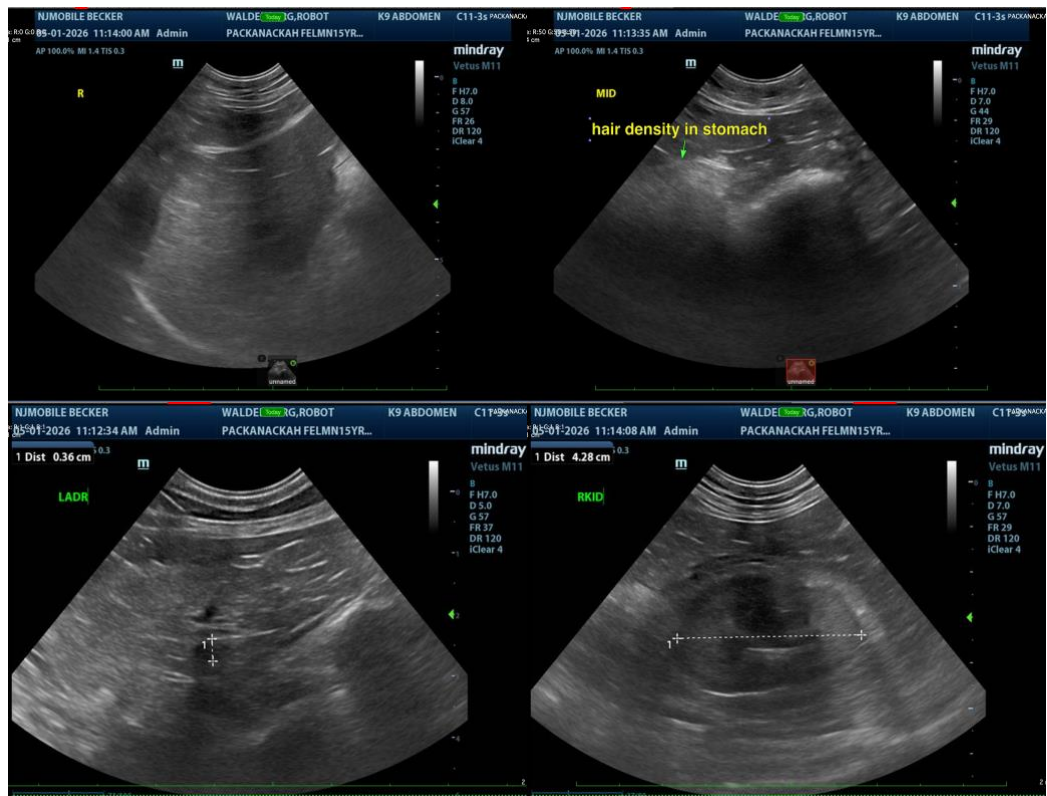
The base and limbs of the **pancreas** were observed to be largely isoechoic to surrounding omental fat. Pancreatic duct and capsular contour were acceptably normal and parenchyma respected normal curvilinear patterns. No overt evidence of active inflammatory or neoplastic disease was noted.

ULTRASONOGRAPHIC FINDINGS

- Structurally unremarkable geriatric abdomen.
- Hairball density in the stomach.

INTERPRETATION OF THE FINDINGS & FURTHER RECOMMENDATIONS

No evidence of gross pathology. Hairball management is warranted. The cause of the anemia is unclear. CBC path review +/- bone marrow aspirate may be appropriate.





PATIENT

Robot Waldenburg

SPECIES

Feline

BREED

DSH

SEX

Neutered Male

AGE

15 Years 5 Months

WEIGHT

12.8 lbs

INTERPRETED BY

Eric Lindquist, DMV,
DABVP(CFM), Cert.
IVUSS

IMAGING PERFORMED BY

Kerri Becker

HOSPITAL NAME

Packanack Animal
Hospital

REFERRING VET

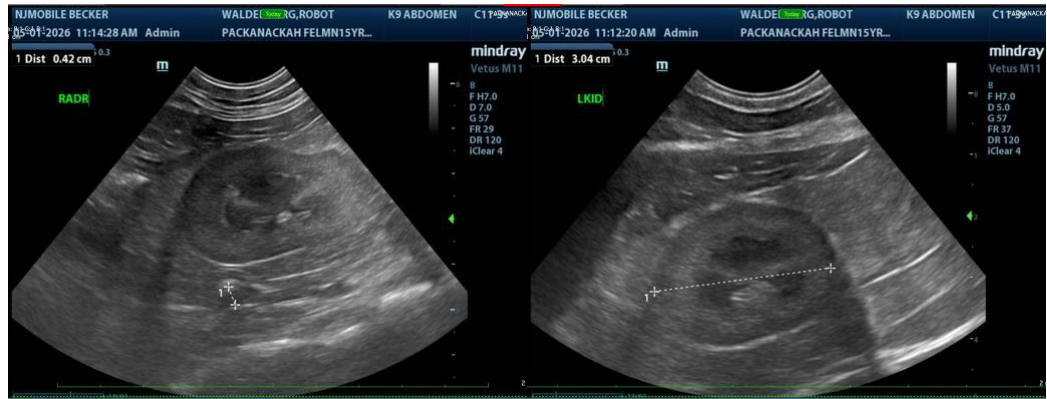
Dr. Gonzaga

INVOICE

15630

DATE

05/01/26



The information and recommendations provided are based on the images presented by the referring veterinarian/sonographer. No evaluation can be communicated regarding pathology that was not visible in the image/video clips provided.

Thank you for this referral. If the clinical or image interpretation does not parallel your findings or if I can be of any further assistance, please contact me.

Eric Lindquist, DMV, DABVP(CFM), Cert. IVUSS,

CEO, Owner, Founder -- SonoPath.com

info@SonoPath.com