



PATIENT

Maya Yurasits

SPECIES

Canine

BREED

Mix

SEX

Spayed Female

AGE

9 Years 1 Month

WEIGHT

112 lbs

INTERPRETED BY

Eric Lindquist, DMV,
DABVP(CFM), Cert.
IVUSS

IMAGING PERFORMED BY

Chloe Lowe CVT

HOSPITAL NAME

Black River Veterinary
Hospital

REFERRING VET

Dr. Hewitt

INVOICE

15664

DATE

05/01/26

PRESENTING CLINICAL SIGNS

Increasing ALT and Alk phos. Pelvic limbs arthritic changes, obesity. Gabapentin 300mgs BID.

Abnormal PE/Chem/CBC/UA Results: ALT 332, Alk phos 676

ULTRASONOGRAPHIC EXAMINATION OF THE ABDOMEN

Urinary System

The **urinary bladder**, trigone, and pelvic urethra to a depth of 1.0 cm presented normal thicknesses and normal tone. The ureters were not visible which is normal. No uroliths or sediment were visualized, and anechoic urine was present. No evidence of inflammatory or neoplastic changes were noted. Ureteral papillae were normal.

The **kidneys** revealed normal size and structure, corticomedullary definition and ratio for this age. The cortices presented largely uniform texture with normal echogenic relationship to liver and spleen. Medullary structure differed distinctly from the cortex and no evidence of pelvic dilation was present. The capsules were acceptably uniform without significant irregularities. The left kidney measured 7.62 cm in length. The right kidney measured 7.57 cm in length.

Adrenal Glands

Both **adrenal glands** were visualized and recognized as having normal shape, size, position and echogenicity for this breed. The phrenic vasculature, glandular echogenicity and detail were unremarkable. Capsule, cortex, and medullary definition were normal for this age patient. The left adrenal gland measured 2.7 cm x 0.57 cm width at the cranial pole and 0.64 cm width at the caudal pole. The right adrenal gland measured 2.63 cm x 1.35 cm width at the cranial pole and 0.80 cm width at the caudal pole.

Spleen

The **spleen** presented enlarged and folded upon itself cranially with uniform parenchyma.

Liver

The **liver** images from right and left intercostal as well as subcostal views revealed subjectively normal liver size, contour, and structure. Some mild age-related parenchymal remodeling was noted but likely not clinically significant at this time. Mild increased portal markings were noted. The gallbladder presented some dependent debris with essentially normal contour. The cystic and common bile ducts were normal. No overt evidence of active inflammatory, infiltrative or regenerative pathology was noted but should be paired with current or past LE elevations regarding any clinical significance to this presentation. The hepatic lymph nodes were unremarkable.

Gastrointestinal

Examination of the **gastrointestinal tract** revealed a stomach and intestine free of stasis, of normal wall thickness, acceptable curvilinear mural detail, and peristaltic activity. Small and large intestine demonstrated normal luminal chyme and stool consistency respectively. No obstructive or overt infiltrative disease was noted. No associated abnormal lymphatic activity was noted.

Pancreas



PATIENT

Maya Yurasits

SPECIES

Canine

BREED

Mix

SEX

Spayed Female

AGE

9 Years 1 Month

WEIGHT

112 lbs

INTERPRETED BY

Eric Lindquist, DMV,
 DABVP(CFM), Cert.
 IVUSS

IMAGING PERFORMED BY

Chloe Lowe CVT

HOSPITAL NAME

Black River Veterinary
 Hospital

REFERRING VET

Dr. Hewitt

INVOICE

15664

DATE

05/01/26

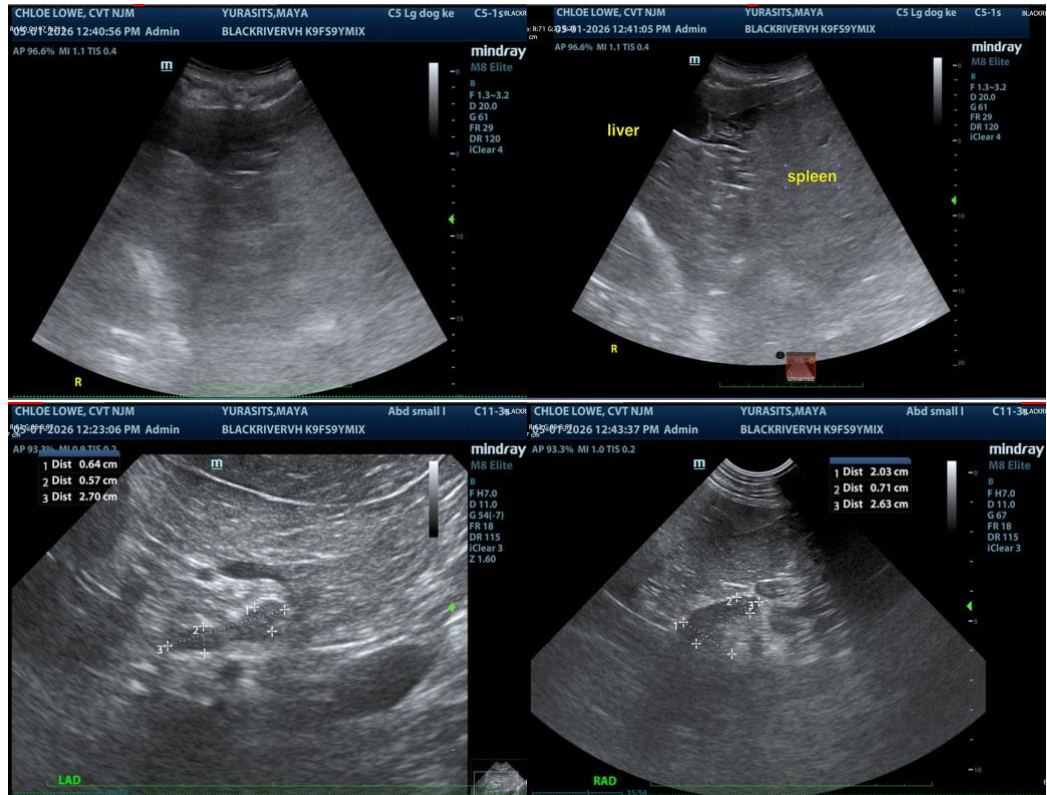
The base and limbs of the **pancreas** were observed to be largely isoechoic to surrounding omental fat. Pancreatic duct and capsular contour were acceptably normal and parenchyma respected normal curvilinear patterns. No overt evidence of active inflammatory or neoplastic disease was noted.

ULTRASONOGRAPHIC FINDINGS

- Mild hepatic nonspecific remodeling- low-grade inflammatory of unknown cause.
- Geriatric abdomen otherwise.

INTERPRETATION OF THE FINDINGS & FURTHER RECOMMENDATIONS

No evidence of significant disease. Even though abdominal tension was present, there's no evidence of visceral disease that would be causing any pain in this patient.





PATIENT

Maya Yurasits

SPECIES

Canine

BREED

Mix

SEX

Spayed Female

AGE

9 Years 1 Month

WEIGHT

112 lbs

INTERPRETED BY

Eric Lindquist, DMV,
 DABVP(CFM), Cert.
 IVUSS

IMAGING PERFORMED BY

Chloe Lowe CVT

HOSPITAL NAME

Black River Veterinary
 Hospital

REFERRING VET

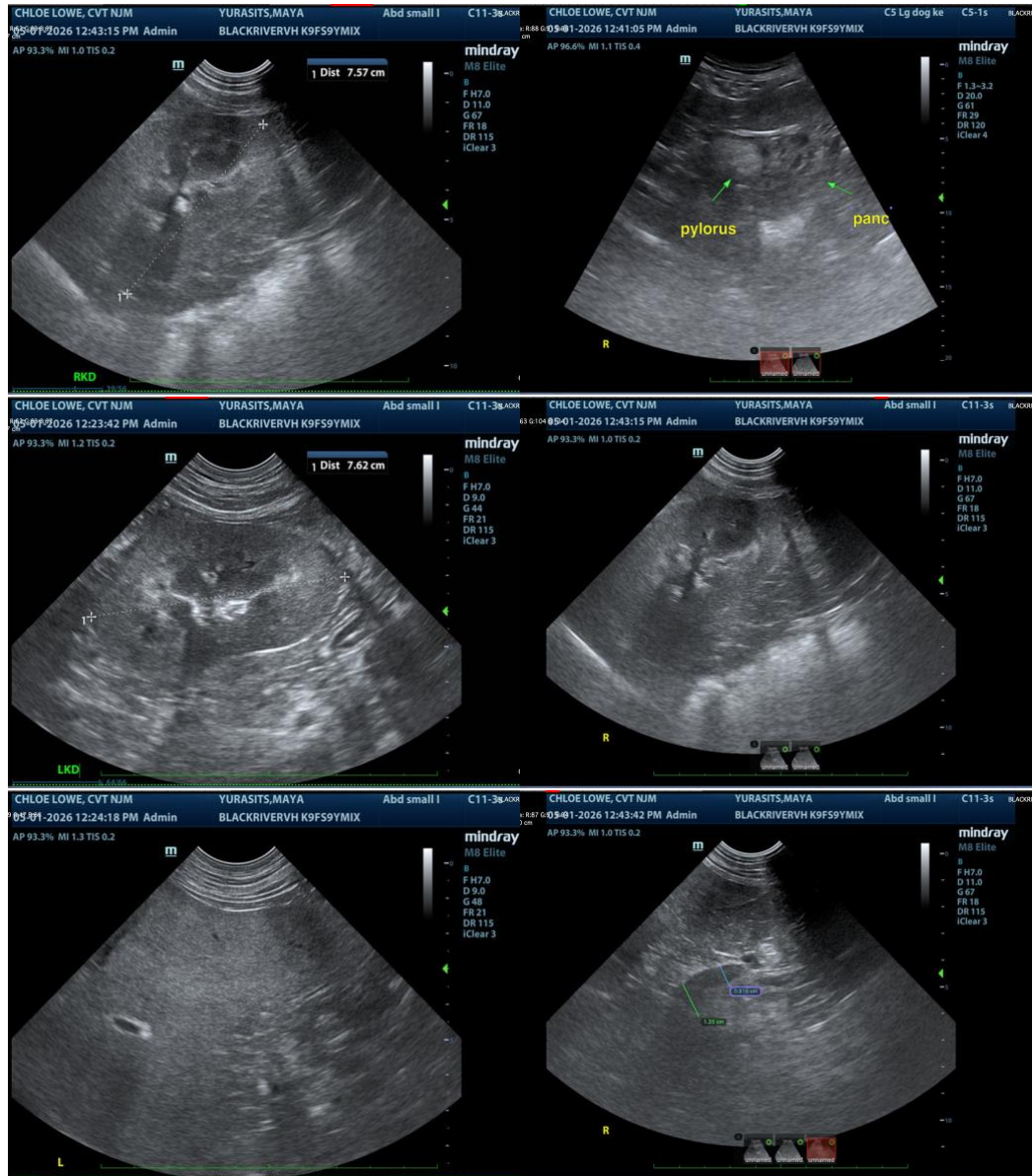
Dr. Hewitt

INVOICE

15664

DATE

05/01/26





PATIENT

Maya Yurasits

SPECIES

Canine

BREED

Mix

SEX

Spayed Female

AGE

9 Years 1 Month

WEIGHT

112 lbs

INTERPRETED BY

Eric Lindquist, DMV,
DABVP(CFM), Cert.
IVUSS

IMAGING PERFORMED BY

Chloe Lowe CVT

HOSPITAL NAME

Black River Veterinary
Hospital

REFERRING VET

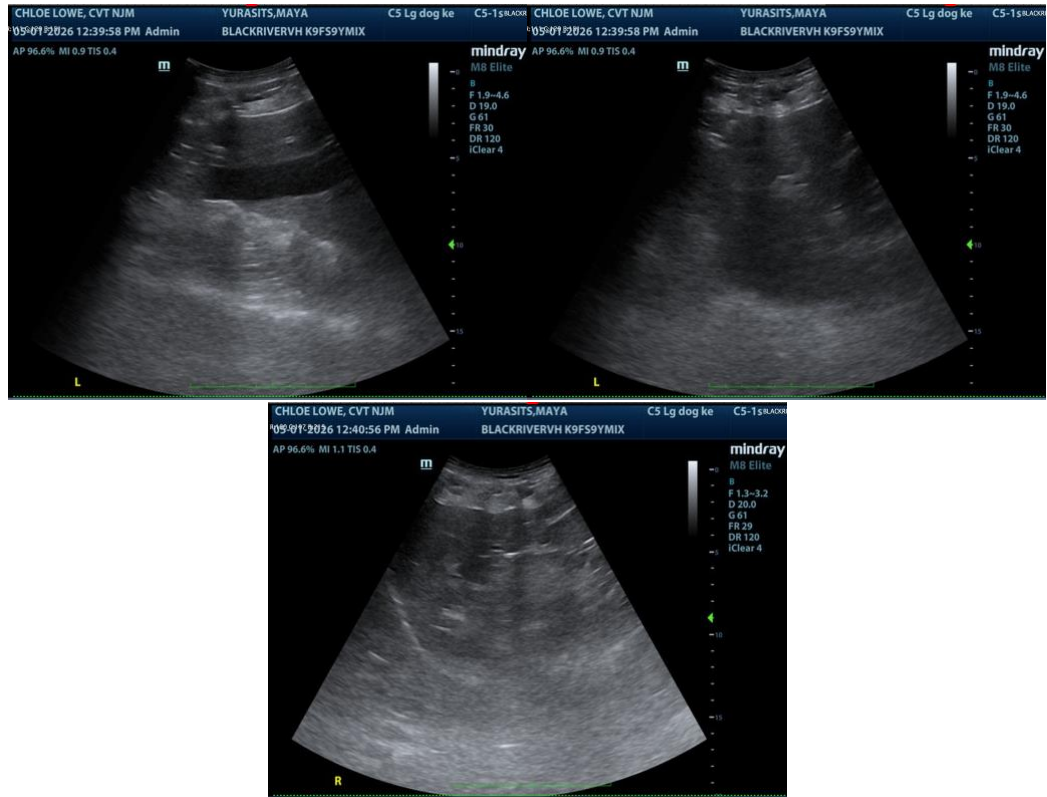
Dr. Hewitt

INVOICE

15664

DATE

05/01/26



The information and recommendations provided are based on the images presented by the referring veterinarian/sonographer. No evaluation can be communicated regarding pathology that was not visible in the image/video clips provided.

Thank you for this referral. If the clinical or image interpretation does not parallel your findings or if I can be of any further assistance, please contact me.

Eric Lindquist, DMV, DABVP(CFM), Cert. IVUSS,

CEO, Owner, Founder -- SonoPath.com

info@SonoPath.com