

**DATE PRESENTING CLINICAL SIGNS**

5/1/23 History: 3/22/23- exam for chronic diarrhea of sporadic nature but recently increasing in frequency.

PATIENT

Thunder Stein

Current Medications: None.

Lab Results: 3/14/23 Fecal parasite exam- Neg. 3/22/23 Superchem/CBC/T4: Prec PSL 204.

Date of Previous IntraPet Ultrasound: No previous.

Sedation: Not required to complete full diagnostic ultrasound.

SPECIES

Canine

Stat Report: Not requested.

Imaging Performed By: Stephanie Warga RDCS, RVT.

BREED

Rottweiler

ULTRASONOGRAPHIC EXAMINATION OF THE ABDOMEN**SEX**

Neuterd Male

Urinary System

The **urinary bladder**, trigone, and pelvic urethra presented normal thicknesses and normal tone. The ureters were not visible which is normal. No uroliths or sediment were visualized and anechoic urine was present. No evidence of inflammatory or neoplastic changes were noted. Ureteral papillae were normal. The pelvic urethra was imaged 2.0 cm beyond the cystourethral junction.

AGE

10/31/15

The **kidneys** revealed normal size and structure, corticomedullary definition and ratio for this age. The cortices presented largely uniform texture with normal echogenic relationship to liver and spleen. Medullary structure differed distinctly from the cortex and no evidence of pelvic dilation was present. The capsules were acceptably uniform without significant irregularities. The right kidney measured 7.3 cm. Occasional cortical cysts were noted in the kidneys. The left kidney measured 7.87 cm.

WEIGHT

130 Pounds

Adrenal Glands

Both **adrenal glands** were visualized and recognized as having normal shape, size, position and echogenicity for this breed. The phrenic vasculature, glandular echogenicity and detail were unremarkable. Capsule, cortex, and medullary definition were normal for this age patient. The right adrenal gland measured 3.7 cm x 0.58 cm at the caudal pole and 0.51 cm at the cranial pole. The left adrenal gland measured 3.97 cm x 0.72 cm at the caudal pole and 0.76 cm at the cranial pole.

INTERPRETED BYEric Lindquist, DMV
DABVP, Cert. IVUSS**Spleen**

The **spleen** was folded upon itself and revealed hypoechoic nodular changes, measuring up to 2.5 cm at the splenic fold. Minor heterogenous changes were noted elsewhere in the spleen with slight free fluid. A separate splenic mass was noted in the caudal body, measuring 5.0 cm.

HOSPITAL NAME

Alexander AH

Liver

The **liver** revealed mild increased portal markings. The liver parenchyma was hypoechoic. The gallbladder and common bile were unremarkable.

REFERRING VET

Dr. Alexander

INVOICE

22283

Gastrointestinal

The **stomach** and upper small intestine were unremarkable. The small intestine revealed a mass, measuring approximately 4.0 cm with loss of structural detail. The mass was ileocecal with regional inflammation and extended for approximately 8.0 cm with infiltrative pattern.

Pancreas

The base and limbs of the **pancreas** were observed to be largely isoechoic to surrounding omental fat. Pancreatic duct and capsular contour were acceptably normal and parenchyma respected normal curvilinear patterns. No overt evidence of active inflammatory or neoplastic disease was noted.

Other

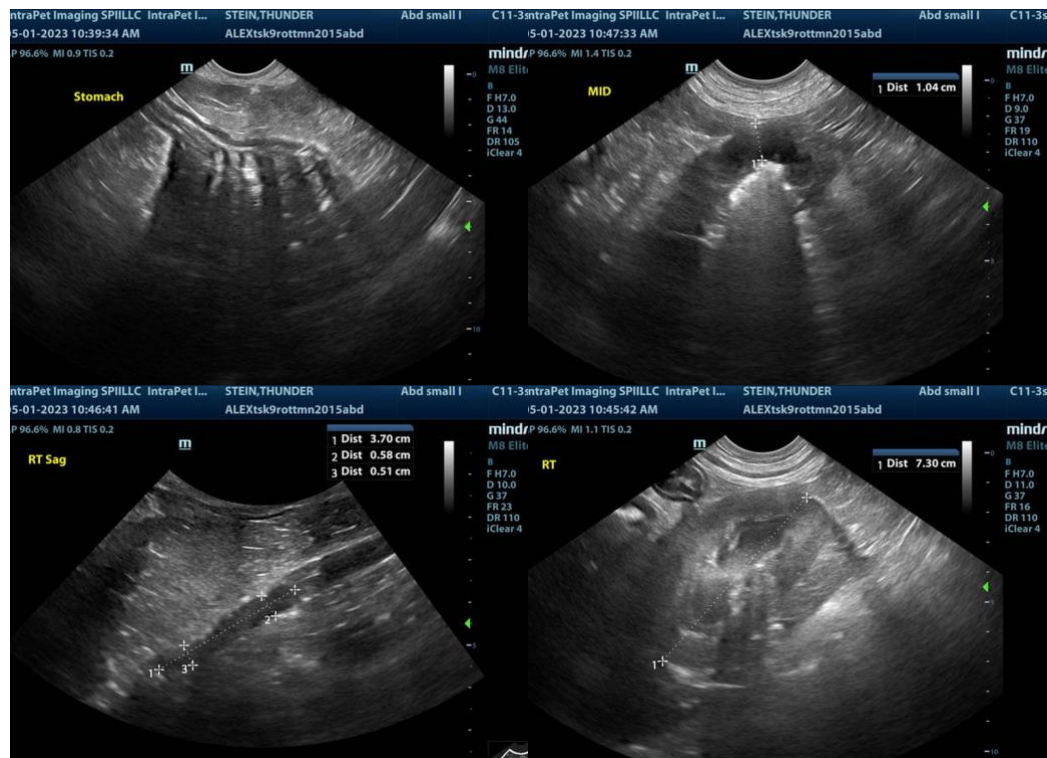
A rapid view of the heart revealed no evident pathology in the right auricle or pericardium.

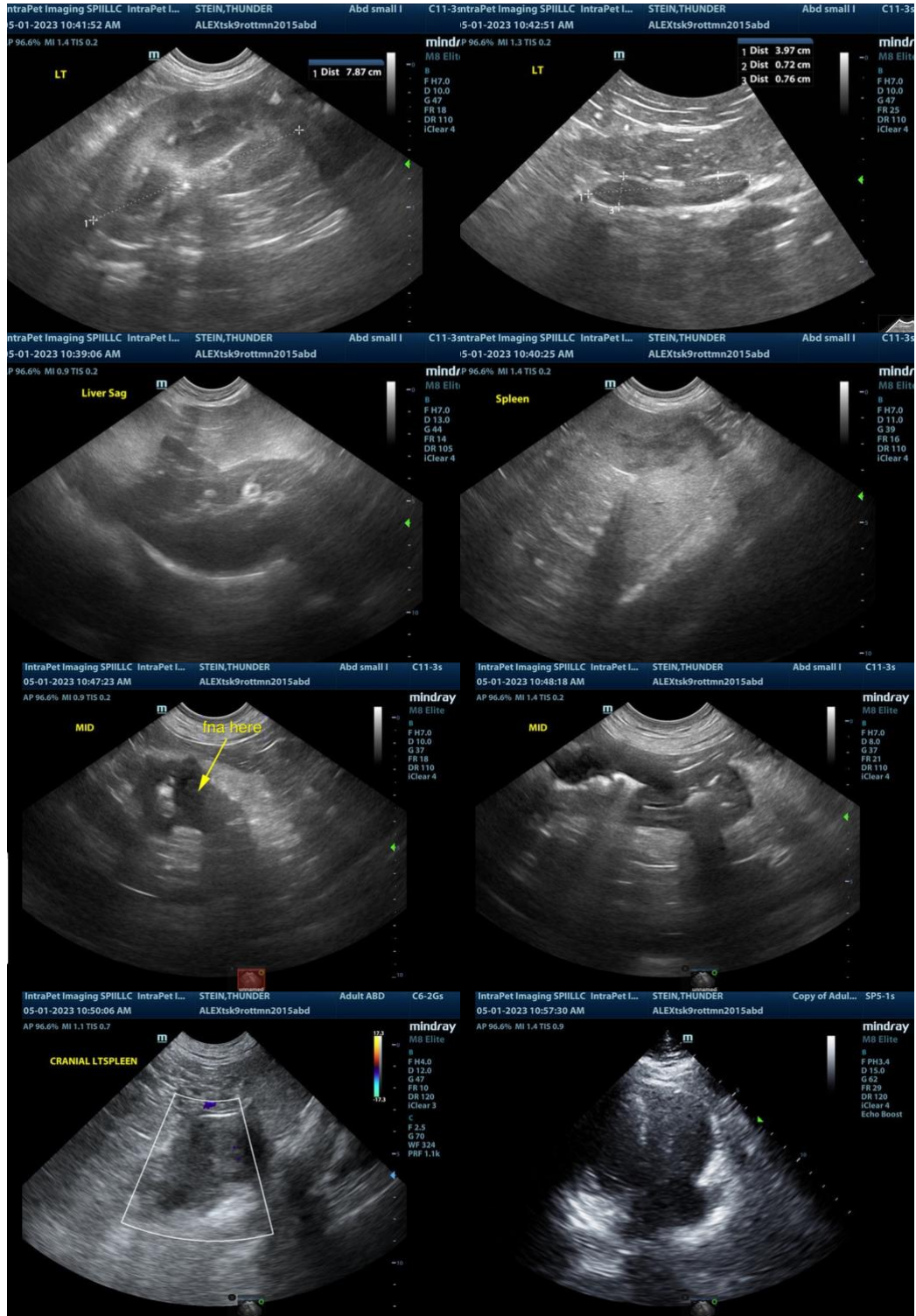
ULTRASONOGRAPHIC FINDINGS

- Ileocecal mass- round cell neoplasia, carcinoma is likely. Granulomatous disease is less likely. Regional inflammation was noted.
- Splenic mass and nodular changes
- Occasional cortical cysts in the kidneys
- Hypoechoic liver with increased portal markings

INTERPRETATION OF THE FINDINGS & FURTHER RECOMMENDATIONS

Ultrasound guided FNA of the ileocecal mass and spleen is recommended. Splenic and ileocecal round cell neoplasia is suspected. Prognosis is very guarded depending upon eventual responsiveness to chemotherapy. Three view chest radiographs or chest CT is warranted to assess for metastatic disease.





The information and recommendations provided are based on the images presented by the referring veterinarian. No evaluation can be communicated regarding pathology that was not visible

in the image/video clips provided.

Thank you for this referral. If the clinical or image interpretation does not parallel your findings or if I can be of any further assistance please contact me.

Eric Lindquist, DMV, DABVP, Cert. IVUSS, CEO of SonoPath.com
info@SonoPath.com