

**DATE PRESENTING CLINICAL SIGNS**

5/1/23

PATIENT

Sprinkles Doyle

SPECIES

Feline

BREED

DSH

SEX

Spayed Female

AGE

12/20/08

WEIGHT

11.8 Pounds

INTERPRETED BYEric Lindquist, DMV
DABVP, Cert. IVUSS**HOSPITAL NAME**

Fullerton AH

REFERRING VET

Dr. Durastanti

INVOICE

22271

History: Patient presented this AM 5/1/23 with a 24 hour history of vomiting. Little appetite, and lethargic. Has had foreign body surgery in the past and has a history of dietary indiscretion, although O doesn't know that she has eaten anything foreign recently. X-rays were sent out and BW was performed in hospital today (see attached). On PE P is dehydrated, and belly is soft and doughy. No other significant changes on PE. Pet did not get food or insulin this morning. Patient has a long term history of diabetes, well controlled on Vetsulin 2.5U BID. More recent history of SDMA elevation, started on renal diet about 2 weeks ago. Also had a dental with multiple extractions last month.

Current Medications: Vetsulin 2.5U BID, Cerenia 1mg/kg SC this AM

Lab Results: SDMA elevated, Glucose elevated, ALT elevated

Radiographs: Radiology report from this AM: "The apparent increase in intestinal wall thickness in some areas could be an artifact due to lack of distention and/or fluid layering. However, this is more likely in this case that this represents a true increase in thickness of the intestinal wall due to inflammatory bowel disease or small intestinal lymphoma. An abdominal ultrasound should be considered for further evaluation."

Date of Previous IntraPet Ultrasound: No previous.

Sedation: Not required to complete full diagnostic ultrasound.

Stat Report: Not requested.

Imaging Performed By: Rachel Brillhart, RDMS.

ULTRASONOGRAPHIC EXAMINATION OF THE ABDOMEN**Urinary System**

The **urinary bladder**, trigone, and pelvic urethra presented normal thicknesses and normal tone. The ureters were not visible which is normal. No uroliths or sediment were visualized and anechoic urine was present. No evidence of inflammatory or neoplastic changes were noted. Ureteral papillae were normal.

The **kidneys** revealed largely normal size and structure, corticomedullary definition and ratio (cortex 1/3 of medulla) were essentially maintained with some minor age-related loss of curvilinear patterns regarding the capsule and C/M junction. The cortices presented largely uniform texture with some increased echogenicity expected for his age patient. Medullary structure differed distinctly from that of the cortex. Slight pyelectasia (0.41 cm) was noted in the right kidney. The right kidney measured 3.35 cm. The right kidney measured 3.5 cm.

Adrenal Glands

The regions of the **adrenal glands** revealed no evident pathology.

Spleen

The **spleen** presented a smooth homogeneous parenchyma hyperechoic to liver and renal cortical parenchyma. The capsule was smooth without noticeable expansion or deviation from within the spleen or adjacent pathology. The splenic vasculature demonstrated normal volume without signs of congestion or thrombosis. No sonographic evidence of acute or chronic inflammatory, neoplastic, or infarctual changes were noted.

Liver

The **liver** revealed mild increased portal markings. The gallbladder was duplicated, mildly thickened and echogenic, consistent with a history of cholangitis. The common bile duct was dilated up to 0.7 cm, however, tapered adequately to the duodenal papilla. The cystic duct was also tortuous.

Gastrointestinal

The **gastrointestinal** presentation revealed mild uniform prominence of the gastric mucosa as well as areas of "ropey" small intestinal wall with slight disruption of the normal 1:3 muscularis/mucosal ratio. The intestinal submucosa was slightly irregular, thickened and hyperechoic suggestive of low grade, chronic disease. No concerning lymphadenopathy was visible. No evidence of obstruction was present. Chronic inflammatory bowel disease is likely with a low possibility of an early neoplastic event such as lymphoma. Full thickness tissue biopsies via open laparotomy, ideally guided by intraoperative ultrasound in order to obtain the most representative mural sample, would be necessary to rule out this possibility. Reactive mesentery was noted around the small intestine.

Pancreas

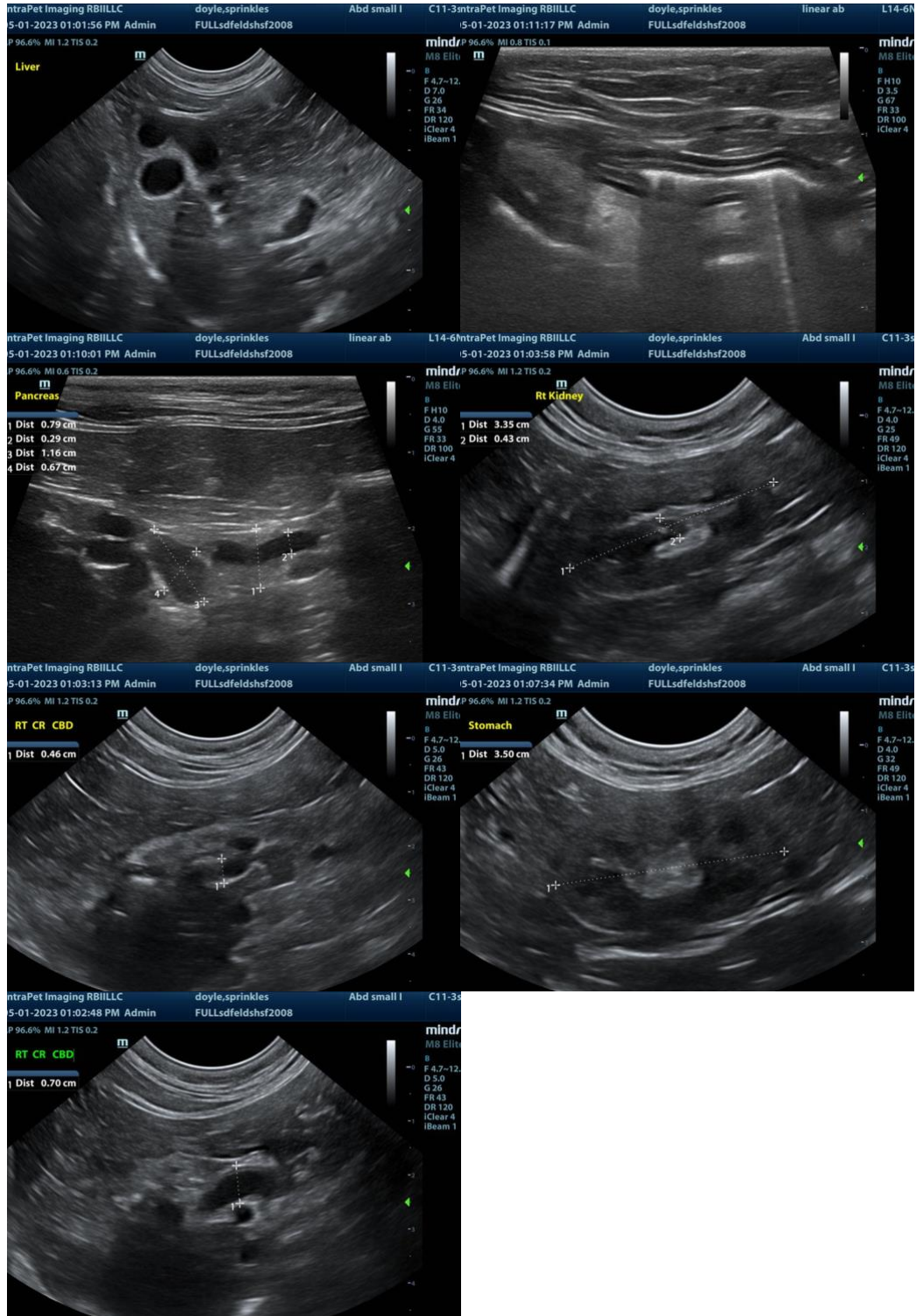
The **pancreas** revealed undulating duct contour. A hypoechoic 1.16 cm x 0.67 cm nodule or overlying lymph node was noted. Heterogenous pancreatic changes were noted throughout the left and right limbs. Enhanced mesentery was noted around the pancreas.

ULTRASONOGRAPHIC FINDINGS

- Chronic cholangitis with dilated common bile duct, however, given the lack of ALP and bilirubin elevations, overt obstruction is not present.
- Duplicated gallbladder (normal variant)
- Diffuse intestinal thickening with reactive mesentery noted around the small intestine. Acute on chronic enteritis/inflammatory bowel is likely.
- Chronic active pancreatitis
- Age-related renal changes with minor pyelectasia- underlying UTI is a potential
- Acute on chronic triaditis presentation

INTERPRETATION OF THE FINDINGS & FURTHER RECOMMENDATIONS

Dysfunctional duodenal papilla may be the underlying cause of CBD dilation, as well as chronic inflammatory events. I recommend stabilization of the diabetic state in this patient. Pain management, IV fluid support, broad spectrum antibiotics and enrofloxacin (to penetrate the biliary tree adequately) is warranted. Ideally, surgical gastrointestinal, pancreatic and hepatic biopsies would be performed to rule out emerging neoplasia, though not suspected. Recheck sonogram in 72 hours if the patient is improving, or earlier if bilirubin/ALP elevations become an issue.



The information and recommendations provided are based on the images presented by the referring veterinarian. No evaluation can be communicated regarding pathology that was not visible

in the image/video clips provided.

Thank you for this referral. If the clinical or image interpretation does not parallel your findings or if I can be of any further assistance please contact me.

Eric Lindquist, DMV, DABVP, Cert. IVUSS, CEO of SonoPath.com
info@SonoPath.com