

PATIENT

Romeo Kebler

SPECIES

Feline

BREED

Persian

SEX

Neutered Male

AGE

15 Years

WEIGHT

8.4 Pounds

INTERPRETED BY

Eric Lindquist, DMV
DABVP, Cert. IVUSS

IMAGING PERFORMED BY

Diane McFadden

HOSPITAL NAME

Newton VH

REFERRING VET

Dr. Harris

INVOICE

22238

DATE

5/1/23

PRESENTING CLINICAL SIGNS

History: anorexic for a week; was vomiting a few days ago; weight loss.

Abnormal PE/Chem/CBC/UA Results: 4/15/23 retic 1.9 low, ALKP 12 low

ULTRASONOGRAPHIC EXAMINATION OF THE ABDOMEN

Urinary System

The **urinary bladder**, trigone, and pelvic urethra presented normal thicknesses and normal tone. The ureters were not visible which is normal. No uroliths or sediment were visualized and anechoic urine was present. No evidence of inflammatory or neoplastic changes were noted. Ureteral papillae were normal.

The **kidneys** presented a relatively uniform cortical hyperechogenicity when compared to the renal medulla, spleen and liver. No overt masses were noted. Corticomedullary definition was nebulous and the ratio favored the cortex slightly. The ureters were not visible and assumed to be normal. These changes are most consistent with chronic interstitial nephritis yet infiltrative disease could not be entirely ruled out without biopsy though neoplasia is not suspected. This is a moderate change. The left kidney measured 4.15 cm. The right kidney measured 4.5 cm. Signals appear to be subjectively subnormal on power doppler assessment

Adrenal Glands

Both **adrenal glands** were visualized and recognized as having normal shape, size, position and echogenicity for this breed. The phrenic vasculature, glandular echogenicity and detail were unremarkable. Capsule, cortex, and medullary definition were normal for this age patient. The right adrenal gland measured 0.43 cm. The left adrenal gland measured 0.26 cm.

Spleen

The **spleen** presented a smooth homogeneous parenchyma hyperechoic to liver and renal cortical parenchyma. The capsule was smooth without noticeable expansion or deviation from within the spleen or adjacent pathology. The splenic vasculature demonstrated normal volume without signs of congestion or thrombosis. No sonographic evidence of acute or chronic inflammatory, neoplastic, or infarctual changes were noted.

Liver

The **liver** was diffusely hyperechoic with coarse architecture and generalized enlargement. The gallbladder and common bile duct were unremarkable.

Gastrointestinal

The **gastrointestinal** presentation revealed mild uniform prominence of the gastric mucosa as well as areas of "ropey" small intestinal wall with slight disruption of the normal 1:3 muscularis/mucosal ratio. The intestinal submucosa was slightly irregular, thickened and hyperechoic suggestive of low grade, chronic disease. No concerning lymphadenopathy was visible. No evidence of obstruction was present. Chronic inflammatory bowel disease is likely with a low possibility of an early neoplastic event such as lymphoma. Full thickness tissue biopsies via open laparotomy, ideally guided by



PATIENT

Romeo Kebler

intraoperative ultrasound in order to obtain the most representative mural sample, would be necessary to rule out this possibility. This is a minor change.

Pancreas

SPECIES

Feline

The **pancreas** was hypoechoic and irregular with enhanced surrounding mesentery, suggestive for chronic active inflammation.

ULTRASONOGRAPHIC FINDINGS

BREED

Persian

- Chronic active pancreatitis
- Minor intestinal thickening- chronic inflammatory bowel is likely
- Chronic interstitial nephrosis
- Hyperechoic liver with coarse architecture and generalized enlargement

SEX

Neutered Male

INTERPRETATION OF THE FINDINGS & FURTHER RECOMMENDATIONS

AGE

15 Years

No obvious evidence of neoplasia. Maldigestion panel, three view chest radiographs and full CNS examination is recommended to examine for occult disease that could be responsible for the weight loss. Evaluation for competitive eating environments should also be considered. Treatment for inflammatory bowel and pancreatitis with the following protocol or similar could be considered. If liver enzyme elevations occur, then FNA is indicated.

WEIGHT

8.4 Pounds

Triaditis/Pancreatitis protocol

Part or all of this protocol may be considered based on your clinical impression of the patient:

INTERPRETED BY

Eric Lindquist, DMV
DABVP, Cert. IVUSS

Recommend pain management when anorexic with **Buprenorphine** (0.01-0.02 mg/kg IM or SC), clinical trial of **Zithromax** (50 mg sid/cat x 10 days, 3 weeks if bartonella +), **Prednisolone** (0.5-2 mg/kg tapering over 1 week to minimal effective dose), and **B12 injections** if weight loss (Cyanobalamine 250 mcg sub-q once-weekly x six weeks, then every other week for six weeks and then once-monthly, long-term if necessary), **novel-protein or hydrolyzed diet** (*Hydrolyzed diets have been shown to be more effective in dietary intolerance case management compared to hypoallergenic diets*) or the **magical Purina DM** (changing protein source is crucial and may need rotation every 6 months if clinical signs recur) Diet trials is a whatever works phenomenon. If vomiting becomes a persistent issue then endoscopy would be warranted and/or recheck sonogram to assess more emerging disease. One diet does not work for all patients so different trials may be necessary or protein source rotation every 6 months as new sensitivities develop.

IMAGING PERFORMED BY

Diane McFadden

HOSPITAL NAME

Newton VH

REFERRING VET

Dr. Harris

INVOICE

22238

DATE

5/1/23



PATIENT

Romeo Kebler

SPECIES

Feline

BREED

Persian

SEX

Neutered Male

AGE

15 Years

WEIGHT

8.4 Pounds

INTERPRETED BY

Eric Lindquist, DMV
DABVP, Cert. IVUSS

IMAGING PERFORMED BY

Diane McFadden

HOSPITAL NAME

Newton VH

REFERRING VET

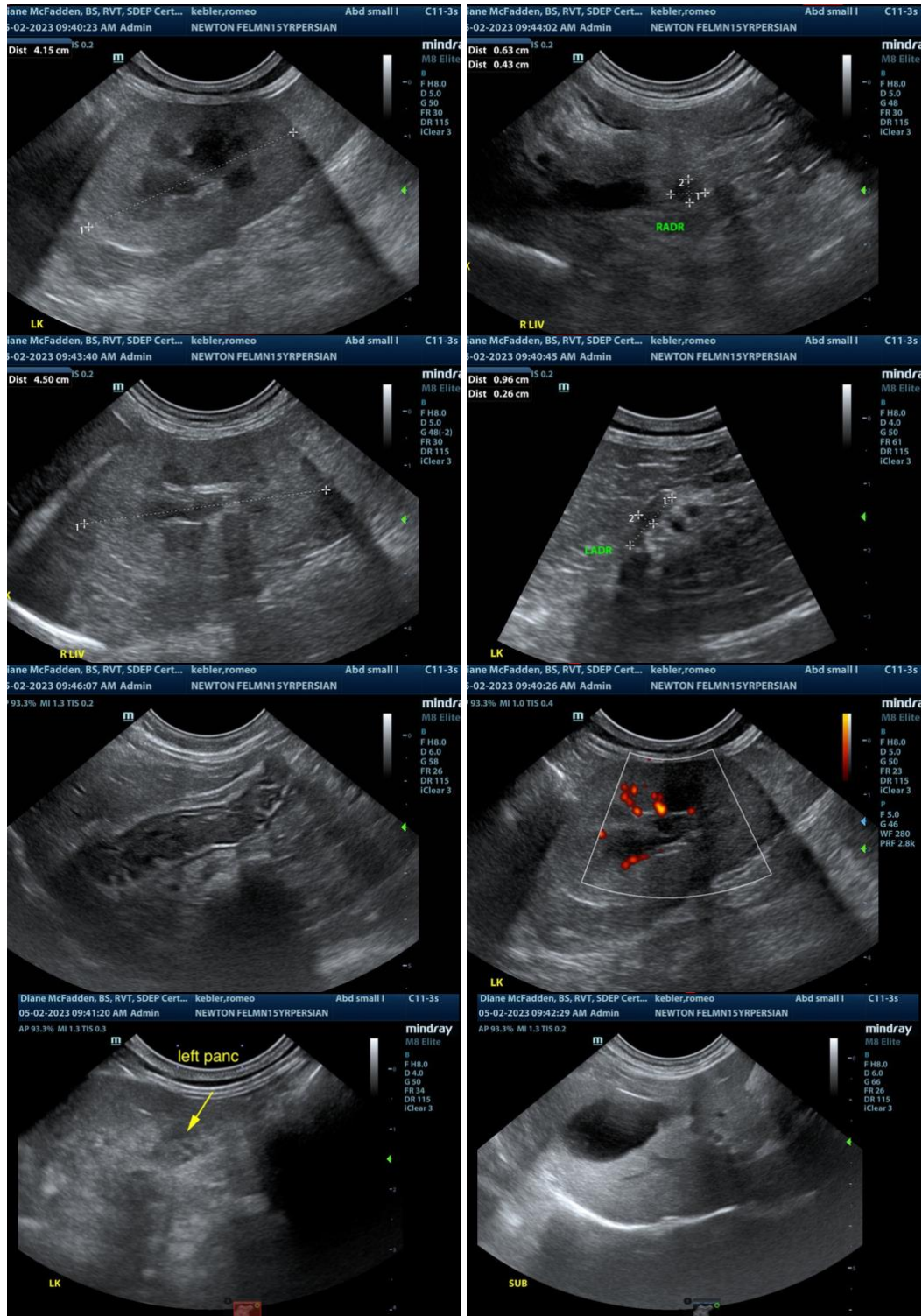
Dr. Harris

INVOICE

22238

DATE

5/1/23





PATIENT

Romeo Kebler

SPECIES

Feline

BREED

Persian

SEX

Neutered Male

AGE

15 Years

WEIGHT

8.4 Pounds

INTERPRETED BY

Eric Lindquist, DMV
DABVP, Cert. IVUSS

**IMAGING
PERFORMED BY**

Diane McFadden

HOSPITAL NAME

Newton VH

REFERRING VET

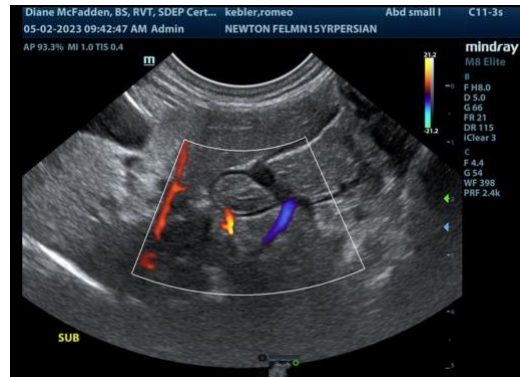
Dr. Harris

INVOICE

22238

DATE

5/1/23



The information and recommendations provided are based on the images presented by the referring veterinarian. No evaluation can be communicated regarding pathology that was not visible in the image/video clips provided.

Thank you for this referral. If the clinical or image interpretation does not parallel your findings or if I can be of any further assistance please contact me.

Eric Lindquist, DMV, DABVP, Cert. IVUSS, CEO of SonoPath.com
info@SonoPath.com