

**DATE PRESENTING CLINICAL SIGNS**

5/1/23

**PATIENT**

Lilo Adams

History: Geriatric, recent decreased HCT noted on screening labs compared to previous studies. New heart murmur 1/6 PMI L apex. Dog presented for a history of GI upset and still has been demonstrating PICA. History of liver value elevations but has normalized. Overall looking for geriatric screen as dog is otherwise asymptomatic.

**SPECIES**

Canine

**BREED**Labrador Retriever  
Mix**SEX**

Spayed Female

**AGE**

12/23/10

**WEIGHT**

62.6 Pounds

**INTERPRETED BY**Eric Lindquist, DMV  
DABVP, Cert. IVUSS**HOSPITAL NAME**

Everhart VH

**REFERRING VET**

Dr. Notarangelo

**INVOICE**

22280

Current Medications: Cerenia 60mg Tablet 4/7/2023, DENAMARIN 425 MG. # 30 11/22/2022, Carprofen 100mg tablet 11/21/2022, Flexadin Advanced 60ct 11/21/2022, Sentinel 51-100lbs 6pk 6/23/2022  
 Lab Results: 4/14/23: PCV 43. 4/7/23: HCT 25, PCV 43, retic 204, crea 2. 11/21/22: hct 51, ALT 316, crea 2, USG 1.009.

Date of Previous IntraPet Ultrasound: No previous.  
 Sedation: Not required to complete full diagnostic ultrasound.  
 Stat Report: Not requested.  
 Imaging Performed By: Stephanie Warga RDCS, RVT.

**ULTRASONOGRAPHIC EXAMINATION OF THE ABDOMEN****Urinary System**

The **urinary bladder**, trigone, and pelvic urethra presented normal thicknesses and normal tone. The ureters were not visible which is normal. No uroliths or sediment were visualized and anechoic urine was present. No evidence of inflammatory or neoplastic changes were noted. Ureteral papillae were normal.

The **kidneys** revealed largely normal size and structure, corticomedullary definition and ratio (cortex 1/3 of medulla) were essentially maintained with some moderate age-related loss of curvilinear patterns regarding the capsule and C/M junction. The cortices presented largely uniform texture with some increased echogenicity expected for his age patient. Medullary structure differed distinctly from that of the cortex. The right kidney measured 5.6 cm. The left kidney measured 6.04 cm. Slight pyelectasia (0.41 cm) was noted in the left kidney.

**Adrenal Glands**

Both **adrenal glands** were visualized and recognized as having normal shape, size, position and echogenicity for this breed. The phrenic vasculature, glandular echogenicity and detail were unremarkable. Capsule, cortex, and medullary definition were normal for this age patient. The right adrenal gland measured 2.57 cm x 0.49 cm at the caudal pole and 0.73 cm at the cranial pole. The left adrenal gland measured 2.78 cm x 0.79 cm at the caudal pole and 0.62 cm at the cranial pole.

**Spleen**

The **spleen** revealed minor ill-defined heterogenous hypoechoic nodular changes.

**Liver**

The **liver** images from right and left intercostal as well as subcostal views revealed subjectively normal liver size, contour, and structure. Some minor age-related parenchymal remodeling was noted but likely not clinically significant at this time. Vascular and biliary tracts were of normal volume and no evidence of congestion was noted. The gallbladder presented some dependent debris with essentially normal contour. The cystic and common bile ducts were normal. No overt evidence of active inflammatory, infiltrative or regenerative pathology was noted but should be paired with current or past LE elevations regarding any clinical significance to this presentation. The hepatic lymph nodes were unremarkable.

### ***Gastrointestinal***

The **stomach** revealed a 4.0 cm shadowing structure in the gastric lumen, nonobstructive. No stasis was noted prior to the structure; however, this would suggest foreign matter if the patient was NPO at the time of the sonogram. Minor gastric wall thickening was noted. The pylorus was patent at the time of the sonogram. Ultrasound is recommended just prior to surgery to ensure the structure is persistently present. The small intestine and colon were unremarkable.

### ***Pancreas***

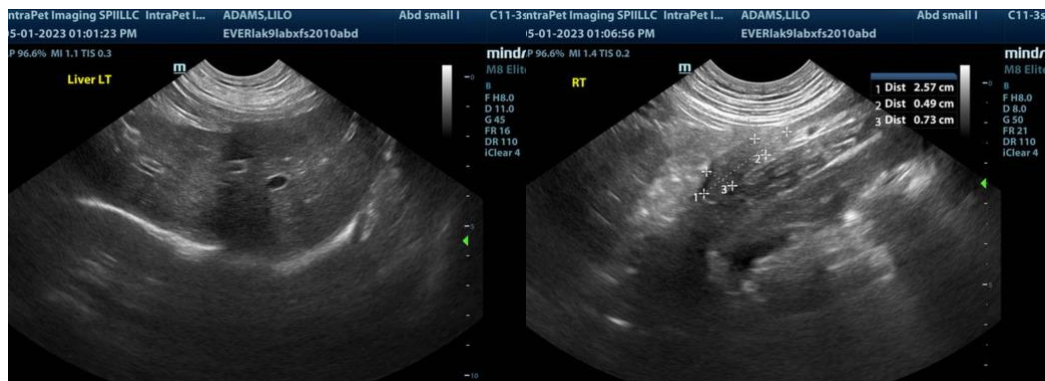
The base and limbs of the **pancreas** were observed to be largely isoechoic to surrounding omental fat. Pancreatic duct and capsular contour were acceptably normal and parenchyma respected normal curvilinear patterns. No overt evidence of active inflammatory or neoplastic disease was noted.

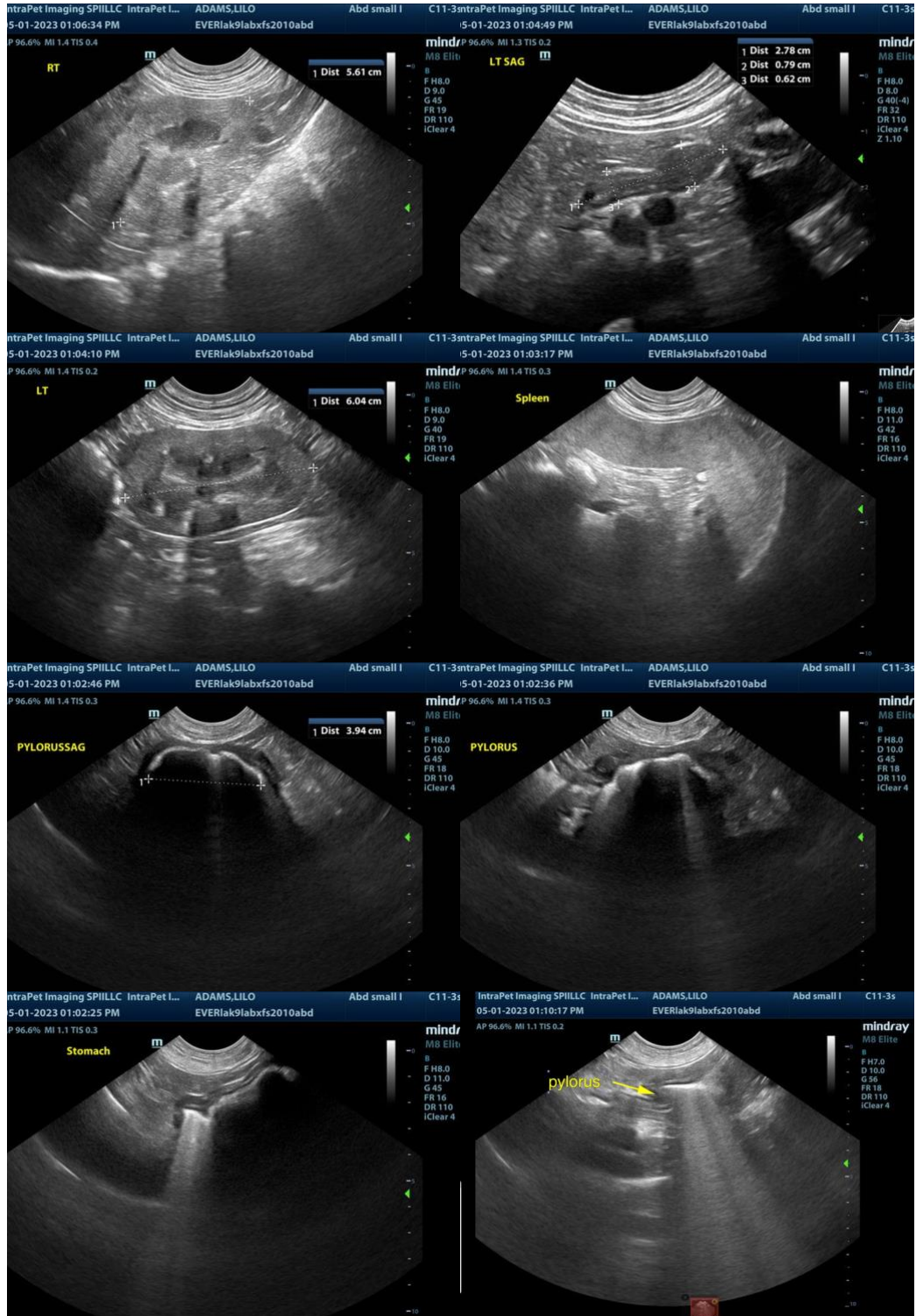
### **ULTRASONOGRAPHIC FINDINGS**

- Hyperplastic spleen
- 4.0 cm gastric foreign matter
- Age-related renal changes with slight pyelectasia in the left kidney
- Age-related hepatic changes
- Geriatric abdomen otherwise

### **INTERPRETATION OF THE FINDINGS & FURTHER RECOMMENDATIONS**

Surgical intervention with gastrotomy and inspection of the gastric mucosa for any hemorrhage is warranted. CBC path review is indicated. Screening FNA of the spleen could be considered, as it would be most consistent with hyperplasia. Repeat ultrasound of the stomach again just prior to surgery to ensure that the structure is still present. No other evidence of pathology to be responsible for the history of anemia in this patient.





The information and recommendations provided are based on the images presented by the referring veterinarian. No evaluation can be communicated regarding pathology that was not visible

**in the image/video clips provided.**

Thank you for this referral. If the clinical or image interpretation does not parallel your findings or if I can be of any further assistance please contact me.

**Eric Lindquist**, DMV, DABVP, Cert. IVUSS, CEO of SonoPath.com  
info@SonoPath.com