



PATIENT

Ruby Hood

SPECIES

Canine

BREED

Rottweiler Mix

SEX

Spayed female

AGE

9 years

WEIGHT

35.4 lbs

INTERPRETED BY

Eric Lindquist, DMV
DABVP, Cert. IVUSS

IMAGING PERFORMED BY

Harnoor Bhinder

HOSPITAL NAME

Hespeler AH

REFERRING VET

Dr. Bhinder

INVOICE

74384

DATE

4/9/26

PRESENTING CLINICAL SIGNS

History: Starting on 30 March 2026, Ruby started to be lethargic, PU/PD, Abdominal distension, rapid breathing, anorexia

Blood work Elevated Alt 140 12-118 Alk Phosphatase 928 05-131 Bilirubin 5.8 0-5.1

ULTRASONOGRAPHIC EXAMINATION OF THE ABDOMEN

Urinary System

The **bladder** in this patient was mildly thickened with slight echogenic mural changes. No calculi or masses were noted. Slight micropolypoid changes were noted. This is a frequent finding in older animals and may be linked to a history of chronic urinary tract infection or active urinary tract infection.

Urinalysis would be recommended with culture if any evidence of inflammatory sediment is present.

The region of the trigone and visible pelvic urethra were normal.

The **kidneys** revealed largely normal size and structure, corticomedullary definition and ratio (cortex 1/3 of medulla) were essentially maintained with some age-related loss of curvilinear patterns regarding the capsule and C/M junction. The cortices presented largely uniform texture with some increased echogenicity expected for this age patient. Medullary structure differed distinctly from that of the cortex and no evidence of pelvic dilation was present. An anechoic 3.5 cm cyst was noted at the caudal pole. The right kidney measured 6.57 cm. The left kidney measured 6.4 cm.

Adrenal Glands

Both **adrenal glands** were visualized and recognized as having normal shape, size, position and echogenicity for this breed. The phrenic vasculature, glandular echogenicity and detail were unremarkable. Capsule, cortex, and medullary definition were normal for this age patient. The left adrenal gland measured

Spleen

The **spleen** in this patient was mildly enlarged with uniform parenchyma and was folded upon itself cranially. This is a positional variant and is not pathological. There was no evidence of significant disease.

Liver

The **liver** images submitted revealed subjectively normal liver size, contour, and structure. Parenchymal echogenicity was naturally coarse and hypoechoic to the spleen. Hepatic vein dilation was noted. The gallbladder presented acceptably thin walls with primarily anechoic content. The cystic and common bile ducts were normal. No pathological hepatic lymphadenopathy was evident. No overt structural evidence of inflammatory, infiltrative or regenerative pathology was evident. A severe amount of pericardial effusion was noted through the diaphragm and imaged from right intercostal approach. Tamponade effect was noted as well.



PATIENT

Ruby Hood

SPECIES

Canine

BREED

Rottweiler Mix

SEX

Spayed female

AGE

9 years

WEIGHT

35.4 lbs

INTERPRETED BY

Eric Lindquist, DMV
DABVP, Cert. IVUSS

IMAGING PERFORMED BY

Harnoor Bhinder

HOSPITAL NAME

Hespeler AH

REFERRING VET

Dr. Bhinder

INVOICE

74384

DATE

4/9/26

Gastrointestinal

There was some residual chyme and gas was noted in the **stomach**, yet not pathological. This is consistent with post prandial presentation. Transit of chyme into the small intestine was normal. Curvilinear patterns were maintained throughout the GI tract. No evidence of pathology. Small and large intestine demonstrated normal luminal chyme and stool consistency respectively. No obstructive or overt infiltrative disease was noted. No associated abnormal lymphatic activity was noted.

Pancreas

The base and limbs of the **pancreas** were observed to be largely isoechoic to surrounding omental fat. Pancreatic duct and capsular contour were acceptably normal and parenchyma respected normal curvilinear patterns. No overt evidence of active inflammatory or neoplastic disease was noted.

Free Abdomen

A mild to moderate amount of ascites was noted in the abdomen.

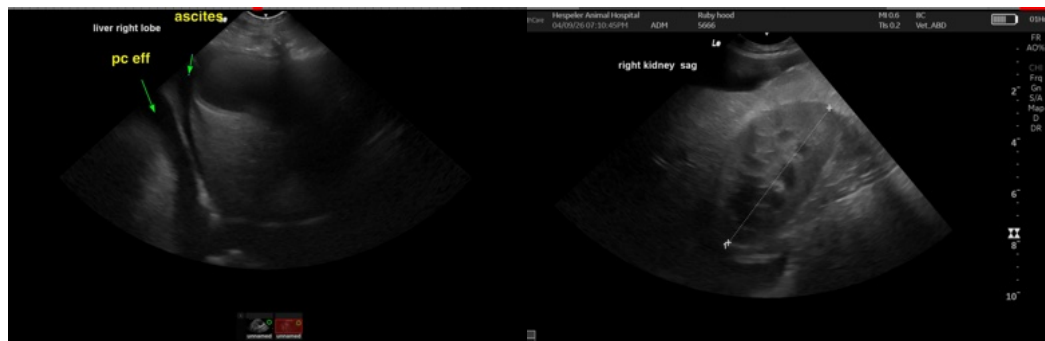ULTRASONOGRAPHIC FINDINGS

Severe amount of pericardial effusion and tamponade effect was noted.

Passive congestion abdomen with ascites.

INTERPRETATION OF THE FINDINGS & FURTHER RECOMMENDATIONS

Ultrasound-guided pericardiocentesis is warranted with further imaging at SDEP 3 from a cardiac standpoint.





PATIENT

Ruby Hood

SPECIES

Canine

BREED

Rottweiler Mix

SEX

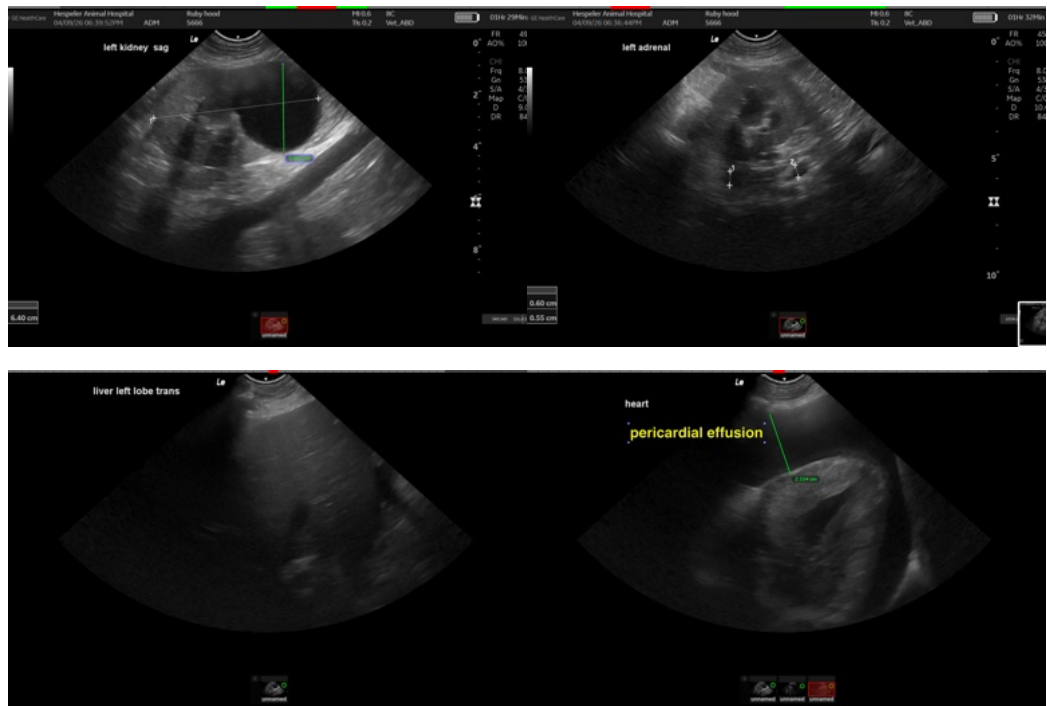
Spayed female

AGE

9 years

WEIGHT

35.4 lbs



INTERPRETED BY

Eric Lindquist, DMV
DABVP, Cert. IVUSS

The information and recommendations provided are based on the images presented by the referring veterinarian/sonographer. No evaluation can be communicated regarding pathology that was not visible in the image/video clips provided.

Thank you for this referral. If the clinical or image interpretation does not parallel your findings or if I can be of any further assistance please contact me.

Eric Lindquist, DMV, DABVP (CFM), Cert. IVUSS, CEO of SonoPath.com

IMAGING PERFORMED BY

Harnoor Bhinder

info@SonoPath.com

HOSPITAL NAME

Hespeler AH

Pericardial Effusion and Cardiac Neoplasia

<http://www.sonopath.com/CardiacNeoplasiaEffusion>

REFERRING VET

Dr. Bhinder

Description: The pericardium is a fibrous sac that encloses the heart and the great vessels—aorta, pulmonary artery, proximal pulmonary veins, and vena cava—located at the heart's base. It is attached caudally to the diaphragm and under normal circumstances contains 1-15 mL of fluid. The latter is comprised of phospholipids that lubricate the heart and allow it to expand and contract without generating friction. The pericardium also fixes the heart, prevents excess motion, and links the diastolic distensibility of the ventricles, thus limiting the degree to which either the left or the right ventricle will distend during diastole. When there are acute changes in venous return (i.e., during exercise), the pericardium plays a critical role in limiting ventricular filling. In cases of chronic cardiac enlargement, the pericardium also becomes distended, and its ability to limit ventricular filling, especially when the heart is at rest, becomes compromised. Pericardial tamponade occurs when there is a rapid accumulation of fluid and the pressure inside the pericardium increases significantly. With tamponade, ventricular filling is restricted and cardiac

INVOICE

74384

DATE

4/9/26



PATIENT

Ruby Hood

SPECIES

Canine

BREED

Rottweiler Mix

SEX

Spayed female

AGE

9 years

WEIGHT

35.4 lbs

INTERPRETED BY

Eric Lindquist, DMV
DABVP, Cert. IVUSS

IMAGING PERFORMED BY

Harnoor Bhinder

HOSPITAL NAME

Hespeler AH

REFERRING VET

Dr. Bhinder

INVOICE

74384

DATE

4/9/26

output is decreased. The right atrium and ventricle are the most vulnerable to this condition as these compartments have thinner walls and a lower pressure.

Etiology: Causes of pericardial effusion include:

- Neoplasia
 - Right atrial (RA) hemangiosarcoma
 - Heart base (aortic body) tumors
 - Mesothelioma
 - Rhabdomyosarcoma
 - Ectopic thyroid carcinoma
 - Metastatic neoplasia
- Idiopathic
- Congestive heart failure
- Peritoneal-pericardial diaphragmatic hernia
- Pericardial cyst
- Hypoalbuminemia
- Infectious pericarditis (bacterial, *Coccidioides immitus*)
- Feline infectious peritonitis
- Left atrial tear secondary to valvular disease
- Coagulopathy

The majority of neoplastic masses consist of hemangiosarcoma and heart-based tumors (chemodectomas or ectopic thyroid adenocarcinoma). Idiopathic pericardial effusion is a diagnosis of exclusion; the effusion is typically hemorrhagic. Approximately 50% of dogs will be cured with a single pericardiocentesis, while some dogs will require multiple pericardiocenteses as well as surgery. A peritoneal-pericardial diaphragmatic hernia is a congenital hernia seen in dogs and cats in which the abdominal contents (i.e., liver, small intestine, spleen, stomach) herniate into the pericardial sac. Constrictive pericarditis is an uncommon condition in which a non-distensible, thickened, fibrotic pericardium develops over time.

Clinical Signs: One will observe the following clinical signs, which often present in combination: ascites, lethargy, exercise intolerance, pale mucous membranes, weak pulses, *pulsus paradoxus*, and respiratory distress.

Diagnostics: Survey radiographs will reveal hepatomegaly, cardiomegaly (generalized or sectorial globoid), and small pulmonary vessels. Pulmonary edema is typically not found, although one may discover concurrent pulmonary metastatic disease. An ECG will show electrical alternans or small complexes, but often the changes are very subtle and difficult to detect.

Echocardiography is usually considered the gold standard for diagnosing pericardial effusion. Findings include:

- Anechoic space between the heart and the pericardium.
- Abnormal side-to-side cardiac motion.
- Decreased chamber size (right ventricle [RV] and left ventricle [LV]).
- Presence of a pericardial or cardiac mass.



PATIENT

- Tamponade with early diastolic RA and RV collapse.

Ruby Hood

SPECIES

Cytology is helpful in the diagnosis of lymphoma, septic pericarditis, and idiopathic effusion, but not in cases of neoplasia.

Canine

According to a study that found troponin I levels to be higher in dogs with neoplastic pericardial effusion, the cardiac troponin I assay can be helpful in the diagnosis hemangiosarcoma.

BREED

Rottweiler Mix

Prognosis:

SEX

- Cardiac hemangiosarcoma: < 8 months with surgical debulking and chemotherapy.
- Chemodectoma (aortic derived): MST 730 days post pericardectomy.
- Idiopathic: 50% complete resolution post cardiocentesis; curative with pericardectomy, which can be done via thoracotomy, or thoracoscopy, or using a balloon to tear the pericardium.
- Mesothelioma: Poor.
- Restrictive pericarditis: Poor, especially when the pericardium has not been surgical stripped.

Spayed female

AGE

9 years

References:

WEIGHT

Cagle LA, Epstein SE, Owens SD, et al. Diagnostic yield of cytology analysis of pericardial effusion in dogs. *J Vet Int Med* 2014;28:66-71.

35.4 lbs

Feigenbaum H. Pericardial disease. In: Feigenbaum H, ed. *Echocardiography, 5th ed.* Philadelphia, PA: Lippincott, Williams & Wilkins; 1994:556-588.

INTERPRETED BY

Eric Lindquist, DMV
DABVP, Cert. IVUSS

Jackson J, Richter KP, Launer DP. Thorascopic partial pericardectomy in 13 dogs. *J Vet Int Med* 1999;13:529-33.

IMAGING PERFORMED BY

Harnoor Bhinder

Johnson MS, Martin M, Binns S. A retrospective study of clinical findings, treatment and outcome in 143 dogs with pericardial effusion. *J Small Anim Prac* 2004;45:546-52.

Kienle RD, Thomas WP. Echocardiography. In: Nyland TG and Mattoon JS, eds. *Small Animal Diagnostic Ultrasound, 2nd ed.* Philadelphia, PA: WB Saunders; 2000:354-423.

HOSPITAL NAME

Hespeler AH

Miller MW, Sisson DD. Pericardial disorders. In: Ettinger SJ and Feldman EC, eds. *Textbook of Veterinary Internal Medicine, 5th ed.* Philadelphia, PA: WB Saunders; 2000:923-36.

REFERRING VET

Dr. Bhinder

Rajagopalan V, Jesty SA, Craig LE, et al. Comparison of presumptive echocardiographic and definitive diagnoses of cardiac tumors in dogs. *J Vet Int Med* 2013;27:1092-96.

INVOICE

74384

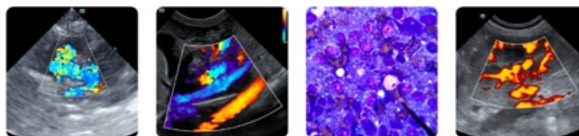
Shaw SP, Rozanski EA, Ruhs JE. Cardiac troponins I and T in dogs with pericardial effusion. *J Vet Int Med* 2004;18:322-24.

DATE

4/9/26

Sidley JA, Atkins CE, Keene BW, et al. Percutaneous balloon pericardiotomy as a treatment for recurrent pericardial effusion in 6 dogs. *J Vet Intern Med* 2002;16:541.

Sisson D, Thomas WP. Pericardial disease and cardiac tumors. In: Fox PR, Sisson D, Moïse NS, eds. *Textbook of Canine and Feline Cardiology, 2nd ed.* Philadelphia, PA: WB Saunders; 1999:679-701.



PATIENT

Ruby Hood

SPECIES

Canine

BREED

Rottweiler Mix

SEX

Spayed female

AGE

9 years

WEIGHT

35.4 lbs

INTERPRETED BY

Eric Lindquist, DMV
DABVP, Cert. IVUSS

**IMAGING
PERFORMED BY**

Harnoor Bhinder

HOSPITAL NAME

Hespeler AH

REFERRING VET

Dr. Bhinder

INVOICE

74384

DATE

4/9/26

Sisson D, Thomas WP, Reed J, et al. Intrapericardial cysts in the dog. *J Vet Int Med* 1993;7:364-69.