



PATIENT

Cooper Rinaldi

SPECIES

Canine

BREED

Labrador Retriever

SEX

Neutered Male

AGE

12 Years

WEIGHT

96.6 lbs

INTERPRETED BY

Eric Lindquist, DMV,
DABVP (CFM), Cert.
IVUSS

IMAGING PERFORMED BY

Rebecca Hamilton

HOSPITAL NAME

Bergen County
Veterinary Clinic

REFERRING VET

Dr. Santo

INVOICE

74337

DATE

4/9/26

PRESENTING CLINICAL SIGNS

Mass effect in abdomen, Increase restfulness
Abnormal PE/Chem/CBC/UA Results: No updated bloodwork

ULTRASONOGRAPHIC EXAMINATION OF THE ABDOMEN

Urinary System

The **urinary bladder**, trigone, and pelvic urethra presented normal thicknesses and normal tone. The ureters were not visible which is normal. No uroliths or sediment were visualized and anechoic urine was present. No evidence of inflammatory or neoplastic changes were noted. Ureteral papillae were normal. The pelvic urethra was imaged 2.0 cm beyond the cystourethral junction.

The **kidneys** revealed normal size and structure, corticomedullary definition and ratio for this age. The cortices presented largely uniform texture with normal echogenic relationship to liver and spleen. Medullary structure differed distinctly from the cortex and no evidence of pelvic dilation was present. The capsules were acceptably uniform without significant irregularities. Right kidney measured 7.3 cm. Left kidney measured 7.6 cm.

Adrenal Glands

Both **adrenal glands** were visualized and recognized as having normal shape, size, position and echogenicity for this breed. The phrenic vasculature, glandular echogenicity and detail were unremarkable. Capsule, cortex, and medullary definition were normal for this age patient. Left measured 2.44 cm x 0.60 cm at the cranial pole and 0.57 cm at the caudal pole. Right measured 2.68 cm x 1.02 cm at the cranial pole and 0.44 cm at the caudal pole.

Spleen

The **spleen** revealed a large parenchymal mass at the cranial body measuring 5.6 cm, non-cavitated. No evidence of rupture or active inflammation.

Liver

The **liver** images from right and left intercostal as well as subcostal views revealed subjectively normal liver size, contour, and structure. Some age-related parenchymal remodeling was noted but likely not clinically significant at this time. Vascular and biliary tracts were of normal volume and no evidence of congestion was noted. The gallbladder presented some dependent debris with essentially normal contour. The cystic and common bile ducts were normal. No overt evidence of active inflammatory, infiltrative or regenerative pathology was noted but should be paired with current or past LE elevations regarding any clinical significance to this presentation. The hepatic lymph nodes were unremarkable.

Gastrointestinal

Examination of the **gastrointestinal tract** revealed a stomach and intestine free of stasis, of normal wall thickness, acceptable curvilinear mural detail, and peristaltic activity. Small and large intestine demonstrated normal luminal chyme and stool consistency respectively. No obstructive or overt infiltrative disease was noted. No associated abnormal lymphatic activity was noted.



PATIENT

Cooper Rinaldi

SPECIES

Canine

BREED

Labrador Retriever

SEX

Neutered Male

AGE

12 Years

WEIGHT

96.6 lbs

INTERPRETED BY

Eric Lindquist, DMV,
DABVP (CFM), Cert.
IVUSS

IMAGING PERFORMED BY

Rebecca Hamilton

HOSPITAL NAME

Bergen County
Veterinary Clinic

REFERRING VET

Dr. Santo

INVOICE

74337

DATE

4/9/26

Pancreas

The base and limbs of the **pancreas** were observed to be largely isoechoic to surrounding omental fat. Pancreatic duct and capsular contour were acceptably normal and parenchyma respected normal curvilinear patterns. No overt evidence of active inflammatory or neoplastic disease was noted.

Other

Rapid view of the heart revealed no evident pathology in the right auricle. Normal contractility and volumes of the heart.

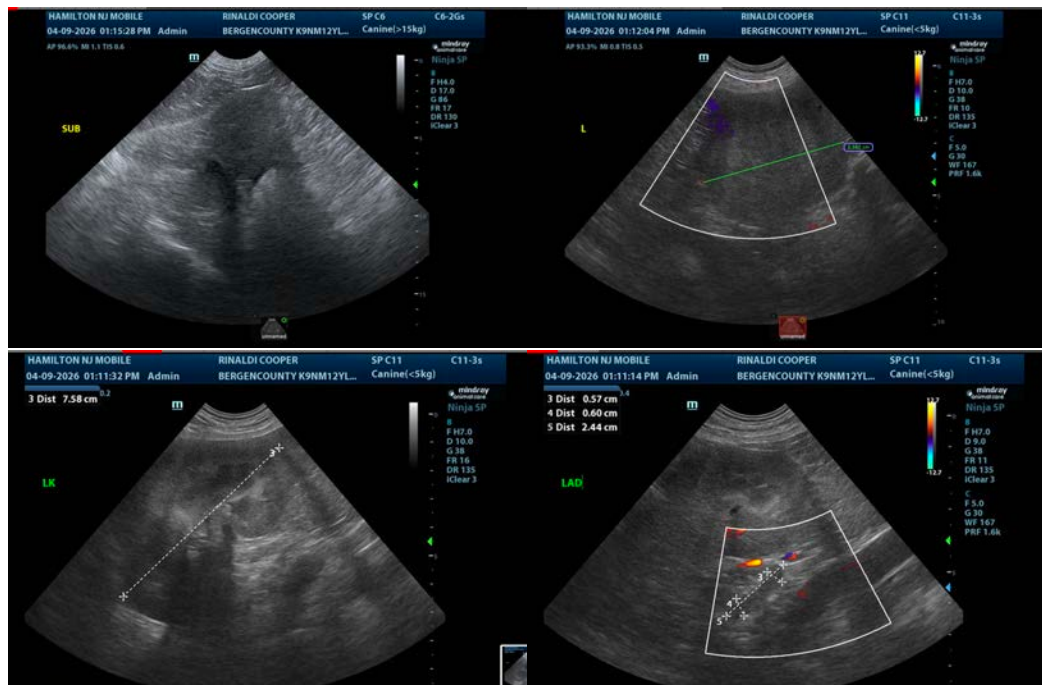
ULTRASONOGRAPHIC FINDINGS

- Splenic mass, appears isolated.
- Age related hepatic changes.

INTERPRETATION OF THE FINDINGS & FURTHER RECOMMENDATIONS

Chest radiographs followed by exploratory splenectomy with liver inspection and biopsy indicated. No contraindication to anesthetic procedure.

***Note that body tension impeded some visibility in this patient. Sedation recommended for any further imaging to reduce body tension.*





PATIENT

Cooper Rinaldi

SPECIES

Canine

BREED

Labrador Retriever

SEX

Neutered Male

AGE

12 Years

WEIGHT

96.6 lbs

INTERPRETED BY

Eric Lindquist, DMV,
 DABVP (CFM), Cert.
 IVUSS

IMAGING PERFORMED BY

Rebecca Hamilton

HOSPITAL NAME

Bergen County
 Veterinary Clinic

REFERRING VET

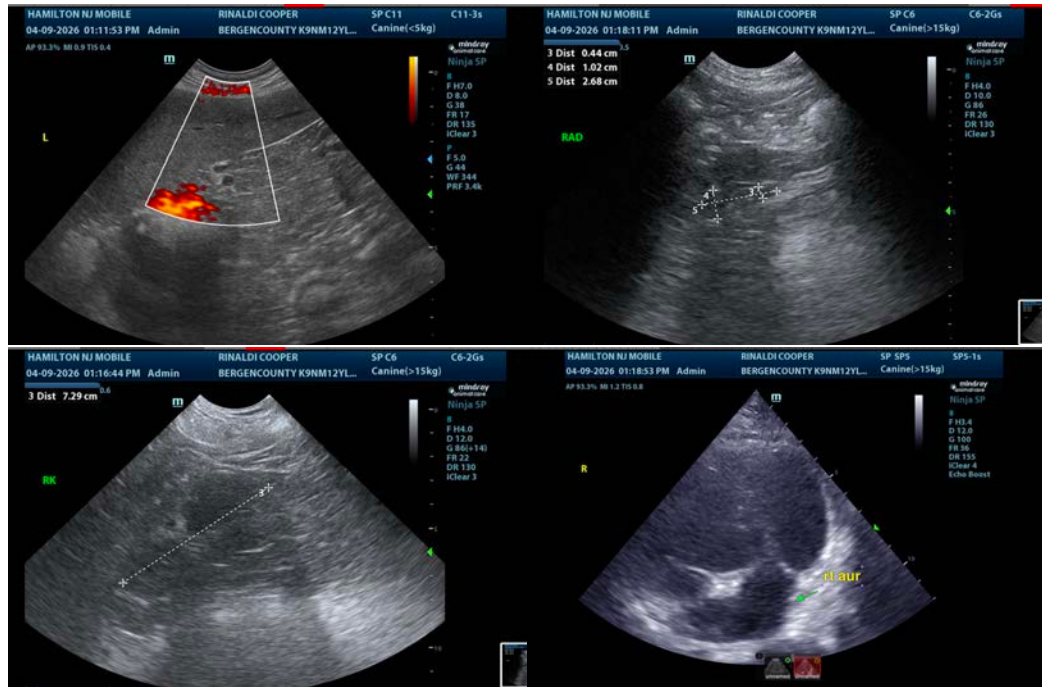
Dr. Santo

INVOICE

74337

DATE

4/9/26



The information and recommendations provided are based on the images presented by the referring veterinarian/sonographer. No evaluation can be communicated regarding pathology that was not visible in the image/video clips provided.

Thank you for this referral. If the clinical or image interpretation does not parallel your findings or if I can be of any further assistance please contact me.

Eric Lindquist, DMV, DABVP(CFM), Cert. IVUSS,
 CEO, Owner, Founder -- SonoPath.com
info@SonoPath.com