



## PATIENT

Charlie Fusco

## SPECIES

Canine

## BREED

Miniature Schnauzer

## SEX

Neutered male

## AGE

10 years

## WEIGHT

22.6 lbs

## INTERPRETED BY

Eric Lindquist, DMV  
DABVP, Cert. IVUSS

## IMAGING PERFORMED BY

Kathleen Laux

## HOSPITAL NAME

Rondout Valley VA

## REFERRING VET

Dr. Laux

## INVOICE

74336

## DATE

4/9/26

## PRESENTING CLINICAL SIGNS

History: 3-4 weeks ago felt a 3-4mm urethral thickening on rectal today feel about a 1cm mass effect to mid urethra on pelvic floor  
ALT 162 started hypothyroid medication, free T4 5.8

## ULTRASONOGRAPHIC EXAMINATION OF THE ABDOMEN

### Urinary System

The **urinary bladder**, trigone, and pelvic urethra presented normal thicknesses and normal tone. The ureters were not visible which is normal. No uroliths or sediment were visualized and anechoic urine was present. No evidence of inflammatory or neoplastic changes was noted. Ureteral papillae were normal.

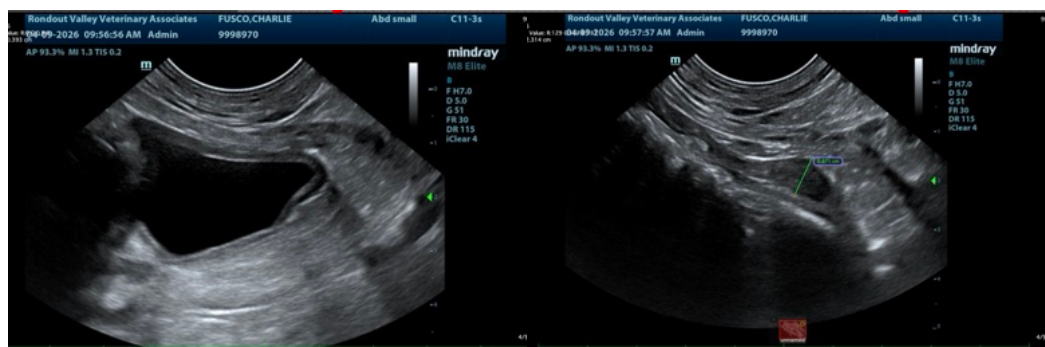
The prostate was uniform and measured 0.87 cm. The pre and post prostatic urethra were unremarkable.

## ULTRASONOGRAPHIC FINDINGS

Fairly normal prostate and urethra.

## INTERPRETATION OF THE FINDINGS & FURTHER RECOMMENDATIONS

I cannot rule out emerging carcinoma. Ultrasound-guided traumatic catheterization would be warranted. If any clinical signs are present or the structure is increasing in size.



The information and recommendations provided are based on the images presented by the referring veterinarian/sonographer. No evaluation can be communicated regarding pathology that was not visible in the image/video clips provided.



**PATIENT**

Charlie Fusco

**SPECIES**

Canine

**BREED**

Miniature Schnauzer

**SEX**

Neutered male

**AGE**

10 years

**WEIGHT**

22.6 lbs

**INTERPRETED BY**

Eric Lindquist, DMV  
DABVP, Cert. IVUSS

**IMAGING  
PERFORMED BY**

Kathleen Laux

**HOSPITAL NAME**

Rondout Valley VA

**REFERRING VET**

Dr. Laux

**INVOICE**

74336

**DATE**

4/9/26

Thank you for this referral. If the clinical or image interpretation does not parallel your findings or if I can be of any further assistance please contact me.

Eric Lindquist, DMV, DABVP (CFM), Cert. IVUSS, CEO of SonoPath.com

[info@SonoPath.com](mailto:info@SonoPath.com)