



PATIENT

Tula Nowak

SPECIES

Feline

BREED

Domestic Shorthair

SEX

Spayed Female

AGE

6 years

WEIGHT

3.8 kg

INTERPRETED BY

Eric Lindquist, DMV
DABVP, Cert. IVUSS

IMAGING PERFORMED BY

Dr. Callihan

HOSPITAL NAME

Animal Emergency

REFERRING VET

Dr. Kalsbeek/AEC

INVOICE

98172

DATE

4/8/22

PRESENTING CLINICAL SIGNS

History: Patient presents for: Was overweight and has been on weight loss diet since the end of January. Owner suddenly noticed that she has lost a lot of weight recently, but due to other cats in the house is not sure of appetite or urine production. Tula has also been vomiting. She has had a small amount of diarrhea in the past few days. Historically has always drank more water than other cats in the house. Indoor only, utd on vx. History of: obesity No known medical issues or sensitivities Medications: none Diet: Wellness weight loss food.

Abnormal PE/Chem/CBC/UA Results: PE: full feel to abdomen and thin topline, appearance weight loss/muscle wasting; icteric; Temp normal; HR 260 on presentation -Lab 17: CHEM:ALT 264 U/L (12-130), ALKP 859 U/L (14-111), GGT 7 U/L (0-4), TBIL 10.4 mg/dL (0-0.9) -Abdominal rads: hepatomegaly -Urinalysis: SG 1.050, KET 15 mg/dL, UBG 8 mg/dL, BIL 6 mg/dL, BLD 250 Ery/mcL, BC 2/HPF, Suspect presence of Cocci, Non-Squamous EPI 6-10/HPF, Suspect presence of non-hyaline casts, Bilirubin crystals 6-10/HPF -Coags: wnl

ULTRASONOGRAPHIC EXAMINATION OF THE ABDOMEN

Urinary System

The **urinary bladder**, trigone, and pelvic urethra presented normal thicknesses and normal tone. The ureters were not visible which is normal. A minor amount of debris was noted, yet this is normal for a cat. No evidence of inflammatory or neoplastic changes was noted. Ureteral papillae were normal.

The **kidneys** revealed normal size and structure, corticomedullary definition and ratio for this age. The cortices presented largely uniform texture with normal echogenic relationship to liver and spleen. Medullary structure differed distinctly from the cortex and no evidence of pelvic dilation was present. The capsules were acceptably uniform without significant irregularities. The right kidney measured 4.3 cm. The left kidney measured 3.87 cm.

Adrenal Glands

Both **adrenal glands** were visualized and recognized as having normal shape, size, position and echogenicity for this breed. The phrenic vasculature, glandular echogenicity and detail were unremarkable. Capsule, cortex, and medullary definition were normal for this age patient. The right adrenal gland measured 0.4 cm. The left adrenal gland measured 0.4 cm.

Spleen

The **spleen** in this patient was uniform, yet volume contracted. Hydration status should be assessed.

Liver

The **liver** parenchyma was uniformly hyperechoic to falciform fat without disruption of architecture. Hepatomegaly was noted and deviated the gastric axis caudally. No masses were noted. The gallbladder and common bile duct were unremarkable. There was no evidence of post hepatic obstruction. A trace amount of free fluid was noted between the liver and diaphragm.



PATIENT

Tula Nowak

Gastrointestinal

SPECIES

Feline

Examination of the **gastrointestinal tract** revealed a stomach and intestine free of stasis, of normal wall thickness, acceptable curvilinear mural detail, and peristaltic activity. Small and large intestine demonstrated normal luminal chyme and stool consistency respectively. No obstructive or overt infiltrative disease was noted. No associated abnormal lymphatic activity was noted.

BREED

Domestic Shorthair

Pancreas

SEX

Spayed Female

The base and limbs of the **pancreas** were observed to be largely isoechoic to surrounding omental fat. Pancreatic duct and capsular contour were acceptably normal and parenchyma respected normal curvilinear patterns. No overt evidence of active inflammatory or neoplastic disease was noted.

AGE

6 years

ULTRASONOGRAPHIC FINDINGS

Structurally unremarkable abdomen.

WEIGHT

3.8 kg

Hepatic lipidosis pattern.

Bladder debris, normal for a cat.

INTERPRETATION OF THE FINDINGS & FURTHER RECOMMENDATIONS

INTERPRETED BY

Eric Lindquist, DMV
DABVP, Cert. IVUSS

Urinalysis is recommended to assess for inflammatory sediment. Coagulation panel and 25-gauge FNA is recommended to ensure there is no significant underlying disease. Hepatic lipidosis protocol is warranted in the meantime.

IMAGING PERFORMED BY

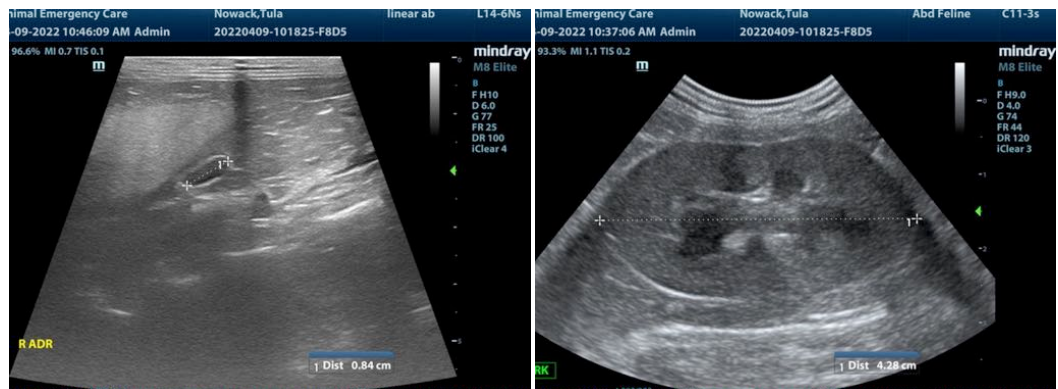
Dr. Callihan

HOSPITAL NAME

Animal Emergency

REFERRING VET

Dr. Kalsbeek/AEC



INVOICE

98172

DATE

4/8/22



PATIENT

Tula Nowak

SPECIES

Feline

BREED

Domestic Shorthair

SEX

Spayed Female

AGE

6 years

WEIGHT

3.8 kg

INTERPRETED BY

Eric Lindquist, DMV
DABVP, Cert. IVUSS

IMAGING PERFORMED BY

Dr. Callihan

HOSPITAL NAME

Animal Emergency

REFERRING VET

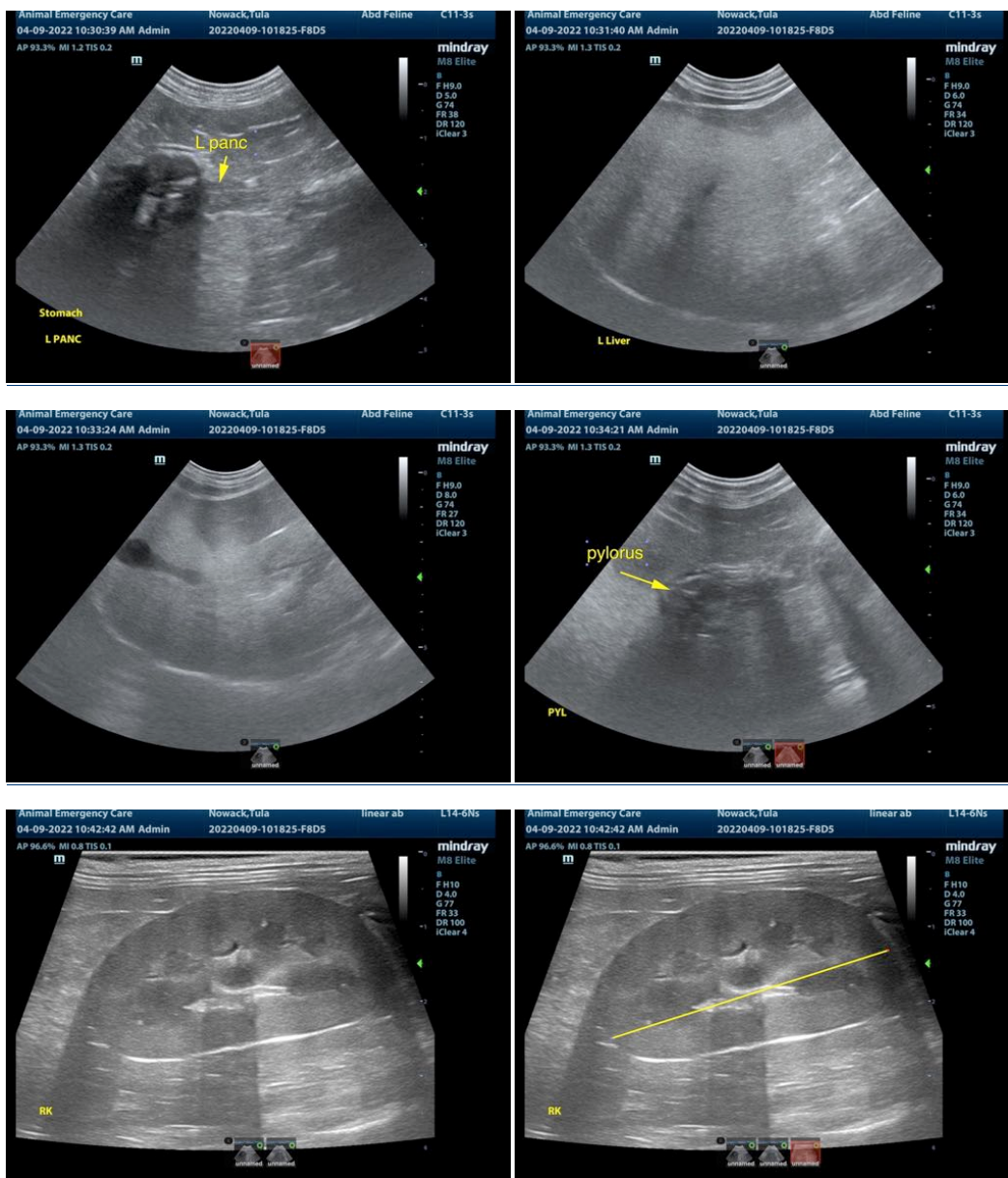
Dr. Kalsbeek/AEC

INVOICE

98172

DATE

4/8/22



The information and recommendations provided are based on the images presented by the referring veterinarian/sonographer. No evaluation can be communicated regarding pathology that was not visible in the image/video clips provided.

Thank you for this referral. If the clinical or image interpretation does not parallel your findings or if I can be of any further assistance please contact me.

Eric Lindquist, DMV, DABVP, Cert. IVUSS, CEO of SonoPath.com
info@SonoPath.com



PATIENT

Tula Nowak

SPECIES

Feline

BREED

Domestic Shorthair

SEX

Spayed Female

AGE

6 years

WEIGHT

3.8 kg

INTERPRETED BY

Eric Lindquist, DMV
DABVP, Cert. IVUSS

IMAGING PERFORMED BY

Dr. Callihan

HOSPITAL NAME

Animal Emergency

REFERRING VET


Dr. Kalsbeek/AEC

INVOICE

98172

DATE

4/8/22



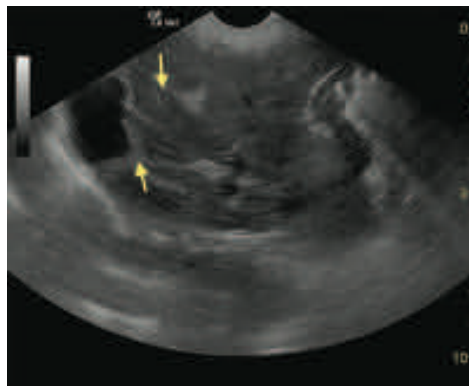
The following is an applicable excerpt from the *Curbside Guide to Diagnosis & Treatment of Sonographic Disease* offered by [SonoPath.com](http://sonopath.com) Lindquist, Frank, Lobetti, and Modler.

An essential quick guide for every general practitioner and sonographer.

<https://sonopath.com/products/curbside-guide-editing-due-release-12012015>

Feline Liver Disease & Treatment Recommendations

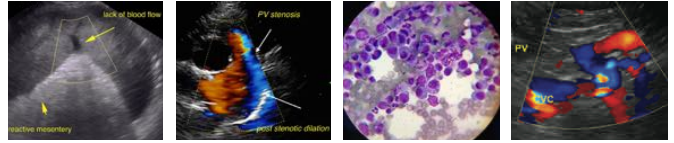
<http://www.sonopath.com/FelineLiverDisease>



Subxiphoidal short axis of the liver in a cat with nodular hyperplasia. Note the presence of multifocal hyper/isoechoic nodules throughout the hepatic parenchyma. This is a non specific finding consistent with chronicity that merits core biopsy to evaluate architectural pathology and rule out neoplasia as opposed to FNA that would assess only cells. Note the arrows that delineate an isoechoic nodule subtly deviating the gall bladder contour.

Description: Liver disease is a common clinical condition in cats; however, it can be subdivided into specific disease categories. Cats most often develop feline cholangitis, which is comprised of various forms of inflammatory liver disease or hepatic lipidosis; however, there are other disease processes, including neoplasia, infectious disease, and toxicities, that result in hepatic dysfunction. This chapter will focus predominantly on feline cholangitis and hepatic lipidosis; hepatic neoplasia is discussed in greater detail in a separate chapter.

1. Feline cholangitis complex is one of the most significant diseases in cats. The term “complex” embodies many different disease processes, each with its own signs and treatment protocols. The World Small Animal Veterinary Association (WSAVA) liver Standardization Group classifies feline cholangitis accordingly: neutrophilic cholangitis, which includes both acute and chronic neutrophilic cholangitis (these are likely extensions of the same disease process); lymphocytic cholangitis; and cholangitis associated with a liver fluke infection.



PATIENT	a) Acute neutrophilic cholangitis is a suppurative disease process of the liver and is most commonly seen in young to middle-aged cats. Acute cholangitis is almost always of bacterial origin, with enteric isolates being the most common culprits (these are thought to ascend from the biliary tree). Pancreatitis and inflammatory bowel disease (IBD) are associated disease processes. Histopathologically, this disease is represented by suppurative inflammation within the walls and lumen of the biliary ducts, and may extend into the portal triads and possibly into the hepatic parenchyma.
Tula Nowak	
SPECIES	
Feline	
BREED	b) Chronic neutrophilic cholangitis is either neutrophilic or lymphoplasmacytic, and arises from the acute form. Inflammation is centered around the portal region and includes lymphocytes, plasma cells, and neutrophils. Inflammation can also extend into the surrounding parenchyma and is sometimes noted within the lumen of the bile duct. Current research is investigating the role of <i>Bartonella</i> species in the development of chronic cholangitis; other postulated etiologies include a <i>Helicobacter</i> infection and immune-mediated processes. Biliary hyperplasia occurs secondary to the chronicity of the disease, and fibrosis and/or cirrhosis represent the end-stage manifestation of these foregoing disease processes. Cirrhosis is a rare condition in the cat because most cats either succumb or undergo successful treatment prior to this stage. Cats with chronic neutrophilic cholangitis often have chronic pancreatitis and IBD (triaditis). These other diseases may be responsible for the immune-mediated destruction of the liver that is commonly seen with the chronic form. The fact that the bile and pancreatic ducts are anatomically close to one another in cats may be the reason for coinfection and explain why the diseases occur in tandem.
Domestic Shorthair	
SEX	
Spayed Female	
AGE	
6 years	
WEIGHT	
3.8 kg	Severe lymphocytic cholangitis is defined as chronic inflammation of the biliary tract infiltrated by small lymphocytes. Cats with lymphocytic cholangitis are usually ill for months or years. This disease is more common in Europe than North America, and is manifested as a chronic inflammatory disease, which ultimately leads to fibrosis and cirrhosis. Chronic infections are thought to be the result of <i>Helicobacter pylori</i> infections and immune-mediated diseases. There is a greater predisposition in both Persian and younger cats to chronic forms.
INTERPRETED BY	
Eric Lindquist, DMV DABVP, Cert. IVUSS	
IMAGING PERFORMED BY	c) Lymphocytic portal hepatitis is characterized by mild lymphocytic inflammation around the portal areas, but no inflammation within the bile ducts or hepatic parenchyma. This is a common finding upon biopsy, and although it can be nonspecific and incidental, it is also thought to indicate a reactive hepatopathy secondary to extrahepatic disease.
Dr. Callihan	
HOSPITAL NAME	
Animal Emergency	
REFERRING VET	d) In tropical and subtropical geographic areas, cholangitis is associated with fluke infestation secondary to infection with <i>Platynosomum</i> spp. Cats become infected by ingesting the second intermediate host (reptiles and amphibians). The fluke infection results in cystic dilation and bile duct thickening as well as obstruction.
Dr. Kalsbeek/AEC	
INVOICE	2. Hepatic lipidosis (HL) is one of the most common causes of hepatic disease in cats. It is defined as an accumulation of lipid within the cytoplasm of the hepatocyte. This can be idiopathic (primary) or can occur secondary to other diseases, and results in anorexia and weight loss. The pathophysiology is multifactorial and due to dysregulation of lipid metabolism in a catabolic state, which leads to excess accumulation of intracellular lipid within the hepatocyte.
98172	
DATE	Other common causes of liver enzyme elevation in cats include hepatocellular thyrotoxicosis, infectious diseases (e.g. <i>Toxoplasma</i> and FIP), and primary and metastatic neoplasia. In hepatic toxicosis, thyroid
4/8/22	



PATIENT

Tula Nowak

hormones have a direct toxic effect on liver cells and stimulate increased liver enzyme activity. Moreover, increased intestinal motility secondary to hyperthyroidism can cause increased oxygen utilization and thus hepatic hypoxia, which ultimately leads to hepatic dysfunction. Acute cholangitis cannot be fully ruled out without conducting a biopsy. Owner (and patient) compliance with methimazole should be evaluated. The methimazole dose may need to be increased or other treatment modalities explored, including radioactive iodine, thyroidectomy, and/or dietary therapy with restricted iodine, such as the therapeutic diet, Hill's® y/d®. It should be noted that methimazole can also cause a drug-induced toxicosis and that this can also result in liver enzyme elevation.

SPECIES

Feline

BREED

Domestic Shorthair

Clinical signs:

SEX

Spayed Female

Cholangitis: Because of the acute suppurative nature of acute neutrophilic cholangitis, clinical signs commonly include pyrexia and jaundice, accompanied by vomiting, diarrhea, and lethargy. Of the four main complex types discussed above, acute cholangitis patients normally present as the most severely ill. A chemistry panel often reveals a moderate increase in ALT, ALP, GGT, bilirubin, and bile acids, while a CBC commonly shows an elevated white blood cell count (WBC) with or without a left shift.

AGE

6 years

Cats suffering from the remaining types of feline cholangitis normally display less severe signs, but have likely been sick for a longer period of time. Those with chronic neutrophilic cholangitis can have intermittent episodes of jaundice and vomiting, which are cyclic and self-resolving. Weight loss, anorexia, and lethargy are common, and one typically observes elevations in ALP, GGT, bilirubin, and bile acids. The degree of elevation in ALT and AST is variable.

WEIGHT

3.8 kg

INTERPRETED BY

Eric Lindquist, DMV
DABVP, Cert. IVUS

Patients with severe lymphocytic cholangitis exhibit weight loss and anorexia; however, because it is a slow-moving, progressive disease, signs may be chronic and mild. Liver enzyme elevations are generally mild until the chronic phase when icterus occurs as well as ascites. Hypergammaglobulinemia is also a prominent feature of this disease.

IMAGING PERFORMED BY

Dr. Callihan

Cats with fluke infestations are either asymptomatic or systemically ill with pyrexia, vomiting, anorexia, icterus, and bile duct obstruction. A CBC may indicate marked liver enzyme elevations as well as an eosinophilia. Cats with lymphocytic portal hepatitis are asymptomatic and do not demonstrate laboratory abnormalities.

HOSPITAL NAME

Animal Emergency

REFERRING VET

Dr. Kalsbeek/AEC

Hepatic lipidosis: The most common clinical signs are anorexia, vomiting, diarrhea, icterus, lethargy, depression, ptialism, and weight loss. Since HL occurs in the face of so many other diseases, clinical signs may vary and be due, in part, to the underlying disease process. Likewise, lab work abnormalities can also vary, depending on concurrent disease processes. Hepatic encephalopathy may ensue, resulting in severe weakness, depression, and ptialism. Common CBC abnormalities include a nonregenerative anemia, stress leucogram, poikilocytosis, and the presence of Heinz bodies. On the serum chemistry, an elevation in ALP is disproportionate to GGT levels, which are usually within normal limits. Serum ALT is variably increased, but typically of a lower magnitude than that of ALP. Bilirubin is increased due to intrahepatic cholestasis. Bile acids are increased, but are a superfluous indicator in the face of hyperbilirubinemia. The BUN and albumin may be normal or subnormal. Coagulation abnormalities occur in cats with HL due to vitamin K deficiency, which is a result of malabsorption in the

INVOICE

98172

DATE

4/8/22



PATIENT	intestines and decreased production of coagulation factors in the liver due to severe hepatic dysfunction.
Tula Nowak	
SPECIES	Cats with thyroid toxicosis mainly exhibit clinical signs of hyperthyroidism. The chief abnormalities on serum chemistry are a mild to moderate elevation in ALT and elevated T4 levels. In the event of methimazole toxicity, the ALT can also be mild to moderately elevated. Cats with hepatic neoplasia may also demonstrate similar signs to other forms of hepatic disease, display elevations in ALT, ALP, GGT, and AST, and exhibit a leukocytosis and possibly anemia of chronic disease. This condition is discussed in greater detail in the chapter on "Hepatic Neoplasia."
Feline	
BREED	
Domestic Shorthair	
SEX	Diagnosics: Ultrasound and interventional ultrasound are important means of definitively diagnosing hepatic disease in cats. An ultrasound-guided core biopsy of the liver can be performed to acquire both histopathology and aerobic/anaerobic cultures. Alternatively, a larger tissue biopsy can be obtained via laparoscopy or laparotomy. In the event that a laparotomy or laparoscopy is performed, biopsies of the small intestine and pancreas should be obtained. One will also often encounter triaditis. Ultrasound-guided centesis of the gallbladder can be done to collect bile for culture and is preferred over hepatic parenchymal cultures. Ultrasound additionally allows for visualization of choleliths and obstruction to bile flow; it also helps determine whether surgical intervention is required. In the case of HL, the sonographic appearance presents as a uniform, diffuse, dense hyperechoic parenchyma that is hyperechoic to falciform fat and spleen; however, a primary underlying disease may also be present, such as cholangitis or lymphoma. In cats with suspected HL, fine needle aspiration (FNA) is the safest way to rule this out and to evaluate for lymphoma, as cytology is especially useful in the diagnosis of both these diseases. Lipidotic livers are friable and hence bleeding can occur as a complication of biopsy due to poor tissue integrity, lack of tissue hemostasis, and possibly compromised systemic hemostasis due to poor hepatic function. Cholangitis and neoplasia can be suspected on cytology, but a hepatic biopsy is preferred in order to define architecture, inflammatory infiltrate, and fibrosis. The clinician must weigh the risks and benefits of obtaining a biopsy in patients that may have a concurrent disease or are unresponsive to conventional therapy for HL. Pretreatment with vitamin K1 and aggressive supportive care may aid in stabilizing a patient for biopsy.
Spayed Female	
AGE	
6 years	
WEIGHT	
3.8 kg	
INTERPRETED BY	
Eric Lindquist, DMV DABVP, Cert. IVUSS	
IMAGING PERFORMED BY	
Dr. Callihan	
HOSPITAL NAME	Cholangitis associated with liver flukes is uncommon in North America, but if the patient is in a tropical or subtropical location, the diagnosis is either obtained by fecal examination or liver biopsy, which permits observation of the flukes and/or their eggs within the bile ducts.
Animal Emergency	
REFERRING VET	Treatment: The following medications are suggested in keeping with general guidelines for treatment for feline hepatic disease; however, each patient should be assessed and treated as an individual, and management should be tailored according to a specific diagnosis.
Dr. Kalsbeek/AEC	
INVOICE	Disease-specific recommendations:
98172	1. Feline cholangitis complex
DATE	
4/8/22	



PATIENT

a) Acute neutrophilic cholangitis and chronic neutrophilic cholangitis:

Tula Nowak

SPECIES

Feline

BREED

Domestic Shorthair

- Antibiotics: Administration of antibiotics should ideally be based on culture and sensitivity. If a culture is not available, one may treat with broad-spectrum antibiotics, such as amoxicillin (10-20 mg/kg PO BID), amoxicillin clavulanic acid (10 mg/kg PO BID or 62.5 mg PO BID), a cephalosporin, such as cefadroxil (20 mg/kg PO BID), or enrofloxacin (5 mg/kg PO once daily). Antibiotics can be used for 4-8 weeks. Metronidazole (11-22 mg/kg PO BID) can be given as an anti-inflammatory medication; it also has an anaerobic spectrum. Metronidazole also decreases ammonia produced by intestinal microbes (administer at 7.5 mg/kg PO BID-TID in cases of hepatic encephalopathy).

SEX

Spayed Female

b) Chronic neutrophilic cholangitis (lymphoplasmacytic inflammation):

AGE

6 years

- An anti-inflammatory medication should be given when biopsy reveals that there has been significant infiltration with lymphocytes and/or plasma cells, or if the patient is not responding to antibiotic medication alone (in the absence of a biopsy).
- Prednisolone should be given at 1-2 mg/kg/day. Start at a higher dose, and wean over time to every other day in decreasing dosages every 2-4 weeks following the resolution of signs. Additional immunosuppressant medications are not typically used in cats for this disease.

WEIGHT

3.8 kg

c) Severe lymphocytic cholangitis:

INTERPRETED BY

Eric Lindquist, DMV
DABVP, Cert. IVUSS

- Prednisolone should be dosed at 1-2 mg/kg/day; however, it remains controversial as to whether prednisolone is in fact effective in the course of this disease.
- Ursodiol (Actigall): 10-15 mg/kg PO Q24hr.

IMAGING PERFORMED BY

Dr. Callihan

d) Liver fluke infection:

HOSPITAL NAME

Animal Emergency

- Praziquantel: Give 20-30 mg/kg PO Q24hr for 3 days.

REFERRING VET

Dr. Kalsbeek/AEC

2. Hepatic Lipidosis

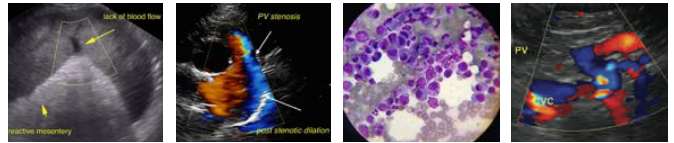
INVOICE

98172

- Hyperalimentation is crucial in the management of HL; it may also be necessary in the management of other hepatic diseases in cats that are not eating so as to prevent hepatic lipidosis as a complication. In order to determine the caloric needs of the patient, calculate the basal energy requirement using the formula $BER = 70 \times BW^{0.75}$. Multiply the BER by an illness energy requirement factor (1.25-1.4 in cats) and then select a therapeutic recovery diet with enhanced protein and fat levels, such as Hill's® a/d®, CliniCare® Liquid Diet (Abbott Animal Health), Royal Canin® Recovery RS™, or Iams® Maximum-Calorie™. Feed small, frequent meals through an esophagostomy tube (E tube), percutaneous endoscopic

DATE

4/8/22



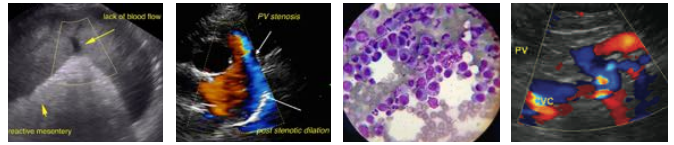
PATIENT	gastrostomy tube (PEG), or nasoesophageal tube (NE) tube. Give slowly over 15-30 minutes or trickle feed as a CRI. In cats that have been anorexic for a prolonged period of time, the amount of food should be gradually increased over 3 days' time. The food should be made into a slurry and warmed, and the total amount of food divided into 4-6 feedings per day. Flush the feeding tube with 5-15 ml warm water. Pretreatment with cisapride (1.25-2.5 mg/cat PO or 0.1-0.5 mg/kg PO BID-TID) or metoclopramide (0.2-0.4 mg/kg PO or SC Q8hr) can prove helpful to improve gastric emptying; dosing should occur 30 minutes before feeding.
Tula Nowak	
SPECIES	
Feline	
BREED	
Domestic Shorthair	
SEX	
Spayed Female	
AGE	
6 years	
WEIGHT	
3.8 kg	
INTERPRETED BY	
Eric Lindquist, DMV DABVP, Cert. IVUS	
IMAGING PERFORMED BY	
Dr. Callihan	
HOSPITAL NAME	
Animal Emergency	
REFERRING VET	
Dr. Kalsbeek/AEC	
INVOICE	
98172	
DATE	
4/8/22	

3. Hepatic Encephalopathy:

- Lactulose: Give 0.5 ml/kg PO BID-TID to soften the stool. Lactulose helps manage hepatic encephalopathy by combining with ammonium in the GI tract and thus decreasing circulating ammonia levels. It can also be mixed into the slurry during feeding. Lactulose can also be given as a retention enema in an encephalopathic crisis.
- Metronidazole or neomycin: Give metronidazole at 7.5 mg/kg PO BID-TID. This is an antimicrobial, which reduces bacterial counts and reduces ammonia production in the colon. Alternatively, administer neomycin at 20 mg/kg PO BID-TID.
- L-Carnitine: Give 50-100 mg/kg PO Q24hr. Normally synthesized by the liver, L-carnitine enhances ammonia elimination and is indicated in cases of hepatic encephalopathy and lipidosis. Carnitine must be in the L-form.
- Diet: A low-protein diet with high amounts of biologically available protein is recommended in encephalopathic patients to reduce the nitrogen load from the breakdown of amino acids.

General treatment recommendations for cats with either feline cholangitis complex or hepatic lipidosis:

- IV Fluids: Fluid therapy is integral, especially in cats with severe liver disease as they are often inappetant and dehydrated. In the face of hepatic failure, avoid Lactated Ringer's solution (LRS) as lactate is metabolized by the liver. Monitor electrolytes closely. Add potassium in the form of potassium chloride (KCL); 20 mEq/L is a general starting point, but higher doses may be needed in the face of severe hypokalemia (maximum infusion rate is 0.5 mEq/kg/hr). Correct concurrent hypomagnesemia with magnesium sulfate or magnesium chloride at 0.75-1 mEq/kg/day given as a CRI for one day, and then reduce it to 0.3-0.5 mEq/kg/day. Monitor serum phosphorus levels and supplement as needed. Hypophosphatemia can occur following the reinstatement of feeding, especially in previously anorexic patients (re-feeding syndrome). Supplement phosphorus at 0.01-0.06 mmol/kg/hr using potassium phosphate or sodium phosphate.
- Vitamin B1 complex (thiamine) can also be added to the fluids at 1-2ml/liter. Note: Protect the fluid bag from light as the vitamins degrade when exposed to light.
- Vitamin B12 (cyanocobalamin) can be administered at 250 ug SC or IM weekly as needed in



PATIENT

Tula Nowak

SPECIES

Feline

BREED

Domestic Shorthair

SEX

Spayed Female

AGE

6 years

WEIGHT

3.8 kg

INTERPRETED BY

Eric Lindquist, DMV
DABVP, Cert. IVUSS

IMAGING PERFORMED BY

Dr. Callihan

HOSPITAL NAME

Animal Emergency

REFERRING VET

Dr. Kalsbeek/AEC

INVOICE

98172

DATE

4/8/22

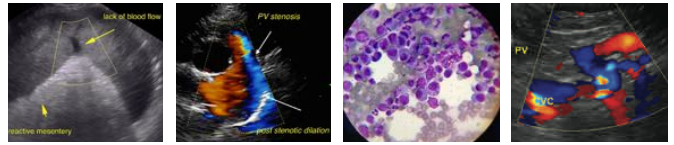
cases of HL or in cats with primary gastrointestinal disease.

- Famotidine can be given 0.5 mg/kg PO or IV once to twice daily as an antacid.
- Ursodiol (Actigall): Give 10-15 mg/kg PO Q24hr, with food, to stimulate bile secretion and flow, and decrease cholestasis. It has immunomodulatory, anti-fibrotic, and choleric effects and anti-copper storage benefits; it also stabilizes mitochondrial function. Ursodiol can be compounded into a liquid formulation for cats.
- S-adenosylmethionine (SAME): Give 90 mg/cat PO on an empty stomach (1-2 hours before feeding), or a loading dose of 35-60 mg/kg once to twice daily and a maintenance dose of 20 mg/kg PO Q24hr. SAME replenishes glutathione and aids in cellular detoxification. It is also an anti-inflammatory and antioxidant.
- Antiemetics: these are used to decrease the frequency of vomiting and therefore enable enteral nutrition. A common antiemetic, metoclopramide (0.2-0.5 mg/kg SC TID 30 min before feeding or 0.01-0.02 mg/kg/hr as a CRI) has the beneficial effect of concurrently improving gastric emptying. Alternative anti-emetics include: maropitant citrate (Cerenia), which should be administered at 1 mg/kg subcutaneously once daily for up to 5 days; odansetron (Zofran), which can be dosed at 0.1 mg/kg PO once to twice daily or 0.1-0.3 mg/kg IV BID-TID; or dolasetron (Anzemet), which can be administered at 0.5 mg/kg PO, SC, or IV Q24hr. Silybin-phosphatidylcholine (Marin) (5 mg/kg PO Q24hr) is yet another alternative; however, to date there are no evidenced-based studies in cats on the effects of milk thistle. Nevertheless, it is suggested that it acts as an antioxidant and free radical scavenger, decreases hepatotoxin binding, improves glutathione concentrations, aids in iron chelating, and promotes choleresis.
- Vitamin E: Give 10-15 IU/kg/day PO (100-400 IU) in a water-soluble form twice daily.

Initially, in the face of hepatic failure and severe icterus, patients are hospitalized and monitored closely. Once stable, the patient can be discharged with a feeding tube if oral intake is not yet sufficient. Weight, appetite, and blood work must be carefully assessed. Specifically, ALT, SAP, serum protein, and serum albumin should initially be evaluated every 2 weeks, then monthly for the first 6 months, and subsequently every 4-6 months. A patient's response to therapy is typically assessed by their clinical condition and laboratory work; however, repeated biopsy or FNA may be necessary if the clinical response proves to be unsatisfactory.

Common drugs to avoid when treating hepatic disease: Halothane; sulphonamides; diazepam; azole antifungals; phenobarbital; tetracyclines; erythromycin or enrofloxacin if combined with theophylline or cisapride; and cimetidine if combined with theophylline, metronidazole, or chloramphenicol. Sedate with caution if lipidosis is present. If anesthesia is necessary for sampling or placing a feeding tube, induction with propofol should be considered with an inhalant, such as sevoflurane or isoflurane.

Conclusion: There are many pathological processes that can result in hepatic disease in the feline patient. Ideally, sampling is performed to obtain a definitive diagnosis, which allows for specific guidance with regards to therapy and prognosis. Adequate nutrition or hyperalimentation is critical for hepatic support when treating HL or preventing it from occurring as a secondary complication. Intensive care and monitoring are also key components of therapy in critically ill icteric cats.



PATIENT

Tula Nowak

SPECIES

Feline

BREED

Domestic Shorthair

SEX

Spayed Female

AGE

6 years

WEIGHT

3.8 kg

INTERPRETED BY

Eric Lindquist, DMV
DABVP, Cert. IVUSS

IMAGING PERFORMED BY

Dr. Callihan

HOSPITAL NAME

Animal Emergency

REFERRING VET

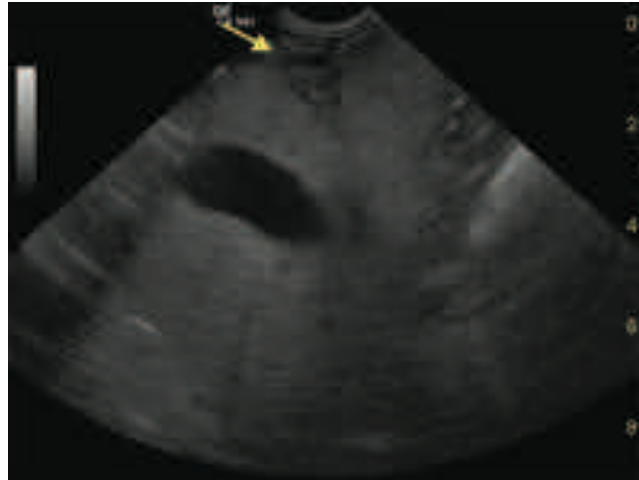Dr. Kalsbeek/AEC

INVOICE

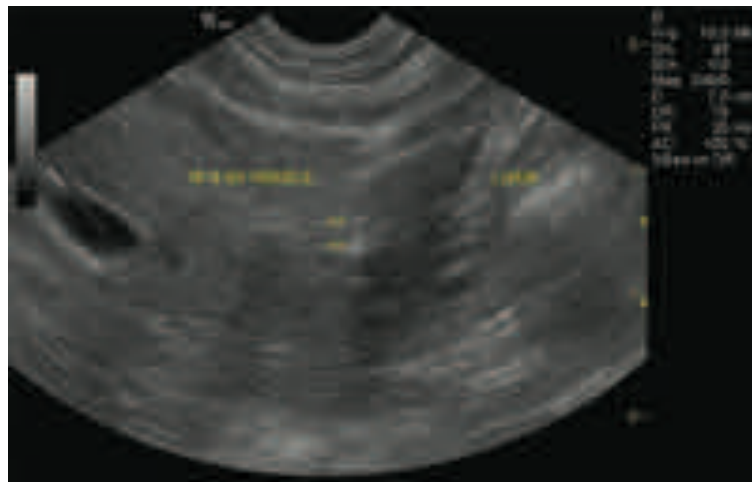98172

DATE

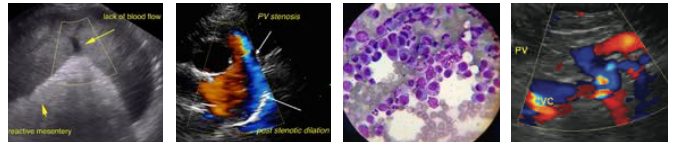
4/8/22



Subxiphoidal long axis of the liver in a cat with hepatic lipidosis. Note the generalized increase in parenchymal echogenicity that is hyperechoic to falciform fat (arrow). The regular coarse echotexture and the visibility of the portal markings is lost. Differential diagnoses also include vacuolar hepatopathy and diffuse neoplastic infiltrate. Final diagnosis in diffuse liver disease requires sampling by FNA to evaluate cells, core biopsy to evaluate architecture and transitional (inflammatory to neoplastic) pathology.



Subxiphoidal short axis of a cat liver during ultrasound guided biopsy. The core biopsy needle is seen as echogenic line (arrowheads) within the liver parenchyma. The sonographic presentation is unremarkable in this case but the liver enzyme profile and clinical presentation indicated liver disease. Therefore, core biopsy was appropriate. At times, the clinical sonographer must sample the liver to assess clinical significance despite unremarkable sonographic findings during acute or aspecific disease. Histopathological dx: Multiple myeloma.



PATIENT

Tula Nowak

SPECIES

Feline

BREED

Domestic Shorthair

SEX

Spayed Female

AGE

6 years

WEIGHT

3.8 kg

INTERPRETED BY

Eric Lindquist, DMV
DABVP, Cert. IVUSS

IMAGING PERFORMED BY

Dr. Callihan

HOSPITAL NAME

Animal Emergency

REFERRING VET

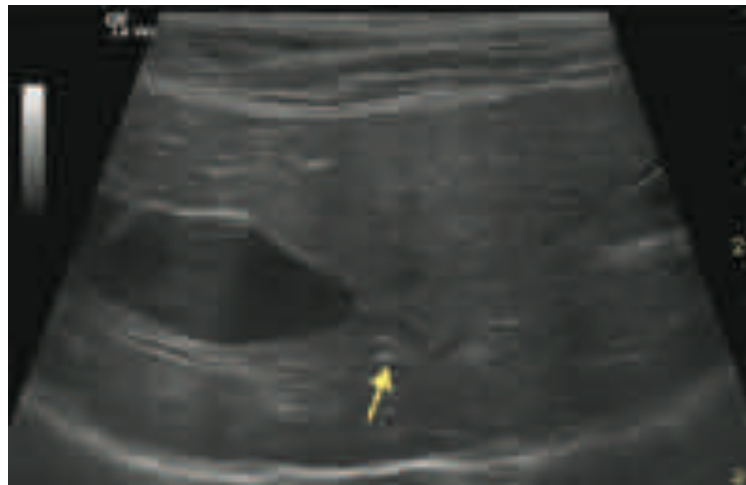Dr. Kalsbeek/AEC

INVOICE

98172

DATE

4/8/22



Subxiphoidal short axis of the liver in a cat with hepatitis and significant liver enzyme elevation. The visibility of the portal markings is slightly increased (arrow). The parenchymal echotexture and echogenicity is preserved. Note the ultrasonographic changes may be very subtle despite severe inflammatory infiltration. US-guided FNA: lymphoplasmacytic cholangitis.

References:

Armstrong PJ, Blanchard G. Hepatic lipidosis in cats. *Vet Clin North Am Small Anim Pract* 2009;39(3):599-616.

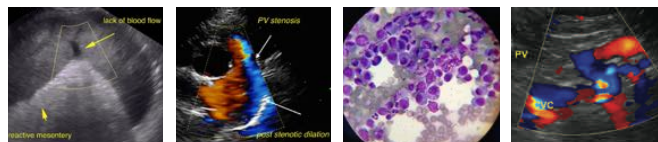
Brian PH, Barrs VR, Martin P, et al. Feline cholecystitis and acute neutrophilic cholangitis: clinical findings, bacterial isolates and response to treatment in six cases. *J Feline Med Surg* 2006;8(2):91-103.

Brenner K, KuKanich KS, Smee NM. Refeeding syndrome in cat with hepatic lipidosis. *J Feline Med Surg* 2011;18(8):614-17.

Carreira VS, Vieira RF, Machado GF, Luvizotto MC. Feline cholangitis, cholangiohepatitis complex secondary to *Platynosomum fastosum* infection in a cat. *Rev Bras Parasitol Vet* 2008;17 Suppl 1:184-87.

Center S. Feline hepatic lipidosis is a common liver disorder. *Feline Health Topics* 1989;4(3):1-6.

Center SA, Baldwin BH, Dillingham S, et al. Diagnostic value of serum gamma-glutamyl transferase and alkaline phosphatase activities in hepatobiliary disease in the cat. *J Am Vet Med Assoc* 1986;188:507-10.



PATIENT	Davenport D. Antimicrobial therapy for gastrointestinal, pancreatic, and hepatic disorders . <i>Probl Vet Med</i> 1990;2(2):374-93.
Tula Nowak	
SPECIES	Gagne JM, Armstrong PJ, Weiss DJ, et al. Clinical features of inflammatory liver diseases in cats: 41 cases (1983-103). <i>J AM Vet Med Assoc</i> 1999;214:513.
Feline	
BREED	Greiter-Wilke A, Scanziani E, Soldati S, et al. Association of <i>Helicobacter</i> with cholangiohepatitis in cats. <i>J Vet Intern Med</i> 2006;20(4):822-27.
Domestic Shorthair	
SEX	Holan KM. Feline Hepatic Lipidosis. In: Bonagura JD, Twedt DC, eds: <i>Current Veterinary Therapy XIV</i> . St. Louis, MI: Saunders Elsevier; 2009:570-75.
Spayed Female	
AGE	Kordick DI, Brown TT, Shin K, Breitschwedt EB. Clinical and pathologic evaluation of chronic <i>Bartonella henselae</i> or <i>Bartonella clarridgeiae</i> infection in cats. <i>J Clin Microbiol</i> 1999;37(5):1536-47.
6 years	
WEIGHT	Mathews KA. Nutritional Support. In: Mathews KA, ed: <i>Veterinary Emergency and Critical Care</i> . Guelph, ON: Lifelearn Inc, 1996:19.1-19.29.
3.8 kg	
INTERPRETED BY	Otte CM, Penning LC, Rothuizen J, Favier RP. Retrospective comparison of prednisolone and ursodeoxycholic acid for the treatment of feline lymphocytic cholangitis. <i>Vet J</i> 2013;195(2):205-9.
Eric Lindquist, DMV DABVP, Cert. IVUSS	
IMAGING PERFORMED BY	Tams T. Management of liver disease in dogs and cats. <i>Mod Vet Pract</i> 1984;65(2):107-14.
Dr. Callihan	
HOSPITAL NAME	Twedt DC, Armstrong PJ. Feline inflammatory liver disease. In: Bonagura JD, Twedt DC, eds: <i>Current Veterinary Therapy XIV</i> . St. Louis, MI: Saunders Elsevier; 2009:576-581.
Animal Emergency	
REFERRING VET	van den Ingh TSGAM, Cullen JM, Twedt DC, et al. Morphological classification of biliary disorders of the canine and feline liver. In: Rothuizen J et al, eds: <i>WSAVA Standards for Clinical and Histological Diagnosis of Canine and Feline Liver diseases</i> . Spain: Saunders Elsevier; 2006:61-78.
Dr. Kalsbeek/AEC	
INVOICE	Webster C, Cooper J. Therapeutic use of cytoprotective agents in canine and feline hepatobiliary disease . <i>Vet Clin North Am Small Anim Pract</i> 2009; 39(3):631-52
98172	
DATE	Weiss D, Armstrong P, Gagne J. Inflammatory liver disease . <i>Semin Vet Med Surg (Small Anim)</i> 1997;12(1):22-27.
4/8/22	