



PATIENT

Stumpy Morton

SPECIES

Feline

BREED

DSH

SEX

Neutered Male

AGE

3 Years 7 Months

WEIGHT

12.5 pounds

INTERPRETED BY

Eric Lindquist, DMV,
DABVP(CFM), Cert.
IVUSS

IMAGING PERFORMED BY

Dr. Leon Anderson
DVM

HOSPITAL NAME

Elizabeth Animal
Hospital

REFERRING VET

Dr. Leon Anderson
DVM

INVOICE

14972

DATE

04/08/26

PRESENTING CLINICAL SIGNS

Cystotomy and removal of ammonium urate stones for the urinary bladder on 3/7/26. Running down possible shunt or other issue causing their formation.

Abnormal PE/Chem/CBC/UA Results: Follow-up Labs yesterday: NSAID Panel: No azotemia and AST 85 U/L. Bile Acids Normal: pre = 2.5 umol/L, post 1.2 umol/L PE: WNL

ULTRASONOGRAPHIC EXAMINATION OF THE ABDOMEN

Urinary System

The **urinary bladder**, trigone, and pelvic urethra to a depth of 1.0 cm presented normal thicknesses and normal tone. The ureters were not visible which is normal. No uroliths or sediment were visualized, and anechoic urine was present. No evidence of inflammatory or neoplastic changes were noted. Ureteral papillae were normal.

The **kidneys** revealed normal size and structure, corticomedullary definition and ratio for this age. The cortices presented largely uniform texture with normal echogenic relationship to liver and spleen. Medullary structure differed distinctly from the cortex and no evidence of pelvic dilation was present. The capsules were acceptably uniform without significant irregularities. The left kidney measured 4.21 cm in length. The right kidney measured 4.05 cm in length.

Adrenal Glands

The **left adrenal gland** was visualized and recognized as having normal shape, size, position and echogenicity for this breed. The phrenic vasculature, glandular echogenicity and detail were unremarkable. Capsule, cortex, and medullary definition were normal for this age patient. The left adrenal gland measured 0.42 cm width.

The **right adrenal gland** was not visualized.

Spleen

The **spleen** presented a smooth homogeneous parenchyma hyperechoic to liver and renal cortical parenchyma. The capsule was smooth without noticeable expansion or deviation from within the spleen or adjacent pathology. The splenic vasculature demonstrated normal volume without signs of congestion or thrombosis. No sonographic evidence of acute or chronic inflammatory, neoplastic, or infarctual changes were noted.

Liver

The **liver** images submitted revealed subjectively normal liver size, contour, and structure. Parenchymal echogenicity was naturally coarse and hypoechoic to the spleen. Vascular and biliary tracts were of normal volume with no evidence of congestion. The gallbladder presented acceptably thin walls with primarily anechoic content. The cystic and common bile ducts were normal. No pathological hepatic lymphadenopathy was evident. No overt structural evidence of inflammatory, infiltrative or regenerative pathology was evident. No evidence of portosystemic shunting. The portal vein measured 0.60 cm. The vena cava measured 0.50 cm.

Gastrointestinal



PATIENT

Stumpy Morton

SPECIES

Feline

BREED

DSH

SEX

Neutered Male

AGE

3 Years 7 Months

WEIGHT

12.5 pounds

INTERPRETED BY

Eric Lindquist, DMV,
DABVP(CFM), Cert.
IVUSS

IMAGING PERFORMED BY

Dr. Leon Anderson
DVM

HOSPITAL NAME

Elizabeth Animal
Hospital

REFERRING VET

Dr. Leon Anderson
DVM

INVOICE

14972

DATE

04/08/26

Examination of the **gastrointestinal tract** revealed a stomach and intestine free of stasis, of normal wall thickness, acceptable curvilinear mural detail, and peristaltic activity. Small and large intestine demonstrated normal luminal chyme and stool consistency respectively. No obstructive or overt infiltrative disease was noted. No associated abnormal lymphatic activity was noted.

Pancreas

The base and limbs of the **pancreas** were observed to be largely isoechoic to surrounding omental fat. Pancreatic duct and capsular contour were acceptably normal and parenchyma respected normal curvilinear patterns. No overt evidence of active inflammatory or neoplastic disease was noted.

ULTRASONOGRAPHIC FINDINGS

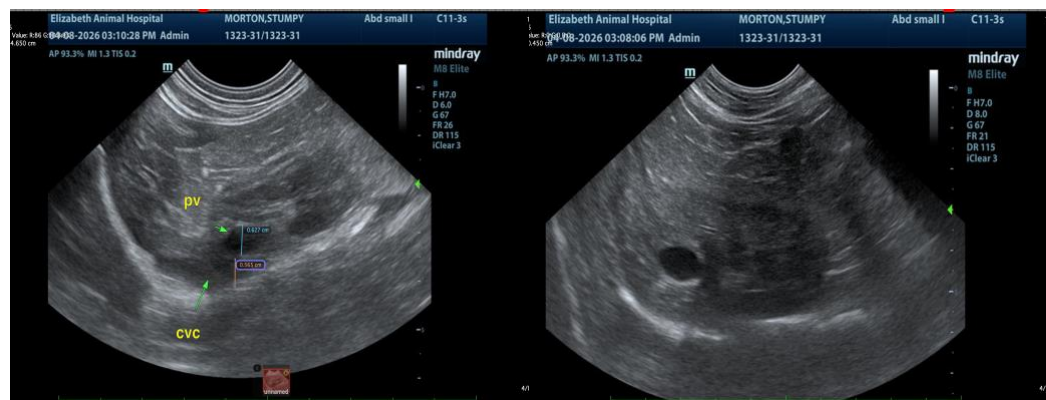
- Structurally unremarkable abdomen. No evidence of portosystemic shunting or active urolithiasis.

INTERPRETATION OF THE FINDINGS & FURTHER RECOMMENDATIONS

Given the normal bile acids, the possibility of shunting is unlikely.

Internal medicine consult can be utilized through SonoPath.com. You can select the internal medicine drop down at <http://spa.sonopath.com/>.

One of the world's top internists & SonoPath associate Dr. Remo Lobetti BVSc, MMedVet, PhD, DECVIM can evaluate your case through SonoPath. <https://sonopath.com/resources/sonopath-services/internal-medicine-teleconsultation-services>





PATIENT

Stumpy Morton

SPECIES

Feline

BREED

DSH

SEX

Neutered Male

AGE

3 Years 7 Months

WEIGHT

12.5 pounds

INTERPRETED BY

Eric Lindquist, DMV,
DABVP(CFM), Cert.
IVUSS

**IMAGING
PERFORMED BY**

Dr. Leon Anderson
DVM

HOSPITAL NAME

Elizabeth Animal
Hospital

REFERRING VET

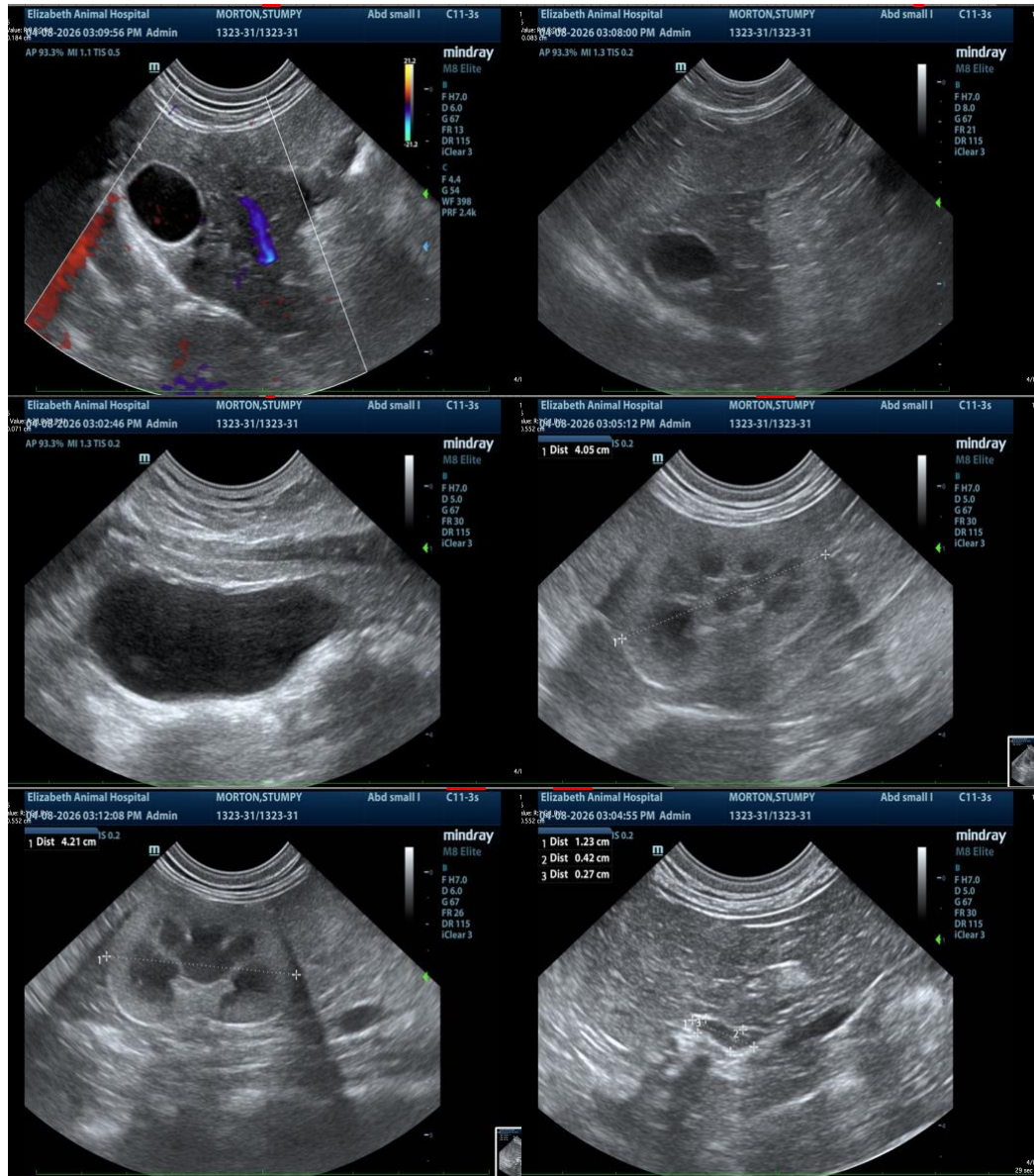
Dr. Leon Anderson
DVM

INVOICE

14972

DATE

04/08/26



The information and recommendations provided are based on the images presented by the referring veterinarian/sonographer. No evaluation can be communicated regarding pathology that was not visible in the image/video clips provided.

Thank you for this referral. If the clinical or image interpretation does not parallel your findings or if I can be of any further assistance, please contact me.

Eric Lindquist, DMV, DABVP(CFM), Cert. IVUSS,

CEO, Owner, Founder -- SonoPath.com



PATIENT

info@SonoPath.com

Stumpy Morton

SPECIES

Feline

BREED

DSH

SEX

Neutered Male

AGE

3 Years 7 Months

WEIGHT

12.5 pounds

INTERPRETED BY

Eric Lindquist, DMV,
DABVP(CFM), Cert.
IVUSS

IMAGING PERFORMED BY

Dr. Leon Anderson
DVM

HOSPITAL NAME

Elizabeth Animal
Hospital

REFERRING VET

Dr. Leon Anderson
DVM

INVOICE

14972

DATE

04/08/26