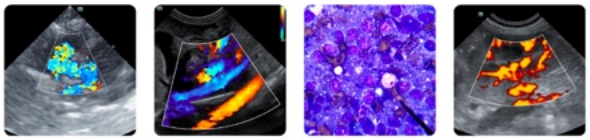

PATIENT
Queenie Anagnostopoulos

SPECIES
Feline

BREED
Domestic Shorthair

SEX
Female

AGE
12 years

WEIGHT
3.1 kg

INTERPRETED BY
Eric Lindquist, DMV DABVP, Cert. IVUSS

IMAGING PERFORMED BY
Harnoor Bhinder

HOSPITAL NAME
Hespeler AH

REFERRING VET
Dr. Bhinder

INVOICE
74320

DATE
4/8/26

PRESENTING CLINICAL SIGNS

History: Irregular nodules palpated at the left 2nd and 3rd mammary glands and the right 3rd and 4th mammary glands. thickening along left and right mammary chains.
normal CBC, chemistry, SDMA, and T4,
with no evidence of metastases on thoracic radiographs.
Normal CBC, biochem and thyroid

ULTRASONOGRAPHIC EXAMINATION OF THE ABDOMEN

Urinary System

The **urinary bladder**, trigone, and pelvic urethra presented normal thicknesses and normal tone. The ureters were not visible which is normal. No uroliths or sediment were visualized and anechoic urine was present. No evidence of inflammatory or neoplastic changes was noted. Ureteral papillae were normal.

The **kidneys** revealed normal size and structure, corticomedullary definition and ratio for this age. The cortices presented largely uniform texture with normal echogenic relationship to liver and spleen. Medullary structure differed distinctly from the cortex and no evidence of pelvic dilation was present. The capsules were acceptably uniform without significant irregularities. The left kidney measured 3.5 cm. The right kidney measured 3.5 cm.

The iliac trifurcation was unremarkable.

Adrenal Glands

The **adrenal glands** were not visualized.

Spleen

The **spleen** revealed slight scalloping contour and uniform parenchyma. The spleen was at the upper limits of normal in size at 0.9 cm.

Liver

The **liver** revealed a microcystic nodule measuring 2.1 cm in the cranial liver adjacent to the diaphragm. This is consistent with cystadenoma. The remainder of the liver was unremarkable. The gallbladder presented acceptably thin walls with primarily anechoic content. The cystic and common bile ducts were normal. No pathological hepatic lymphadenopathy was evident.

Gastrointestinal

Examination of the **gastrointestinal tract** revealed a stomach and intestine free of stasis, of normal wall thickness, acceptable curvilinear mural detail, and peristaltic activity. Small and large intestine

PATIENT

Queenie Anagnostopoulos

SPECIES

Feline

BREED

Domestic Shorthair

SEX

Female

AGE

12 years

WEIGHT

3.1 kg

INTERPRETED BY

Eric Lindquist, DMV DABVP, Cert. IVUSS

IMAGING PERFORMED BY

Harnoor Bhinder

HOSPITAL NAME

Hespeler AH

REFERRING VET

Dr. Bhinder

INVOICE

74320

DATE

4/8/26

demonstrated normal luminal chyme and stool consistency respectively. No obstructive or overt infiltrative disease was noted. No associated abnormal lymphatic activity was noted.

Pancreas

The base and limbs of the **pancreas** were observed to be largely isoechoic to surrounding omental fat. Pancreatic duct and capsular contour were acceptably normal and parenchyma respected normal curvilinear patterns. No overt evidence of active inflammatory or neoplastic disease was noted.

Thorax

The cranial mediastinum was unremarkable. Only fat density was noted. The heart presented subjectively normal volumes and contractility. There was no evidence of thoracic pathology in the acoustic windows available.

ULTRASONOGRAPHIC FINDINGS

Cystadenomatous type liver nodule/mass, likely benign. Isolated and unrelated to the patient's history. Common geriatric finding.

Otherwise, unremarkable abdomen.

INTERPRETATION OF THE FINDINGS & FURTHER RECOMMENDATIONS

The hepatic nodule/mass should be monitored for growth over the next 3-6 months. Ultrasound-guided FNA can be considered; however, these type of nodules do not typically exfoliate readily.

SonoPath
FOSTERING THE ART OF VETERINARY MEDICINE™

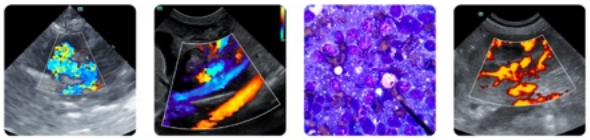

Clinical Sonography & Telecytology
Educational Teleconsultation Services™

SonoPath.com info@sonopath.com 1.800.838.4268

PATIENT

Queenie Anagnostopoulos

SPECIES

Feline

BREED

Domestic Shorthair

SEX

Female

AGE

12 years

WEIGHT

3.1 kg

INTERPRETED BY

Eric Lindquist, DMV DABVP, Cert. IVUSS

IMAGING PERFORMED BY

Harnoor Bhinder

HOSPITAL NAME

Hespeler AH

REFERRING VET

Dr. Bhinder

INVOICE

74320

DATE

4/8/26

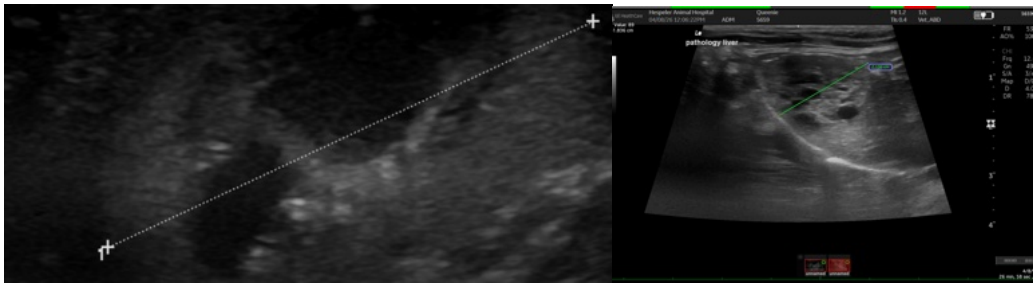

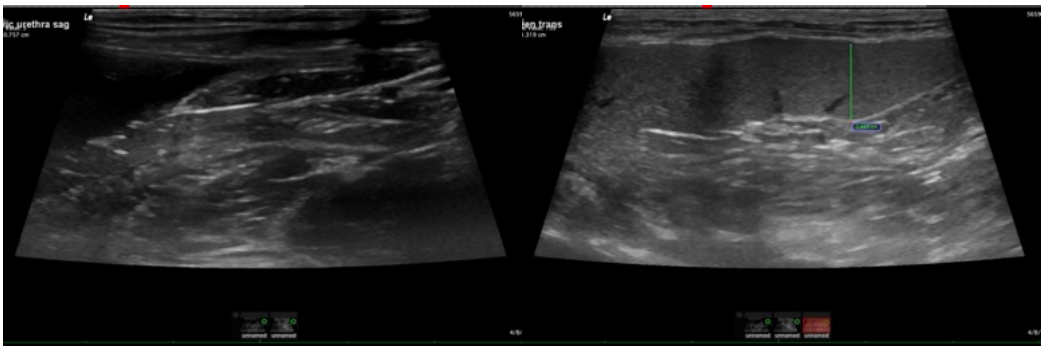

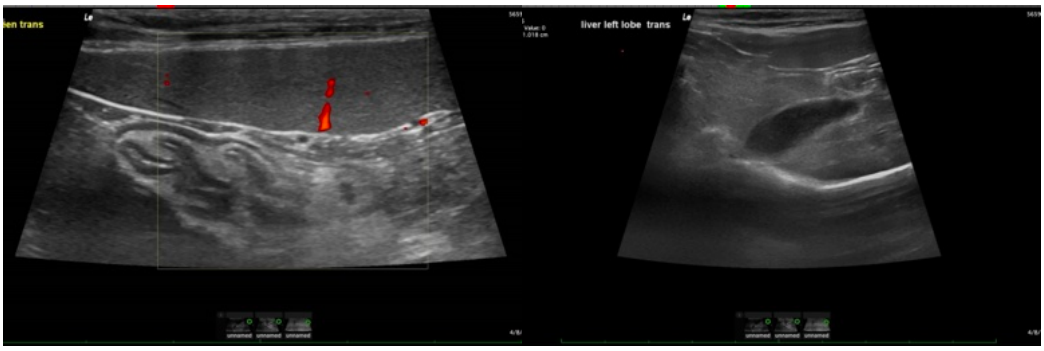

The information and recommendations provided are based on the images presented by the referring veterinarian/sonographer. No evaluation can be communicated regarding pathology that was not visible in the image/video clips provided.

Thank you for this referral. If the clinical or image interpretation does not parallel your findings or if I can be of any further assistance please contact me.

SonoPath
FOSTERING THE ART OF VETERINARY MEDICINE™

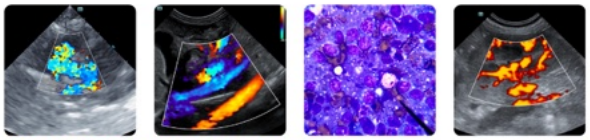

Clinical Sonography & Telecytology
Educational Teleconsultation Services™

SonoPath.com info@sonopath.com 1.800.838.4268

PATIENT

Queenie Anagnostopoulos

SPECIES

Feline

BREED

Domestic Shorthair

SEX

Female

AGE

12 years

WEIGHT

3.1 kg

INTERPRETED BY

Eric Lindquist, DMV DABVP, Cert. IVUSS

IMAGING PERFORMED BY

Harnoor Bhinder

HOSPITAL NAME

Hespeler AH

REFERRING VET

Dr. Bhinder

INVOICE

74320

DATE

4/8/26

Eric Lindquist, DMV, DABVP (CFM), Cert. IVUSS, CEO of SonoPath.com

info@SonoPath.com