



PATIENT

Oscar De Champlain

SPECIES

Canine

BREED

English Bulldog

SEX

Male

AGE

2 ½ years

WEIGHT

30 kg

INTERPRETED BY

Eric Lindquist, DMV
DABVP, Cert. IVUSS

IMAGING PERFORMED BY

Evan Bell

HOSPITAL NAME

Cedarview AH

REFERRING VET

Evan Bell

INVOICE

98168

DATE

4/8/22

PRESENTING CLINICAL SIGNS

History: March 25th collection for insemination showed blood in prostatic fluid. US today shows small hypoechoic cyst/abscess on R prostate. Urinalysis suggestive for rods, culture pending, and moderate blood (poss iatrogenic via cysto). No clinical signs noted.

ULTRASONOGRAPHIC EXAMINATION OF THE ABDOMEN

Urinary System

The **urinary bladder** was mildly thickened. No uroliths or sediment were visualized and anechoic urine was present. No evidence of inflammatory or neoplastic changes was noted. Ureteral papillae were normal.

The **prostate** revealed minor, heterogenous parenchymal changes with a 0.3 cm cyst and remodeling. The prostate measured 4.4 cm at the maximum width. The testicles were uniform.

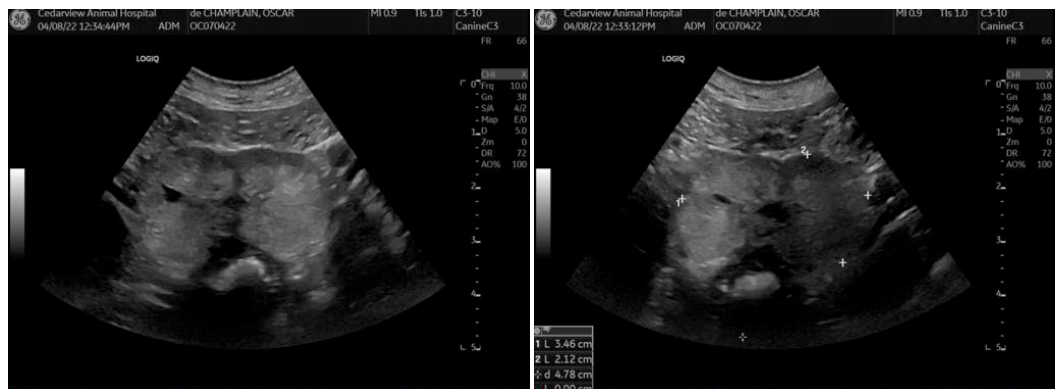The **kidneys** revealed normal size and structure, corticomedullary definition and ratio for this age. The cortices presented largely uniform texture with normal echogenic relationship to liver and spleen. Medullary structure differed distinctly from the cortex and no evidence of pelvic dilation was present. The capsules were acceptably uniform without significant irregularities.

ULTRASONOGRAPHIC FINDINGS

BPH Prostatitis pattern.
Mildly thickened urinary bladder.
Unremarkable testicular images.

INTERPRETATION OF THE FINDINGS & FURTHER RECOMMENDATIONS

FNA of the prostate could be considered for further definition +/- cystic drainage and culture. Enrofloxacin is warranted over a 3-4 week period with reassessment of the clinical signs.





PATIENT

Oscar De Champlain

SPECIES

Canine

BREED

English Bulldog

SEX

Male

AGE

2 ½ years

WEIGHT

30 kg

INTERPRETED BY

Eric Lindquist, DMV
DABVP, Cert. IVUSS

**IMAGING
PERFORMED BY**

Evan Bell

HOSPITAL NAME

Cedarview AH

REFERRING VET

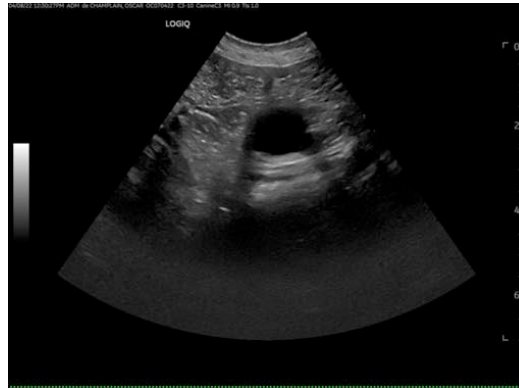
Evan Bell

INVOICE

98168

DATE

4/8/22



The information and recommendations provided are based on the images presented by the referring veterinarian/sonographer. No evaluation can be communicated regarding pathology that was not visible in the image/video clips provided.

Thank you for this referral. If the clinical or image interpretation does not parallel your findings or if I can be of any further assistance please contact me.

Eric Lindquist, DMV, DABVP, Cert. IVUSS, CEO of SonoPath.com
info@SonoPath.com