

**DATE**

4/8/22

**PRESENTING CLINICAL SIGNS****PATIENT**

Nala Bish

History: Pet is just not quite right, hx of IBD (owner treats holistically to keep under control) patient usually does very well with this treatment approach. Recently she has been off, drinks very little then will drink a lot. No v+/D+, eats but not excited about food and does not finish her meals. Previous pet had bladder cancer and owner is concerned about underlying diseases that are not visible.

**SPECIES**

Canine

Current Medications: None.

Lab Results: LDDST normal.

Date of Previous IntraPet Ultrasound: 11/17/20. See attached.

Sedation: Not required to complete full diagnostic ultrasound.

Stat Report: Not requested.

Imaging Performed By: Rachel Brillhart, RDMS.

**BREED**

Pomeranian

**ULTRASONOGRAPHIC EXAMINATION OF THE ABDOMEN****SEX**

Spayed Female

**Urinary System**

The **urinary bladder**, trigone, and pelvic urethra presented normal thicknesses and normal tone. The ureters were not visible which is normal. No uroliths or sediment were visualized and anechoic urine was present. No evidence of inflammatory or neoplastic changes were noted. Ureteral papillae were normal.

**AGE**

11/3/13

The **kidneys** revealed largely normal size and structure, corticomedullary definition and ratio (cortex 1/3 of medulla) were essentially maintained with some mild age-related loss of curvilinear patterns regarding the capsule and C/M junction. The cortices presented largely uniform texture with some increased echogenicity expected for his age patient. Medullary structure differed distinctly from that of the cortex and no evidence of pelvic dilation was present. Mineralization was noted in the kidneys. The left kidney measured 4.4 cm. The right kidney measured 4.31 cm.

**WEIGHT**

19 Pounds

**INTERPRETED BY**Eric Lindquist, DMV  
DABVP, Cert. IVUSS**Adrenal Glands**

Both **adrenal glands** were visualized and recognized as having normal shape, size, position and echogenicity for this breed. The phrenic vasculature, glandular echogenicity and detail were unremarkable. Capsule, cortex, and medullary definition were normal for this age patient. The right adrenal gland measured 1.52 cm x 0.62 cm at the cranial pole and 0.61 cm at the caudal pole. The left adrenal gland measured 2.02 cm x 0.61 cm at the cranial pole and 0.61 cm at the caudal pole.

**HOSPITAL NAME**

Happier at Home MV

**Spleen**

The **spleen** was largely unremarkable with a focal hypoechoic nodule, measuring 0.43 cm.

**REFERRING VET**

Dr. Haskin

**Liver**

The **liver** was uniformly swollen with minor, excessive gallbladder debris and over distension with dependent and suspended bile without evidence of overt mucocele formation. However, excessive sludge was present. The liver presented coarse architecture with mildly increased portal markings and subtle, mixed echogenic changes. This is consistent with vacuolar hepatopathy and some level of remodeling and history of inflammatory component. There was no overt suspicion of neoplasia.

**INVOICE**

14680

**Gastrointestinal**

Examination of the **gastrointestinal tract** revealed a stomach and intestine free of stasis, of normal wall thickness, acceptable curvilinear mural detail, and peristaltic activity. Small and large intestine demonstrated

normal luminal chyme and stool consistency respectively. No obstructive or overt infiltrative disease was noted. No associated abnormal lymphatic activity was noted.

### **Pancreas**

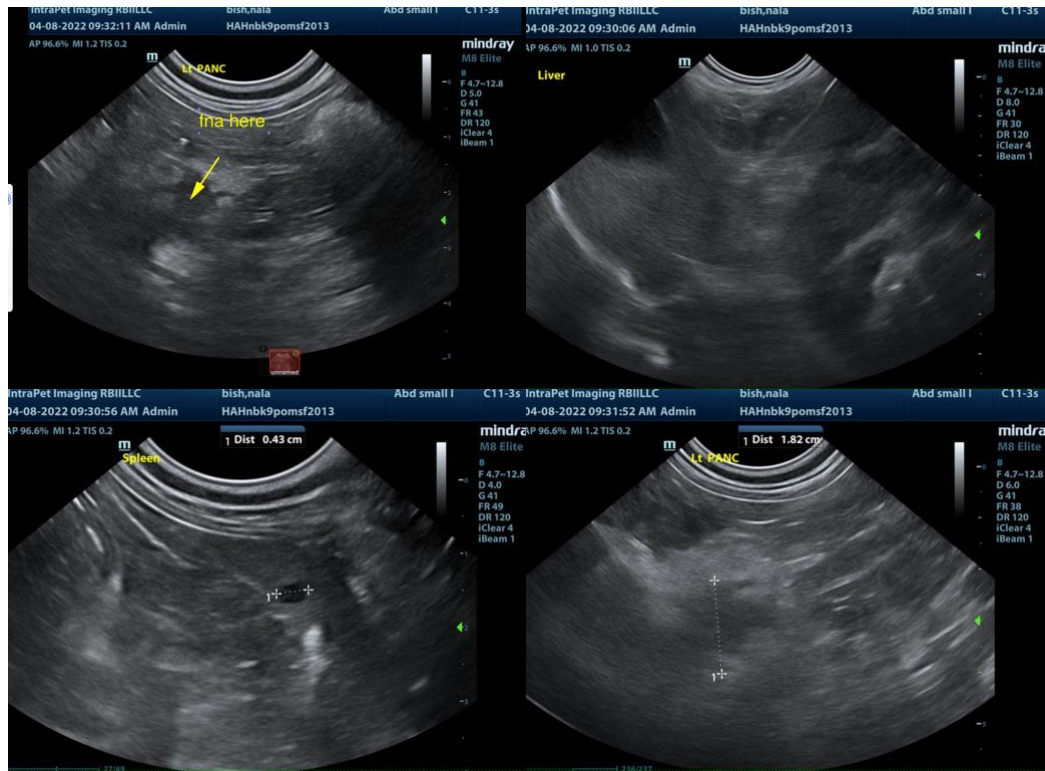
The **pancreas** revealed mixed hyperechoic and hypoechoic changes, occupying the right limb with a moderate amount of remodeling. The left pancreatic limb revealed hypoechoic irregular changes, measuring up to 2.0 cm. Hyperechoic surrounding fat was noted around variable areas of the pancreas, consistent with chronic active pancreatitis.

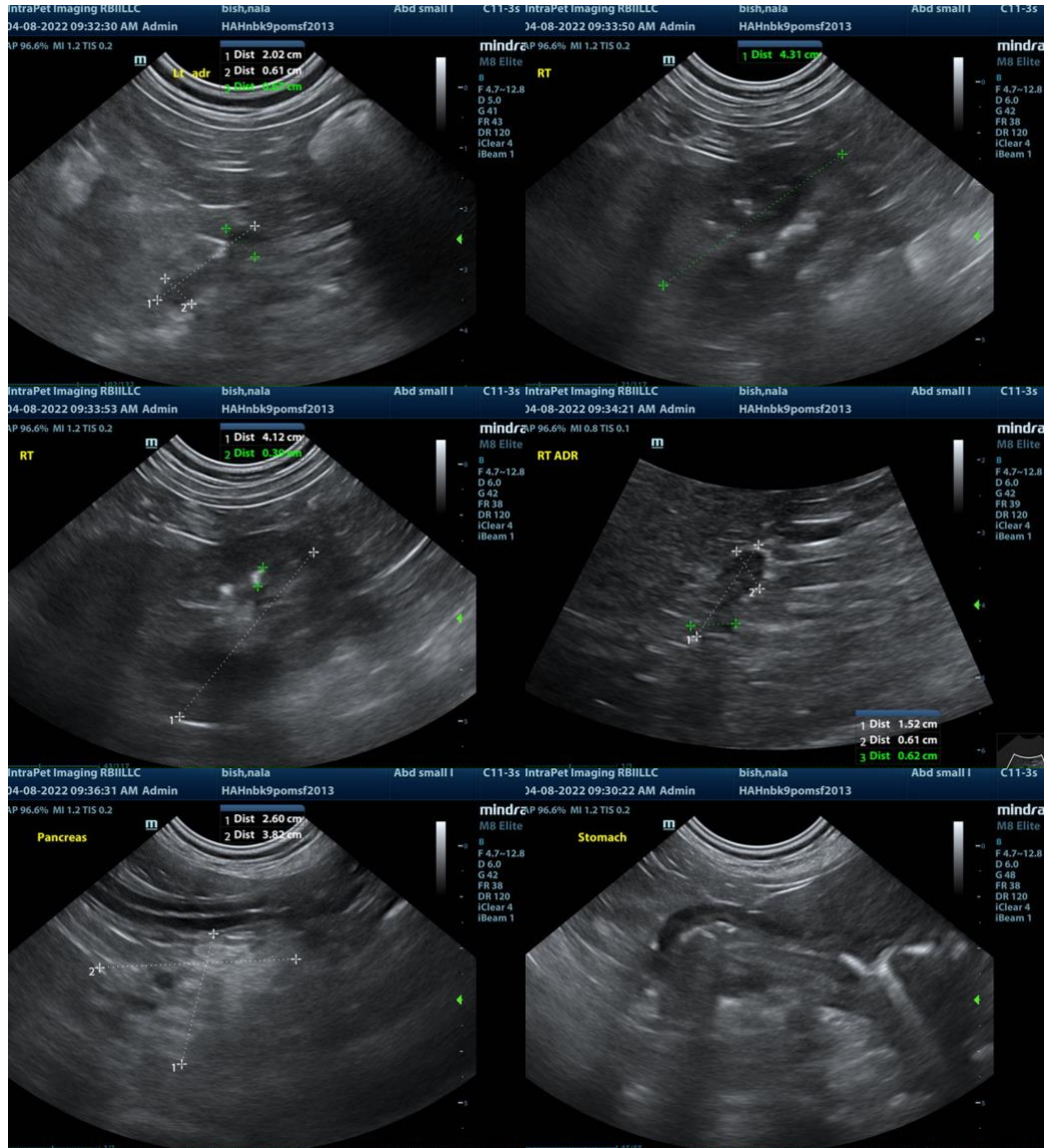
### **ULTRASONOGRAPHIC FINDINGS**

- Pancreatic remodeling and pancreatitis pattern. Chronic active pancreatitis suspected.
- Benign hepatopathy
- Minor renal mineralization
- Focal splenic nodule

### **INTERPRETATION OF THE FINDINGS & FURTHER RECOMMENDATIONS**

FNA of the splenic nodule would be ideal. FNA of the hypoechoic portion of the pancreatic pathology could also be considered for further definition. Minor potential for pancreatic neoplasia. Left and right subxiphoid palpation recommended to assess for discomfort in the pancreatic regions noted.





The information and recommendations provided are based on the images presented by the referring veterinarian. No evaluation can be communicated regarding pathology that was not visible in the image/video clips provided.

Thank you for this referral. If the clinical or image interpretation does not parallel your findings or if I can be of any further assistance please contact me.

**Eric Lindquist**, DMV, DABVP, Cert. IVUSS, CEO of SonoPath.com  
 Eric.Lindquist@SonoPath.com