



PATIENT

Luigi Calderone

SPECIES

Canine

BREED

Shih Tzu Mix

SEX

Neutered male

AGE

11 years

WEIGHT

17.12 lbs

INTERPRETED BY

Eric Lindquist, DMV
DABVP, Cert. IVUSS

IMAGING PERFORMED BY

Dr. Rivera

HOSPITAL NAME

DPC VH

REFERRING VET

Dr. Rivera

INVOICE

98165

DATE

4/8/22

PRESENTING CLINICAL SIGNS

History: Workup to send over to cancer specialist. On 3/24 p has Anal Mass - Hepatoid Adenoma and Right Anal Sac Mass - Apocrine Gland Adenocarcinoma removed. Biopsy results read: Mitotic count 24/hpf, narrow (<0.1mm) margins, Angiolymphatic invasion present

ULTRASONOGRAPHIC EXAMINATION OF THE ABDOMEN

Urinary System

The **urinary bladder**, trigone, and pelvic urethra presented normal thicknesses and normal tone. The ureters were not visible which is normal. No uroliths or sediment were visualized and anechoic urine was present. No evidence of inflammatory or neoplastic changes was noted. Ureteral papillae were normal.

The residual prostate measured 0.5 cm.

The **kidneys** revealed normal size and structure, corticomedullary definition and ratio for this age. The cortices presented largely uniform texture with normal echogenic relationship to liver and spleen. Medullary structure differed distinctly from the cortex and no evidence of pelvic dilation was present. The capsules were acceptably uniform without significant irregularities. The left kidney measured 4.0 cm.

Adrenal Glands

Both **adrenal glands** were visualized and recognized as having normal shape, size, position and echogenicity for this breed. The phrenic vasculature, glandular echogenicity and detail were unremarkable. Capsule, cortex, and medullary definition were normal for this age patient. The left adrenal gland measured 0.5 cm.

Spleen

The **spleen** presented a smooth homogeneous parenchyma hyperechoic to liver and renal cortical parenchyma. The capsule was smooth without noticeable expansion or deviation from within the spleen or adjacent pathology. The splenic vasculature demonstrated normal volume without signs of congestion or thrombosis. No sonographic evidence of acute or chronic inflammatory, neoplastic, or infarctual changes was noted.

Liver

The **liver** images submitted revealed subjectively normal liver size, contour, and structure. Parenchymal echogenicity was naturally coarse and hypoechoic to the spleen. Vascular and biliary tracts were of normal volume with no evidence of congestion. The gallbladder presented acceptably thin walls with primarily anechoic content. The cystic and common bile ducts were normal. No pathological hepatic lymphadenopathy was evident. No overt structural evidence of inflammatory, infiltrative or regenerative pathology was evident.



PATIENT

Gastrointestinal

Luigi Calderone

Examination of the **gastrointestinal tract** revealed a stomach and intestine free of stasis, of normal wall thickness, acceptable curvilinear mural detail, and peristaltic activity. Small and large intestine demonstrated normal luminal chyme and stool consistency respectively. No obstructive or overt infiltrative disease was noted.

SPECIES

Canine

BREED

Shih Tzu Mix

Pancreas

The base and limbs of the **pancreas** were observed to be largely isoechoic to surrounding omental fat. Pancreatic duct and capsular contour were acceptably normal and parenchyma respected normal curvilinear patterns. No overt evidence of active inflammatory or neoplastic disease was noted.

SEX

Neutered male

Free Abdomen

A singular, isoechoic, iliac lymph node was slightly enlarged and irregular measuring 2.0 x 1.0 cm. The remaining lymph nodes were unremarkable. The region presented isoechoic tissue. There was no other evidence of potential metastatic disease noted.

AGE

11 years

WEIGHT

17.12 lbs

ULTRASONOGRAPHIC FINDINGS

Irregular iliac lymph node.

Otherwise, structurally unremarkable abdomen.

INTERPRETED BY

Eric Lindquist, DMV
DABVP, Cert. IVUSS

INTERPRETATION OF THE FINDINGS & FURTHER RECOMMENDATIONS

This area should be monitored in 3-4 weeks for any progression. FNA of the sublumbar lymph node could be considered if accessible, yet the length to width ratio would suggest a reactive node or normal variant at this point.

IMAGING PERFORMED BY

Dr. Rivera

HOSPITAL NAME

DPC VH

REFERRING VET

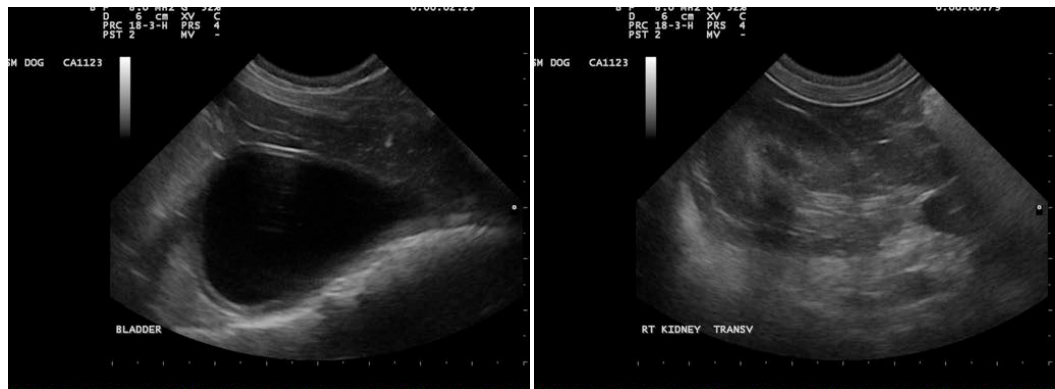
Dr. Rivera

INVOICE

98165

DATE

4/8/22





PATIENT

Luigi Calderone

SPECIES

Canine

BREED

Shih Tzu Mix

SEX

Neutered male

AGE

11 years

WEIGHT

17.12 lbs

INTERPRETED BY

Eric Lindquist, DMV
DABVP, Cert. IVUSS

**IMAGING
PERFORMED BY**

Dr. Rivera

HOSPITAL NAME

DPC VH

REFERRING VET

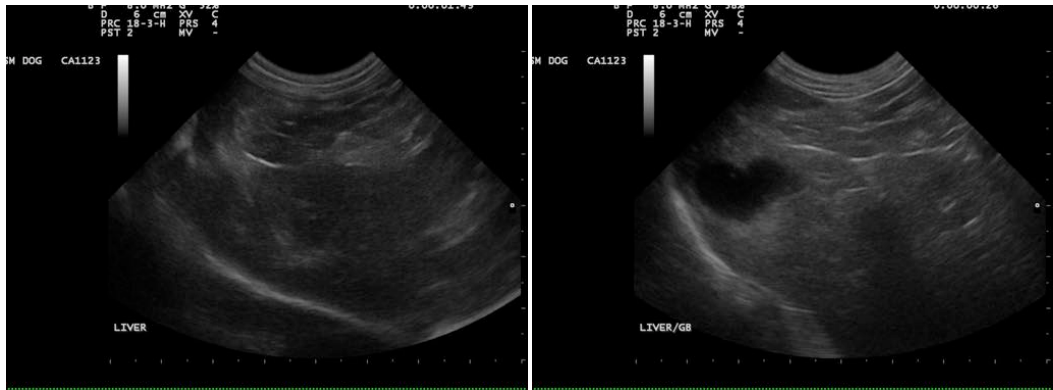
Dr. Rivera

INVOICE

98165

DATE

4/8/22



The information and recommendations provided are based on the images presented by the referring veterinarian/sonographer. No evaluation can be communicated regarding pathology that was not visible in the image/video clips provided.

Thank you for this referral. If the clinical or image interpretation does not parallel your findings or if I can be of any further assistance please contact me.

Eric Lindquist, DMV, DABVP, Cert. IVUSS, CEO of SonoPath.com
info@SonoPath.com