



PATIENT

Ginger King

SPECIES

Canine

BREED

Dachshund

SEX

Spayed Female

AGE

7 Years

WEIGHT

17.5 Pounds

INTERPRETED BY

Eric Lindquist, DMV
DABVP, Cert. IVUSS

IMAGING PERFORMED BY

Gudrun Gunther

HOSPITAL NAME

New Frontier AMC

REFERRING VET

Gudrun Gunther

INVOICE

14690

DATE

4/8/22

PRESENTING CLINICAL SIGNS

History: Patient diagnosed with a bladder transitional cell carcinoma in January 2022. O considering surgery/chemotherapy. Abdominal ultrasound and thoracic radiographs for staging purposes Patient has been taking Piroxicam 3mg/kg since January

Abnormal PE/Chem/CBC/UA Results: BRAF positive Mild elevation ALT (145)

ULTRASONOGRAPHIC EXAMINATION OF THE ABDOMEN

Urinary System

The **urinary bladder** revealed a mixed echogenic multifocal mineralizing apical mass with second mass in the dorsal ureteral papilla region. The apical mass measured 2.2 cm at maximum width. The dorsal caudal bladder lesion measured 1.9 cm x 1.0 cm. The cystourethral junction and proximal urethra were unremarkable with slight focal thickening at the ventral caudal bladder wall at the base of the cystourethral junction measuring 0.3 cm. The pathology was hypervascular, strongly suggestive for transitional cell carcinoma and a multifocal nonsurgical presentation. The iliac lymph nodes were unremarkable.

The **kidneys** revealed largely normal size and structure, corticomedullary definition and ratio (cortex 1/3 of medulla) were essentially maintained with some mild age-related loss of curvilinear patterns regarding the capsule and C/M junction. The cortices presented largely uniform texture with some increased echogenicity expected for his age patient. Medullary structure differed distinctly from that of the cortex and no evidence of pelvic dilation was present. The right kidney measured 4.26 cm. The left kidney measured 4.42 cm.

Adrenal Glands

The **right adrenal gland** was visualized and recognized as having normal shape, size, position and echogenicity for this breed. The phrenic vasculature, glandular echogenicity and detail were unremarkable. Capsule, cortex, and medullary definition were normal for this age patient. The right adrenal gland measured 0.63 cm at maximum width.

The **left adrenal gland** revealed a serpentine shape with tissue occupation of the phrenic vein. Slight irregular contour was noted. Blood flow was still present within the phrenic vein, yet partially occupied, strongly suggestive for carcinoma or pheochromocytoma, subjectively too organized to be simple thrombus. The left adrenal gland measured 0.69 cm.

Spleen

The **spleen** presented a smooth homogeneous parenchyma hyperechoic to liver and renal cortical parenchyma. The capsule was smooth without noticeable expansion or deviation from within the spleen or adjacent pathology. The splenic vasculature demonstrated normal volume without signs of congestion or thrombosis. No sonographic evidence of acute or chronic inflammatory, neoplastic, or infarctual changes were noted. Caudal folding of the spleen was noted.

Liver

The **liver** images from right and left intercostal as well as subcostal views revealed subjectively normal liver size, contour, and structure. Some minor age-related parenchymal remodeling was noted but likely not clinically significant at this time. The gallbladder was mildly over distended with suspended



PATIENT

Ginger King

and dependent debris, yet not to the level of emerging mucocele, yet sludge appears to be mildly excessive. No adjunctive inflammation was noted.

SPECIES

Canine

Gastrointestinal

Examination of the **gastrointestinal tract** revealed a stomach and intestine free of stasis, of normal wall thickness, acceptable curvilinear mural detail, and peristaltic activity. Small and large intestine demonstrated normal luminal chyme and stool consistency respectively. No obstructive or overt infiltrative disease was noted. No associated abnormal lymphatic activity was noted.

BREED

Dachshund

Pancreas

SEX

Spayed Female

The base and limbs of the **pancreas** were observed to be largely isoechoic to surrounding omental fat. Pancreatic duct and capsular contour were acceptably normal and parenchyma respected normal curvilinear patterns. No overt evidence of active inflammatory or neoplastic disease was noted.

AGE

7 Years

ULTRASONOGRAPHIC FINDINGS

- Nonresectable, multifocal bladder masses, strongly vascularized and mineralized, suggestive for transitional cell carcinoma. Cystoscopy would be ideal to obtain tissue biopsies, otherwise traumatic catheterization could be considered.
- Irregular left adrenal gland with phrenic vein occupation. Even though the left adrenal gland appeared largely normal, irregular shape and phrenic vein occupation would suggest carcinoma or pheochromocytoma. Left adrenal through the right approach would be ideal, in order to assess for invasion into the vena cava.
- Age-related hepatic changes
- Gallbladder sludge
- Splenic fold
- Age-related renal changes

WEIGHT

17.5 Pounds

INTERPRETED BY

Eric Lindquist, DMV
DABVP, Cert. IVUSS

IMAGING PERFORMED BY

Gudrun Gunther

HOSPITAL NAME

New Frontier AMC

INTERPRETATION OF THE FINDINGS & FURTHER RECOMMENDATIONS

Serial blood pressures warranted to assess if any hypertension is related to the left adrenal. The left adrenal gland does appear resectable, however, given the comorbidity of the bladder neoplasia, full global assessment should be considered, regarding life quality.

REFERRING VET

Gudrun Gunther

INVOICE

14690

DATE

4/8/22



PATIENT

Ginger King

SPECIES

Canine

BREED

Dachshund

SEX

Spayed Female

AGE

7 Years

WEIGHT

17.5 Pounds

INTERPRETED BY

Eric Lindquist, DMV
DABVP, Cert. IVUSS

IMAGING PERFORMED BY

Gudrun Gunther

HOSPITAL NAME

New Frontier AMC

REFERRING VET

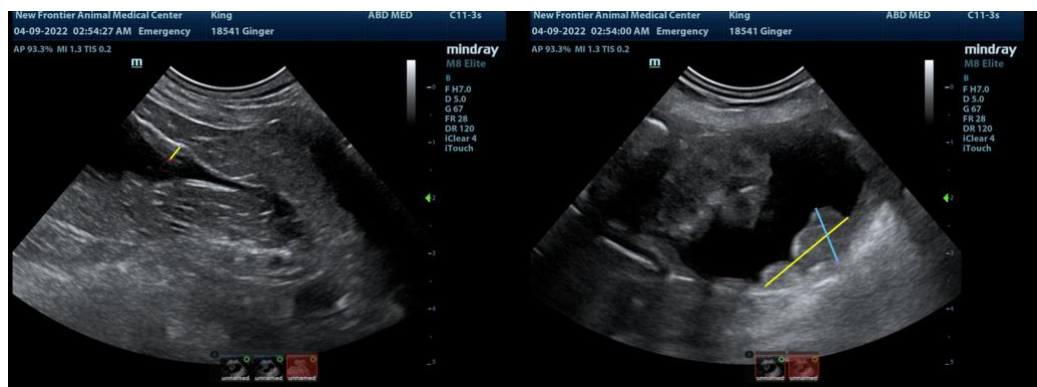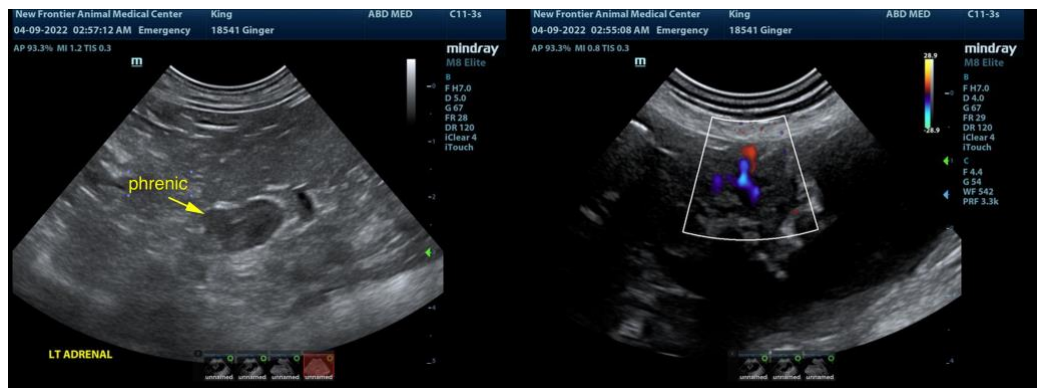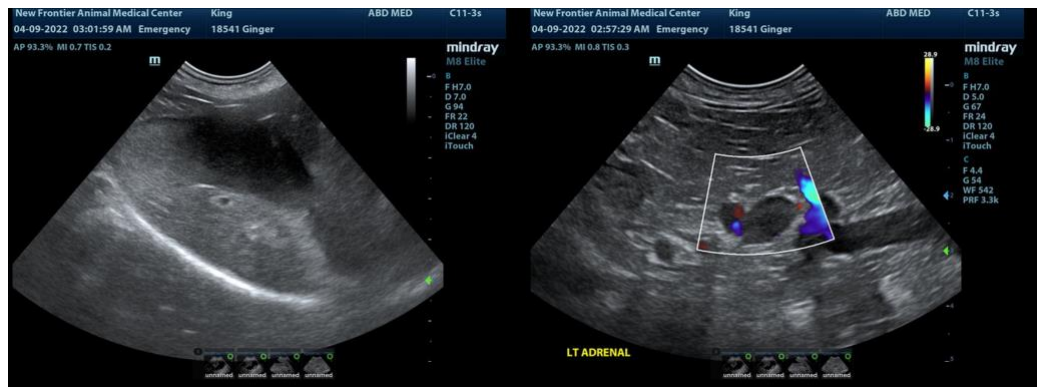
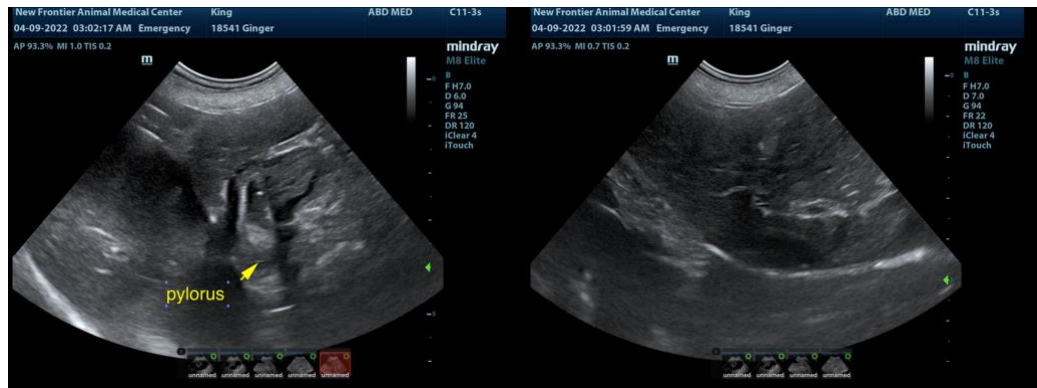
Gudrun Gunther

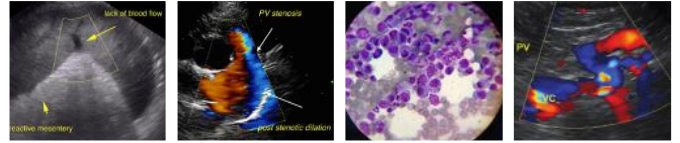
INVOICE

14690

DATE

4/8/22





PATIENT

Ginger King

SPECIES

Canine

BREED

Dachshund

SEX

Spayed Female

AGE

7 Years

WEIGHT

17.5 Pounds

INTERPRETED BY

Eric Lindquist, DMV
DABVP, Cert. IVUSS

IMAGING PERFORMED BY

Gudrun Gunther

HOSPITAL NAME

New Frontier AMC

REFERRING VET

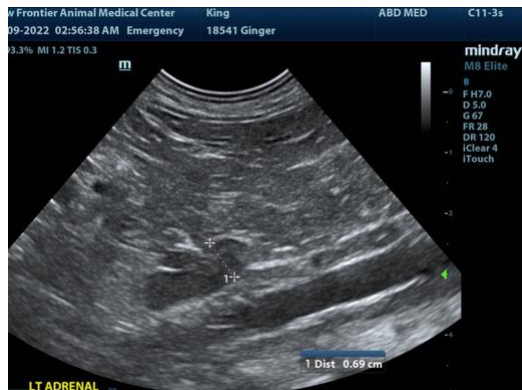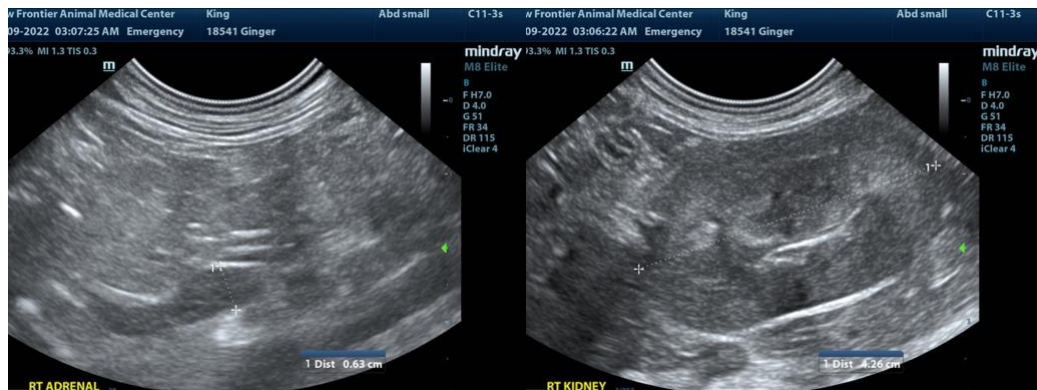
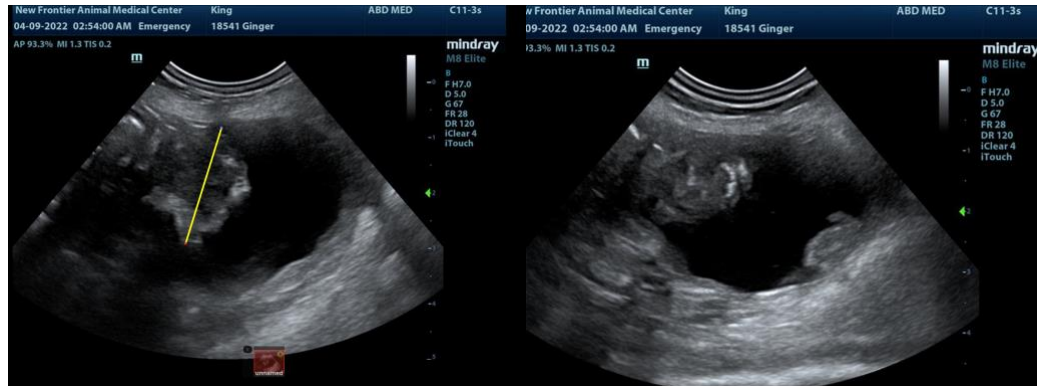
Gudrun Gunther

INVOICE

14690

DATE

4/8/22



The information and recommendations provided are based on the images presented by the referring veterinarian. No evaluation can be communicated regarding pathology that was not visible in the image/video clips provided.

Thank you for this referral. If the clinical or image interpretation does not parallel your findings or if I can be of any further assistance please contact me.

Eric Lindquist, DMV, DABVP, Cert. IVUSS, CEO of SonoPath.com
info@SonoPath.com

Transitional Cell Carcinoma



PATIENT

<http://www.sonopath.com/TCC>

Ginger King

SPECIES

Canine

BREED

Dachshund

SEX

Spayed Female

AGE

7 Years

WEIGHT

17.5 Pounds

INTERPRETED BY

Eric Lindquist, DMV
DABVP, Cert. IVUSS

IMAGING PERFORMED BY

Guhrun Gunther

HOSPITAL NAME

New Frontier AMC

REFERRING VET

Guhrun Gunther

INVOICE

14690

DATE

4/8/22

Description: Many cases of transitional cell carcinoma (TCC) are either mistaken for urinary tract infections (UTIs) or go undiagnosed until they reach an advanced stage, thereby compromising the possibility for successful treatment. In dogs, TCC represents 90-95% of all bladder tumors; the remaining cases are comprised of squamous cell carcinoma, adenocarcinoma, papilloma, leiomyosarcoma, fibrosarcoma, hemangiosarcoma, and rhabdomyosarcoma. Urinary bladder tumors are rare in cats, but when they do occur, they are usually cases of TCC, lymphoma, or mesenchymal tumors.

Clinical Signs: Clinical signs of TCC typically include: hematuria, stranguria, pollakiuria, lethargy, weight loss, and bone pain or organ failure due to metastasis. Diagnosis occurs at a mean age of 11 years, and females are more often affected than males (ratio of 1.7:1). Overrepresented breeds include Scottish Terriers, Shetland Sheepdogs, West Highland White Terriers, Airedale Terriers, and Beagles. Obesity appears to be a predisposing factor. Insecticide exposure as well as cyclophosphamide and acrolein use have also been identified as potential triggers.

Diagnostics: Urine sediment analysis can reveal neoplastic cells in up to 30% of cases; however, interpretation must be scrupulous as reactive cells have a similar morphology to neoplastic ones. Ultrasound diagnostics, when available, provide prompt visualization as well as early detection by capturing minute irregularities in the bladder wall down to 2 mm as well as imaging the pelvic urethra to 3-4 cm caudal from the cystourethral junction. Ultrasound can also be used to evaluate regional lymph nodes and other organs for evidence of metastasis as well as the kidneys and ureter for evidence of impingement and back-pressure from tumors located in the trigone area. One study of 65 dogs suggested that it might be possible to achieve even earlier detection using the veterinary bladder tumor antigen test (V-BTA, Bion Diagnostics), which yielded 90% sensitivity and 78% specificity. False positives occurred, however, in cases where the subjects had hematuria, proteinuria, and glucosuria.

The V-BTA is best used as a screening test, not a diagnostic tool. A negative test suggests that TCC is not likely present, but a positive test indicates that more testing—and a cytopathological or histopathological test in particular—is warranted. Although the V-BTA demonstrates good sensitivity, it only yields reasonable specificity; however, the negative predictive value is 95%. The most appropriate use of this test may be as a screening tool to rule out TCC in geriatric dogs. The second and third generation tests—(BTA stat® and Bard Trak, respectively)—should not be used in dogs as they often yield false negative results.

Treatment: Up to 80% of the urinary bladder can be surgically resected without long-term compromise provided that the trigone is not involved; however, canine TCC often involves the trigone area. TCC in dogs is metastatic, and up to 40% of dogs have metastatic disease at the time of diagnosis (17% of cases will have spread to the lungs). One study of 70 dogs revealed that the 25 that were treated with surgical debulking and medical therapy (chemotherapy and/or piroxicam) achieved a median life span of 272 days. Those that underwent biopsy only with medical therapy (42 dogs) experienced a median life span of 195 days, while the remaining 36 dogs that received medical therapy only averaged 150 days.



PATIENT

Ginger King

Surgical options include partial cystectomy, total cystectomy, ureterocolonic anastomosis, or the insertion of a permanent cystostomy catheter. Complete staging, including 3-view thoracic radiographs and abdominal ultrasound, should be performed prior to surgical intervention. A screening of spinal radiographs allows for an evaluation of the lumbar vertebrae.

SPECIES

Canine

Survival times range from a few months to over 48 months, depending on staging criteria and the procedure performed. The survival rate for patients with “non-resectable” trigonal/urethral TCC has improved considerably with the recent development of a new procedure—US-guided endoscopic laser ablation (UGELAB), which can be used in combination with urethral stents. UGELAB has shown significant success as a palliative procedure and can be repeated as progression occurs. Importantly, it avoids seeding by keeping the exfoliating cells within the bladder and is therefore an excellent method of obtaining clean samples given that this kind of tumor is notorious for “trailing” along needle passages. Anecdotal evidence suggests that strongly mineralized tumors respond best to laser ablation (tumor reduction from chemotherapy does not tend to be as effective in these cases). One study of over 60 patients indicated that survival times for those that underwent UGELAB varies depending on the tumor position and ureteral involvement. They ranged between 11 days and 1906 days; however, the median survival time (MST) was approximately 380 days, even in cases when additional therapies had also been pursued.

BREED

Dachshund

SEX

Spayed Female

AGE

7 Years

WEIGHT

17.5 Pounds

Complete surgical excision of TCC is usually not possible due to trigone location, tumour size, and the presence of multifocal TCC. A study of 67 dogs with TCC resulted in 2 dogs with tumour-free margins; however, one of these dogs experienced a relapse 8 months later, and the other developed metastatic disease. Radiation therapy alone does not appear to be effective, and the benefits of surgical debulking remain controversial. TCC often recurs in the bladder despite surgical resection, either as a result of microscopic disease at the surgical margins or *de novo* tumor growth due to field carcinogenesis. It is thought that TCC may reoccur in other regions of the bladder wall post-resection since it is highly likely that the entire bladder mucosa would have been exposed to the same carcinogen. Previously affected bladders therefore appear to be predisposed to new tumor development.

INTERPRETED BY

Eric Lindquist, DMV
DABVP, Cert. IVUSS

IMAGING PERFORMED BY

Guhrun Gunther

HOSPITAL NAME

New Frontier AMC

REFERRING VET

Guhrun Gunther

Chemotherapy remains the treatment of choice for TCC as radiation therapy leads to difficulties with bladder fibrosis. Over the years, various chemotherapeutics have been investigated, such as cisplatin and carboplatin, but few have resulted in increased survivability and many result in significant toxic side effects. Nonsteroidal anti-inflammatory drugs (NSAIDs), including both nonselective COX inhibitors and selective COX II inhibitors, exhibit anti-carcinoma effects and result in partial remission, disease stabilization, and, less commonly, full remission for dogs with TCC. The MST of dogs treated with piroxicam (0.3 mg/kg PO Q24hr) has been reported to be 210 days, which is comparable to the MSTs achieved with other more toxic chemotherapeutics. GI ulceration can occur with piroxicam because it is a non-selective NSAID and inhibits prostaglandin E₂ (PGE₂). To prevent and treat gastric ulceration, misoprostol, a prostaglandin E analogue, should be administered (100 ug/dog PO TID). Selective COX II inhibitors, such as deracoxib (3 mg/kg PO Q24hr) and meloxicam (0.1 mg/kg PO Q24hr), exhibit less GI irritation and can be used as alternatives. Clinical ulceration can be managed with misoprostol (100 ug/dog PO TID), sucralfate (1/2-1 g PO TID; it should be taken one hour before or after food), and concurrent omeprazole (0.7 mg/kg PO Q24hr). One other negative side effect of COX inhibition is reduced renal blood flow due to prostaglandin and thromboxane

INVOICE

14690

DATE

4/8/22



PATIENT

Ginger King

inhibition, which can result in azotemia in dogs with subnormal renal function. Therefore, it is imperative to assess the baseline renal function and monitor renal analytes over time in these cases.

SPECIES

Canine

Piroxicam demonstrates greater therapeutic effectiveness when coupled with other chemotherapeutics, such as mitoxantrone. According to one study, the combination of drugs resulted in an MST of 291 days. Typically, an NSAID is combined with mitoxantrone and/or vinblastine. Current studies are examining the effects of tyrosine kinase inhibitors on TCC and whether it is more effective alone or in combination with piroxicam. Research is also being conducted on the use of metronomic chemotherapy, which entails the long-term administration of a low-dose chemotherapeutic, such as chlorambucil or another agent.

BREED

Dachshund

SEX

Spayed Female

Common complications associated with TCC in dogs include local invasion, which results in urethral and ureteral obstruction and hydronephrosis, and metastatic disease, which leads to systemic involvement. Metastasis most commonly affects local and distant lymph nodes, the lungs, and the liver. Twenty percent of TCC patients present with metastasis at the time of diagnosis.

AGE

7 Years

Urethral obstruction can be treated with an indwelling catheter, intermittent catheterization, or a tube cystotomy; however, the best long-term management entails the insertion of a urethral stent by a specialist trained in Interventional Radiology. Unfortunately, urinary incontinence is a long-term possible complication of stent placement.

WEIGHT

17.5 Pounds

INTERPRETED BY

Eric Lindquist, DMV
DABVP, Cert. IVUSS

Many patients often require concurrent—and recurring—treatment for UTIs. Dogs with TCC may have recurrent or chronic UTIs, and the clinician should therefore remain vigilant with respect to this complicating problem.

IMAGING PERFORMED BY

Gudrun Gunther

Conclusion: TCC is a frequent cause of bladder neoplasia in dogs. Hematuria, pollakiuria, and dysuria are the most common clinical signs. A multimodal therapy that includes NSAIDs, chemotherapy, stent placement, and possibly endoscopic ablation (UGELAB) may extend disease-free intervals for patients. Cats are much less frequently affected by TCC than dogs.

HOSPITAL NAME

New Frontier AMC

References:

REFERRING VET

Gudrun Gunther

Blackburn AL, Berent AC, Weisse CW, Brown DC. Evaluation of outcome following urethral stent placement for the treatment of obstructive carcinoma of the urethra in dogs: 42 cases (2004-2008). *J Am Vet Med Assoc* 2013;242(1):59-68.

INVOICE

14690

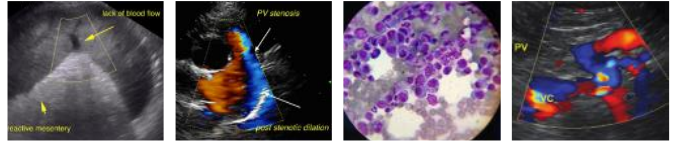
Boria PA, Glickman NW, Schmidt BR, et al. Carboplatin and piroxicam therapy in 31 dogs with transitional cell carcinoma of the urinary bladder. *Vet Comp Oncol* 2005;3(2):73-80.

DATE

4/8/22



PATIENT	Cerf DJ, Lindquist EL. Palliative ultrasound-guided endoscopic diode laser ablation of transitional cell carcinomas of the lower urinary tract in dogs. <i>J Am Vet Med Assoc</i> 2012;240(1):51-60.
Ginger King	
SPECIES	Glickman LT, Raghavan M, Knapp DW, et al. Herbicide exposure and the risk of transitional cell carcinoma of the urinary bladder in Scottish Terriers. <i>J Am Vet Med Assoc</i> 2004;224(8):1290-97.
Canine	
BREED	Henry CJ, Tyler JW, McEntee MC, et al. Evaluation of a bladder tumor antigen test as a screening test for transitional cell carcinoma of the lower urinary tract in dogs. <i>Am J Vet Res</i> 2003;64(8):1017-20.
Dachshund	
SEX	Henry CJ. Management of transitional cell carcinoma. <i>Vet Clin North Am Small Anim Pract</i> 2003;33(3):597-613.
Spayed Female	
AGE	Henry CJ. Bladder and urethral tumors. In: Henry CJ, Higginbotham ML, eds. <i>Cancer Management in Small Animal Practice</i> . St. Louis, MO: Elsevier; 2010:290.
7 Years	
WEIGHT	Knapp DW. Urinary bladder cancer. In: Bonagura J, Twedt D, eds. <i>Kirk's Current Veterinary Therapy XIV</i> . St. Louis, MO: Saunders Elsevier; 2008:369-73.
17.5 Pounds	
INTERPRETED BY	Knapp DW. Ultrasound-guided endoscopic diode laser ablation in dogs with transitional cell carcinoma. <i>J Am Vet Med Assoc</i> 2012;240(7):802.
Eric Lindquist, DMV DABVP, Cert. IVUSS	
IMAGING PERFORMED BY	London C. Toceranib phosphate for the treatment of solid tumors in dogs and cats. Proceedings from the American College of Veterinary Internal Medicine, Denver, CO, June 15-18, 2011.
McMillan SK, Boria P, Moore GE, et al. Antitumor effects of deracoxib treatment in 26 dogs with transitional cell carcinoma of the urinary bladder. <i>J Am Vet Med Assoc</i> 2011;239(8):1084-89.	
Guhrun Gunther	
HOSPITAL NAME	Mutsaers AJ, Widmer WR, Knapp DW. Canine transitional cell carcinoma. <i>J Vet Intern Med</i> 2003;17(2):136-44.
New Frontier AMC	
REFERRING VET	Nyland TG, Wallack ST, and Wisner ER. Needle-tract implantation following us-guided fine-needle aspiration biopsy of transitional cell carcinoma of the bladder, urethra, and prostate. <i>Vet Radiol Ultrasound</i> 2002;43(1):50-53.
Guhrun Gunther	
INVOICE	Raghavan M, Knapp DW, Dawson MH, et al. Topical flea and tick pesticides and the risk of transitional cell carcinoma of the urinary bladder in Scottish Terriers. <i>J Am Vet Med Assoc</i> 2004;225(3):389-94.
14690	
DATE	Schrempp DR, Childress MO, Stewart JC, et al. Metronomic administration of chlorambucil for treatment of dogs with urinary bladder transitional cell carcinoma. <i>J Am Vet Med Assoc</i> 2013;242(11):1534-38.
4/8/22	



PATIENT

Ginger King

Weisse C, Berent A, Todd K, et al Evaluation of palliative stenting for management of malignant urethral obstructions in dogs. *J Am Vet Med Assoc* 2006;229(2):226-34.

SPECIES

Canine

BREED

Dachshund

SEX

Spayed Female

AGE

7 Years

WEIGHT

17.5 Pounds

INTERPRETED BY

Eric Lindquist, DMV
DABVP, Cert. IVUSS

**IMAGING
PERFORMED BY**

Gudrun Gunther

HOSPITAL NAME

New Frontier AMC

REFERRING VET

Gudrun Gunther

INVOICE

14690

DATE

4/8/22