



PATIENT

Duke Aquan- Yuan

SPECIES

Canine

BREED

Port Water Dog

SEX

Neutered Male

AGE

9 years

WEIGHT

80 Pounds

INTERPRETED BY

Eric Lindquist, DMV
DABVP, Cert. IVUSS

**IMAGING
PERFORMED BY**

Kelly Reschny

HOSPITAL NAME

Maples AH

REFERRING VET

Dr. Kazienko

INVOICE

14665

DATE

4/8/22

PRESENTING CLINICAL SIGNS

History: grade 4 murmur, left sided had mast cell tumor removed from ear a few years ago, now has larger, firm mass on right shoulder/neck area.

LIMITED ULTRASONOGRAPHIC EXAMINATION

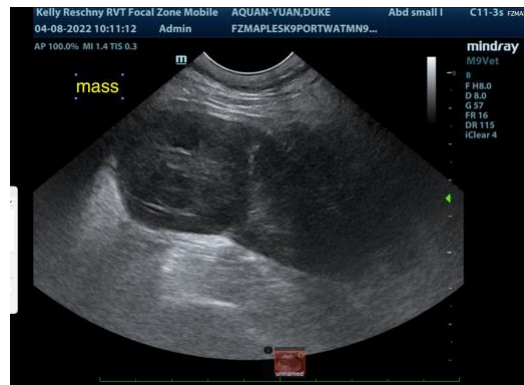
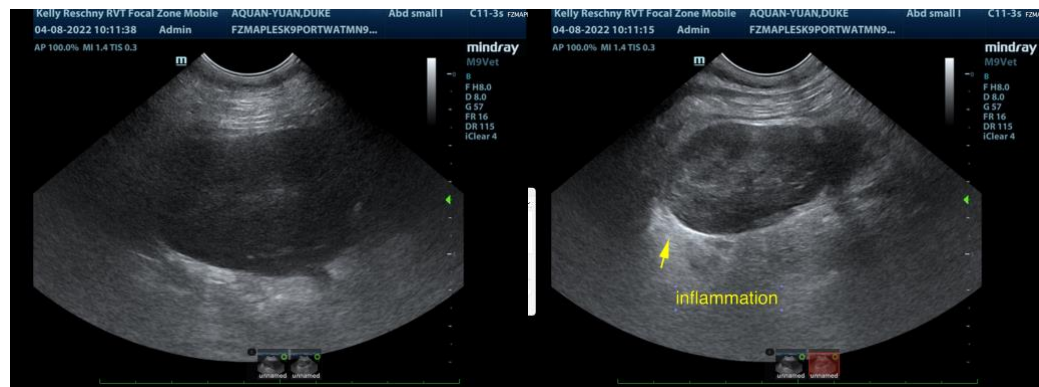
Shoulder mass in this patient was undifferentiated, nodular mass, measuring 5.0 cm at maximum width, extending for approximately 10 cm with regional inflammation. The mass appeared to occupy the subcutaneous and deep tissue. Some margins were ill-defined, strongly suggestive for round cell neoplasia or sarcoma.

ULTRASONOGRAPHIC FINDINGS

- Sarcomatous type mass with peripheral inflammation, may be related to mast cell history

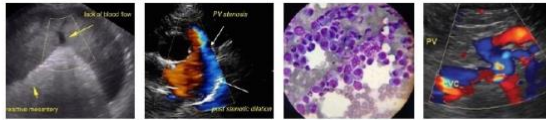
INTERPRETATION OF THE FINDINGS & FURTHER RECOMMENDATIONS

FNA indicated + abdominal sonogram to assess for related lesions +/- CT for potential surgical planning, however, clean resection is debatable as some margins appear to be somewhat ill-defined.



The information and recommendations provided are based on the images presented by the referring veterinarian. No evaluation can be communicated regarding pathology that was not visible in the image/video clips provided.

Thank you for this referral. If the clinical or image interpretation does not parallel your findings or if I can be of any further assistance please contact me.



PATIENT

Duke Aquan- Yuan

Eric Lindquist, DMV, DABVP, Cert. IVUSS, CEO of SonoPath.com
Eric.Lindquist@SonoPath.com

SPECIES

Canine

BREED

Port Water Dog

SEX

Neutered Male

AGE

9 years

WEIGHT

80 Pounds

INTERPRETED BY

Eric Lindquist, DMV
DABVP, Cert. IVUSS

IMAGING PERFORMED BY

Kelly Reschny

HOSPITAL NAME

Maples AH

REFERRING VET

Dr. Kazienko

INVOICE

14665

DATE

4/8/22