



PATIENT

Benny Bedell

SPECIES

Canine

BREED

Shetland Sheepdog

SEX

Neutered Male

AGE

3 Years

WEIGHT

25.5 Pounds

INTERPRETED BY

Eric Lindquist, DMV
DABVP, Cert. IVUSS

IMAGING PERFORMED BY

Diane McFadden

HOSPITAL NAME

Rockaway AH

REFERRING VET

Dr. Maniar

INVOICE

14659

DATE

4/8/22

PRESENTING CLINICAL SIGNS

History: vomited undigested food, continuously

Abnormal PE/Chem/CBC/UA Results: pending

ULTRASONOGRAPHIC EXAMINATION OF THE ABDOMEN

Urinary System

The **urinary bladder**, trigone, and pelvic urethra presented normal thicknesses and normal tone. The ureters were not visible which is normal. No uroliths or sediment were visualized, and anechoic urine was present. No evidence of inflammatory or neoplastic changes were noted. Ureteral papillae were normal.

The **kidneys** revealed normal size and structure, corticomedullary definition and ratio for this age. The cortices presented largely uniform texture with normal echogenic relationship to liver and spleen. Medullary structure differed distinctly from the cortex and no evidence of pelvic dilation was present. The capsules were acceptably uniform without significant irregularities. The right kidney measured 4.28 cm. The left kidney measured 3.94 cm.

Adrenal Glands

Both **adrenal glands** were visualized and recognized as having normal shape, size, position and echogenicity for this breed. The phrenic vasculature, glandular echogenicity and detail were unremarkable. Capsule, cortex, and medullary definition were normal for this age patient. The left adrenal gland measured 2.3 cm x 0.54 cm at the caudal pole and 0.55 cm at the cranial pole. The right adrenal gland measured 1.75 cm x 1.02 cm at the cranial pole and 0.37 cm at the caudal pole.

Spleen

The **spleen** presented a smooth homogeneous parenchyma hyperechoic to liver and renal cortical parenchyma. The capsule was smooth without noticeable expansion or deviation from within the spleen or adjacent pathology. The splenic vasculature demonstrated normal volume without signs of congestion or thrombosis. No sonographic evidence of acute or chronic inflammatory, neoplastic, or infarctual changes were noted.

Liver

The **liver** images submitted revealed subjectively normal liver size, contour, and structure. Parenchymal echogenicity was naturally coarse and hypoechoic to the spleen. Vascular and biliary tracts were of normal volume with no evidence of congestion. The gallbladder presented acceptably thin walls with primarily anechoic content. The cystic and common bile ducts were normal. No pathological hepatic lymphadenopathy was evident. No overt structural evidence of inflammatory, infiltrative or regenerative pathology was evident.

Gastrointestinal

A minor amount of chyme was noted in the **stomach**. No evidence of foreign body. Structurally, the pyloric outflow was unremarkable. The small intestine and colon were empty. Curvilinear patterns were respected.

Pancreas



PATIENT

Benny Bedell

The base and limbs of the **pancreas** were observed to be largely isoechoic to surrounding omental fat. Pancreatic duct and capsular contour were acceptably normal and parenchyma respected normal curvilinear patterns. No overt evidence of active inflammatory or neoplastic disease was noted.

SPECIES

Canine

ULTRASONOGRAPHIC FINDINGS

- Unremarkable abdomen and GI tract

BREED

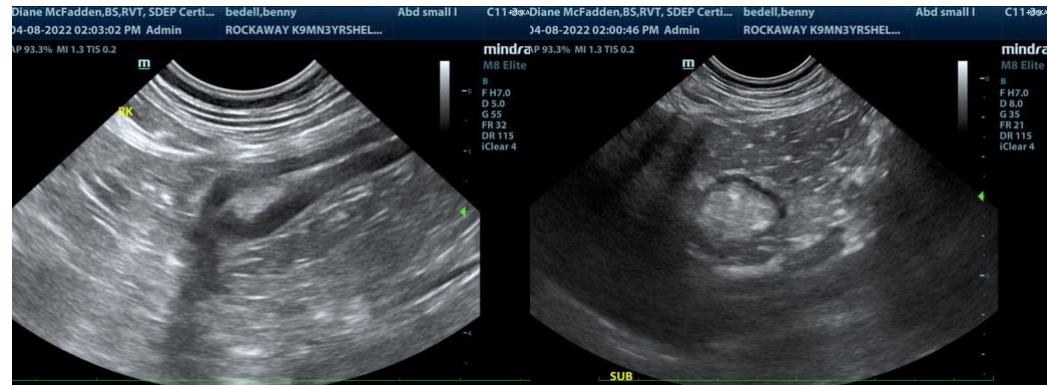
Shetland Sheepdog

INTERPRETATION OF THE FINDINGS & FURTHER RECOMMENDATIONS

Endoscopy indicated, if clinical signs persist. However, transit of chyme appears to adequate in the small intestine and colon. No evidence of structural GI disease.

SEX

Neutered Male



AGE

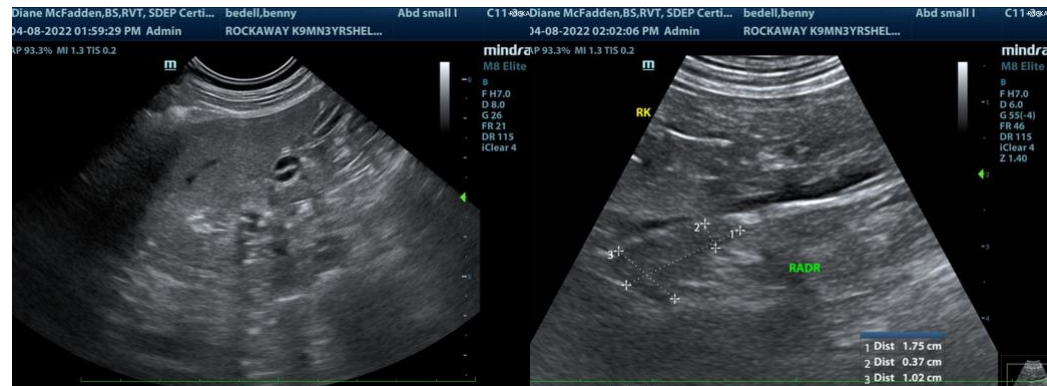
3 Years

WEIGHT

25.5 Pounds

INTERPRETED BY

Eric Lindquist, DMV
DABVP, Cert. IVUSS

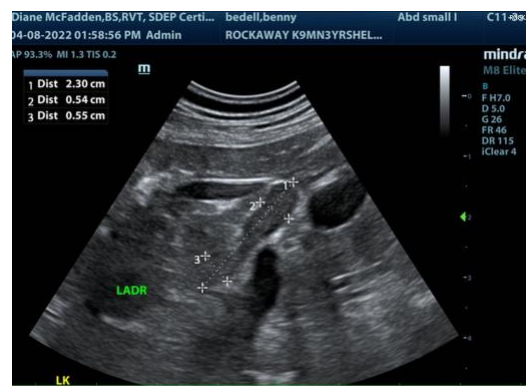

IMAGING PERFORMED BY

Diane McFadden

HOSPITAL NAME

Rockaway AH



REFERRING VET

Dr. Maniar

INVOICE

14659

DATE

4/8/22

The information and recommendations provided are based on the images presented by the



PATIENT

Benny Bedell

referring veterinarian. No evaluation can be communicated regarding pathology that was not visible in the image/video clips provided.

SPECIES

Canine

Thank you for this referral. If the clinical or image interpretation does not parallel your findings or if I can be of any further assistance please contact me.

BREED

Shetland Sheepdog

Eric Lindquist, DMV, DABVP, Cert. IVUSS, CEO of SonoPath.com
info@SonoPath.com

SEX

Neutered Male

AGE

3 Years

WEIGHT

25.5 Pounds

INTERPRETED BY

Eric Lindquist, DMV
DABVP, Cert. IVUSS

IMAGING PERFORMED BY

Diane McFadden

HOSPITAL NAME

Rockaway AH

REFERRING VET

Dr. Maniar

INVOICE

14659

DATE

4/8/22