



PATIENT

Rani Nandurkar

SPECIES

Canine

BREED

Miniature Schnauzer

SEX

Spayed Female

AGE

14 Years

WEIGHT

15.5 lbs

INTERPRETED BY

Eric Lindquist, DMV,
 DABVP (CFM), Cert.
 IVUSS

IMAGING PERFORMED BY

Ginny Dodd, DVM, D,
 ABVP-CFP

HOSPITAL NAME

Down Dog Veterinary
 Clinic

REFERRING VET

Dr. Jennifer Kimmel

INVOICE

74271

DATE

4/7/26

PRESENTING CLINICAL SIGNS

Chronic diarrhea, vomiting, borborygmus, inappetence, and weight loss- 5 # in past year. Multiple medications and diet changes have not consistently helped.

Abnormal PE/Chem/CBC/UA Results: CBC- wnl; Chem/T45- mild ALP elevation; creatinine low, UA-normal GI panel- pending Oral Trazadone this AM; Torb 1 mg and enalpha IM 15 min ago

ULTRASONOGRAPHIC EXAMINATION OF THE ABDOMEN

Urinary System

The **urinary bladder**, trigone, and pelvic urethra presented normal thicknesses and normal tone. The ureters were not visible which is normal. No uroliths or sediment were visualized and anechoic urine was present. No evidence of inflammatory or neoplastic changes were noted. Ureteral papillae were normal. The pelvic urethra was imaged 2.0 cm beyond the cystourethral junction.

The **kidneys** revealed largely normal size and structure, corticomedullary definition and ratio (cortex 1/3 of medulla) were essentially maintained with some age-related loss of curvilinear patterns regarding the capsule and C/M junction. The cortices presented largely uniform texture with some increased echogenicity expected for his age patient. Medullary structure differed distinctly from that of the cortex and no evidence of pelvic dilation was present. Left kidney measured 3.8 cm. Right kidney measured 3.85 cm.

Adrenal Glands

Both **adrenal glands** were visualized and recognized as having normal shape, size, position and echogenicity for this breed. The phrenic vasculature, glandular echogenicity and detail were unremarkable. Capsule, cortex, and medullary definition were normal for this age patient. Right measured 1.55 cm x 0.57 cm at the caudal pole and 0.48 cm at the cranial pole. Left measured 1.62 cm x 0.43 cm at the cranial pole and 0.43 cm at the caudal pole.

Spleen

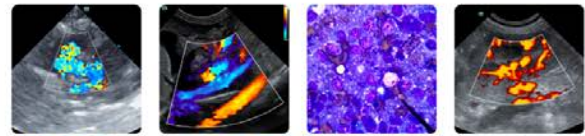
The **spleen** revealed a hyperechoic nodule at the mid body measuring 1.5 cm x 0.90 cm. Other heterogeneous changes noted without overt mass formation.

Liver

The **liver** images from right and left intercostal as well as subcostal views revealed subjectively normal liver size, contour, and structure. Some age-related parenchymal remodeling was noted but likely not clinically significant at this time. Vascular and biliary tracts were of normal volume and no evidence of congestion was noted. The gallbladder presented some dependent debris with essentially normal contour. The cystic and common bile ducts were normal. No overt evidence of active inflammatory, infiltrative or regenerative pathology was noted but should be paired with current or past LE elevations regarding any clinical significance to this presentation. The hepatic lymph nodes were unremarkable.

Gastrointestinal

Examination of the **gastrointestinal tract** revealed a stomach and intestine free of stasis, of normal wall thickness, acceptable curvilinear mural detail, and peristaltic activity. Small and large intestine demonstrated normal luminal chyme and stool consistency respectively. No obstructive or overt infiltrative disease was noted. No associated abnormal lymphatic activity was noted.



PATIENT

Rani Nandurkar

SPECIES

Canine

BREED

Miniature Schnauzer

SEX

Spayed Female

AGE

14 Years

WEIGHT

15.5 lbs

INTERPRETED BY

Eric Lindquist, DMV,
 DABVP (CFM), Cert.
 IVUSS

IMAGING PERFORMED BY

Ginny Dodd, DVM, D,
 ABVP-CFP

HOSPITAL NAME

Down Dog Veterinary
 Clinic

REFERRING VET

Dr. Jennifer Kimmel

INVOICE

74271

DATE

4/7/26

Pancreas

The base and limbs of the **pancreas** were observed to be largely isoechoic to surrounding omental fat. Pancreatic duct and capsular contour were acceptably normal and parenchyma respected normal curvilinear patterns. No overt evidence of active inflammatory or neoplastic disease was noted.

Other

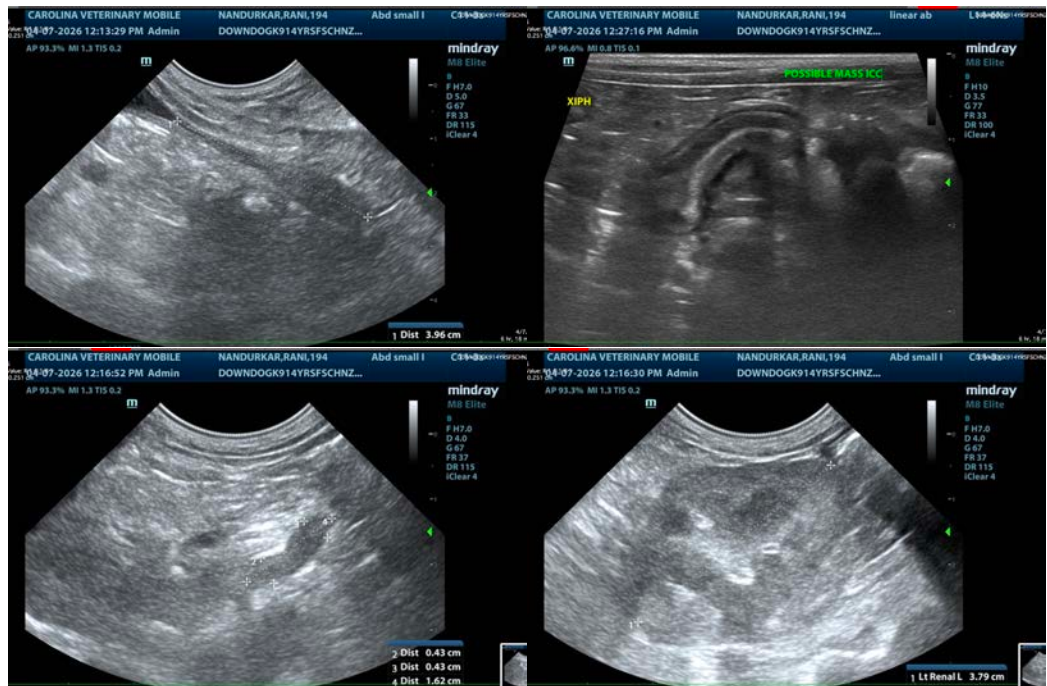
Rapid view of the heart revealed no evidence of pathology in the right auricle or pericardium.

ULTRASONOGRAPHIC FINDINGS

- Splenic lipid plaques and heterogeneous changes.
- Age related renal and hepatic changes.

INTERPRETATION OF THE FINDINGS & FURTHER RECOMMENDATIONS

Geriatric abdomen. No evidence of specific disease. Largely expected changes for this age patient. The cause of weight loss is unclear. Maldigestion panel, three view chest radiographs and full CNS examination is recommended to examine for occult disease that could be responsible for the weight loss. Evaluation for competitive eating environments should also be considered.





PATIENT

Rani Nandurkar

SPECIES

Canine

BREED

Miniature Schnauzer

SEX

Spayed Female

AGE

14 Years

WEIGHT

15.5 lbs

INTERPRETED BY

Eric Lindquist, DMV,
 DABVP (CFM), Cert. IVUSS

IMAGING PERFORMED BY

Ginny Dodd, DVM, D,
 ABVP-CFP

HOSPITAL NAME

Down Dog Veterinary
 Clinic

REFERRING VET

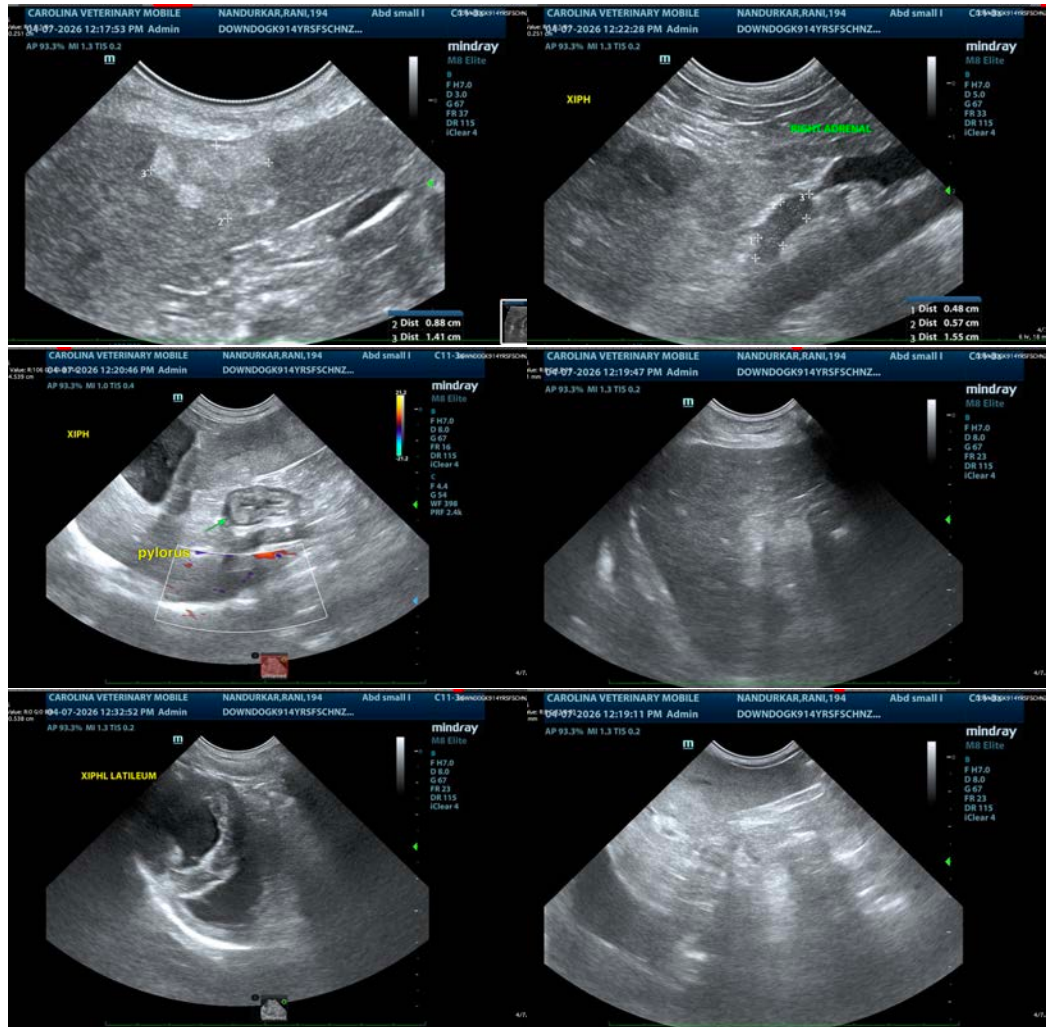
Dr. Jennifer Kimmel

INVOICE

74271

DATE

4/7/26



The information and recommendations provided are based on the images presented by the referring veterinarian/sonographer. No evaluation can be communicated regarding pathology that was not visible in the image/video clips provided.

Thank you for this referral. If the clinical or image interpretation does not parallel your findings or if I can be of any further assistance please contact me.

Eric Lindquist, DMV, DABVP(CFM), Cert. IVUSS,
 CEO, Owner, Founder -- SonoPath.com
info@SonoPath.com