



PATIENT

Jet Holderness

SPECIES

Canine

BREED

Terrier Cross

SEX

Spayed female

AGE

12 years

WEIGHT

15.6 lbs

INTERPRETED BY

Eric Lindquist, DMV
DABVP, Cert. IVUSS

IMAGING PERFORMED BY

Gudrun Gunther

HOSPITAL NAME

New Frontier Animal
Medical Center

REFERRING VET

Dr. Gunther

INVOICE

74275

DATE

4/7/26

PRESENTING CLINICAL SIGNS

- Monitoring Echo (last echo 4/1/25) - asymptomatic
- Monitoring Abdominal Ultrasound - post liver lobectomy in April 2025 for a well differentiated hepatocellular carcinoma
- Bladder polyp diagnosed 11/26/25 - BRAF Negative
- Thoracic rads unremarkable

ULTRASONOGRAPHIC EXAMINATION OF THE ABDOMEN

Urinary System

The **urinary bladder**, trigone, and pelvic urethra presented normal thicknesses and normal tone. The ureters were not visible which is normal. No uroliths or sediment were visualized and anechoic urine was present. No evidence of inflammatory or neoplastic changes was noted. Ureteral papillae were normal.

The **kidneys** revealed largely normal size and structure, corticomedullary definition and ratio (cortex 1/3 of medulla) were essentially maintained with some age-related loss of curvilinear patterns regarding the capsule and C/M junction. The cortices presented largely uniform texture with some increased echogenicity expected for this age patient. Medullary structure differed distinctly from that of the cortex. Minor microcystic cortical changes were noted. Slight mineralization was noted in both kidneys. The right kidney measured 5.12 cm. The left kidney measured 5.01 with pyelectasia that measured 0.3 cm. Blood flow to the kidneys appeared to be mildly subnormal on Power Doppler assessment.

Adrenal Glands

Both **adrenal glands** were visualized and recognized as having normal shape, size, position and echogenicity for this breed. The phrenic vasculature, glandular echogenicity and detail were unremarkable. Capsule, cortex, and medullary definition were normal for this age patient. The left adrenal gland measured 2.04 x 0.48 cm at the cranial pole and 0.64 cm at the caudal pole. The right adrenal gland measured 1.41 x 0.5 cm.

Spleen

The **spleen** presented a smooth homogeneous parenchyma hyperechoic to liver and renal cortical parenchyma. The capsule was smooth without noticeable expansion or deviation from within the spleen or adjacent pathology. The splenic vasculature demonstrated normal volume without signs of congestion or thrombosis. No sonographic evidence of acute or chronic inflammatory, neoplastic, or infarctual changes was noted.

Liver

The **liver** revealed coarse architecture with increased portal markings. Isoechoic, non-disruptive nodular changes were noted. Normal size and vascularity was noted. Vascular and biliary tracts were of



PATIENT

Jet Holderness

SPECIES

Canine

BREED

Terrier Cross

SEX

Spayed female

AGE

12 years

WEIGHT

15.6 lbs

INTERPRETED BY

Eric Lindquist, DMV
DABVP, Cert. IVUSS

IMAGING PERFORMED BY

Gudrun Gunther

HOSPITAL NAME

New Frontier Animal
Medical Center

REFERRING VET

Dr. Gunther

INVOICE

74275

DATE

4/7/26

normal volume with no evidence of congestion. The gallbladder presented acceptably thin walls with primarily anechoic content. The cystic and common bile ducts were normal. No pathological hepatic lymphadenopathy was evident. No overt structural evidence of inflammatory, infiltrative or regenerative pathology was evident.

Gastrointestinal

Examination of the **gastrointestinal tract** revealed a stomach and intestine free of stasis, of normal wall thickness, acceptable curvilinear mural detail, and peristaltic activity. Small and large intestine demonstrated normal luminal chyme and stool consistency respectively. No obstructive or overt infiltrative disease was noted. No associated abnormal lymphatic activity was noted.

Pancreas

The base and limbs of the **pancreas** were observed to be largely isoechoic to surrounding omental fat. Pancreatic duct and capsular contour were acceptably normal and parenchyma respected normal curvilinear patterns. No overt evidence of active inflammatory or neoplastic disease was noted.

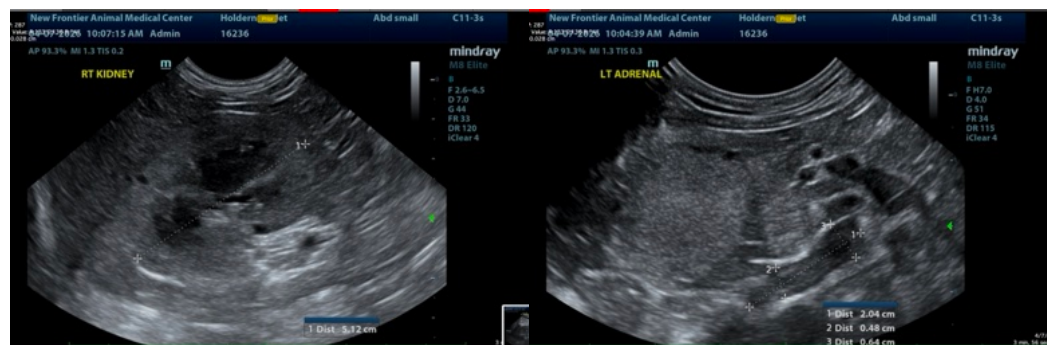
ULTRASONOGRAPHIC FINDINGS

Mild to moderate hepatic remodeling. There was no evidence of return of neoplasia.

Benign hepatopathy, stable geriatric abdomen with hepatic and renal remodeling.

INTERPRETATION OF THE FINDINGS & FURTHER RECOMMENDATIONS

No specific therapy is recommended at this time.





PATIENT

Jet Holderness

SPECIES

Canine

BREED

Terrier Cross

SEX

Spayed female

AGE

12 years

WEIGHT

15.6 lbs

INTERPRETED BY

Eric Lindquist, DMV
DABVP, Cert. IVUSS

IMAGING PERFORMED BY

Gudrun Gunther

HOSPITAL NAME

New Frontier Animal
Medical Center

REFERRING VET

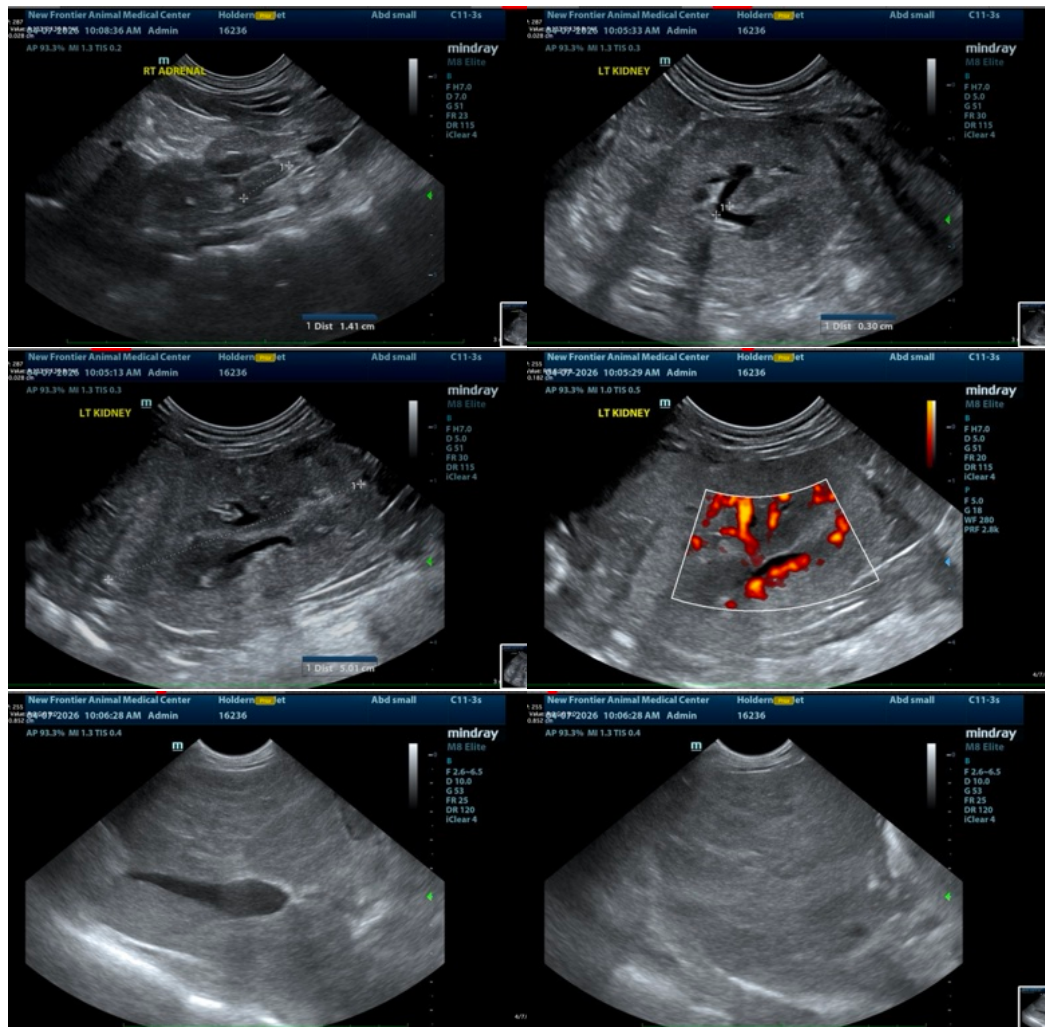
Dr. Gunther

INVOICE

74275

DATE

4/7/26



The information and recommendations provided are based on the images presented by the referring veterinarian/sonographer. No evaluation can be communicated regarding pathology that was not visible in the image/video clips provided.

Thank you for this referral. If the clinical or image interpretation does not parallel your findings or if I can be of any further assistance please contact me.

Eric Lindquist, DMV, DABVP (CFM), Cert. IVUSS, CEO of SonoPath.com

info@SonoPath.com