



PATIENT

Ginger Coble

SPECIES

Canine

BREED

Cocker Spaniel

SEX

Spayed female

AGE

15 years

WEIGHT

27.7 lbs

INTERPRETED BY

Eric Lindquist, DMV
DABVP, Cert. IVUSS

IMAGING PERFORMED BY

Jenny Wenrich

HOSPITAL NAME

Straley VA

REFERRING VET

Dr. Shapira

INVOICE

74269

DATE

4/7/26

PRESENTING CLINICAL SIGNS

- No clinical signs, abnormal pre-anesthetic bloodwork prompted recommendation for abdominal ultrasound (see below) to assess pancreas
- CBC: neutrophilic leukocytosis, Chemistry: elevated amylase and lipase which have historically been elevated

ULTRASONOGRAPHIC EXAMINATION OF THE ABDOMEN

Urinary System

The **urinary bladder**, trigone, and pelvic urethra presented normal thicknesses and normal tone. The ureters were not visible which is normal. No uroliths or sediment were visualized and anechoic urine was present. No evidence of inflammatory or neoplastic changes was noted. Ureteral papillae were normal.

The **kidneys** revealed normal size and structure, corticomedullary definition and ratio for this age. The cortices presented largely uniform texture with normal echogenic relationship to liver and spleen. Medullary structure differed distinctly from the cortex and no evidence of pelvic dilation was present. The capsules were acceptably uniform without significant irregularities. Slight, pinpoint mineralization was noted in both kidneys. The left kidney measured 4.5 cm. The right kidney measured 5.5 cm.

Adrenal Glands

Both **adrenal glands** were visualized and recognized as having normal shape, size, position and echogenicity for this breed. The phrenic vasculature, glandular echogenicity and detail were unremarkable. Capsule, cortex, and medullary definition were normal for this age patient. The left adrenal gland measured 0.57 cm. The right adrenal gland was visualized obliquely and measured 0.5 cm.

Spleen

The **spleen** presented a smooth homogeneous parenchyma hyperechoic to liver and renal cortical parenchyma. The capsule was smooth without noticeable expansion or deviation from within the spleen or adjacent pathology. The splenic vasculature demonstrated normal volume without signs of congestion or thrombosis. No sonographic evidence of acute or chronic inflammatory, neoplastic, or infarctual changes was noted.

Liver

The **liver** images submitted revealed subjectively normal liver size, contour, and structure. Parenchymal echogenicity was naturally coarse and hypoechoic to the spleen. Vascular and biliary tracts were of normal volume with no evidence of congestion. The gallbladder presented acceptably thin walls with primarily anechoic content. The cystic and common bile ducts were normal. No pathological hepatic lymphadenopathy was evident. No overt structural evidence of inflammatory, infiltrative or regenerative pathology was evident.



PATIENT

Ginger Coble

SPECIES

Canine

BREED

Cocker Spaniel

SEX

Spayed female

AGE

15 years

WEIGHT

27.7 lbs

INTERPRETED BY

Eric Lindquist, DMV
DABVP, Cert. IVUSS

IMAGING PERFORMED BY

Jenny Wenrich

HOSPITAL NAME

Straley VA

REFERRING VET

Dr. Shapira

INVOICE

74269

DATE

4/7/26

Gastrointestinal

Examination of the **gastrointestinal tract** revealed a stomach and intestine free of stasis, of normal wall thickness, acceptable curvilinear mural detail, and peristaltic activity. Small and large intestine demonstrated normal luminal chyme and stool consistency respectively. No obstructive or overt infiltrative disease was noted. No associated abnormal lymphatic activity was noted.

Pancreas

The base and limbs of the **pancreas** were observed to be largely isoechoic to surrounding omental fat. Some parenchymal remodeling, however, with mild deviation from curvilinear normalcy was observed. Pancreatic duct and capsular irregularities were present consistent with age related changes. If pain upon imaging (+ Murphy sign) was present or if the patient is focally painful in subxiphoid palpation then low-grade smoldering chronic pancreatitis should be suspected.

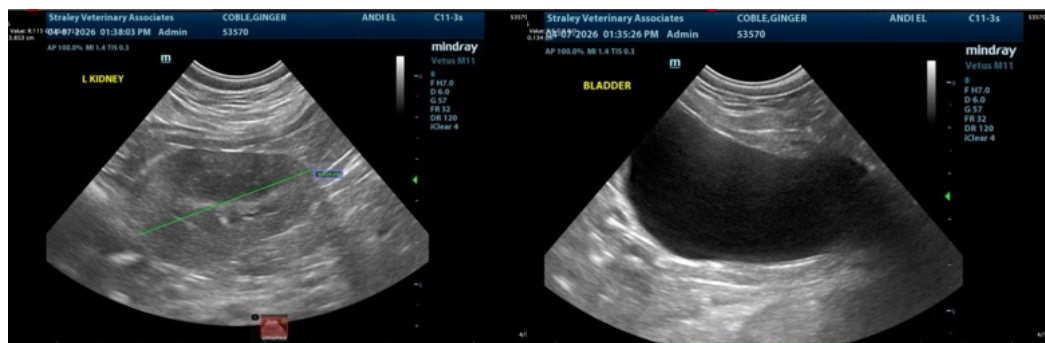
ULTRASONOGRAPHIC FINDINGS

Geriatric abdomen.

Moderate amount of hepatic remodeling.

INTERPRETATION OF THE FINDINGS & FURTHER RECOMMENDATIONS

There was no evidence of specific disease. Bile acid profile would be ideal to ensure that the level of hepatic remodeling does not reflect a functional deficit. Otherwise, there was no over contraindication to anesthetic procedure.





PATIENT

Ginger Coble

SPECIES

Canine

BREED

Cocker Spaniel

SEX

Spayed female

AGE

15 years

WEIGHT

27.7 lbs

INTERPRETED BY

Eric Lindquist, DMV
DABVP, Cert. IVUSS

IMAGING PERFORMED BY

Jenny Wenrich

HOSPITAL NAME

Straley VA

REFERRING VET

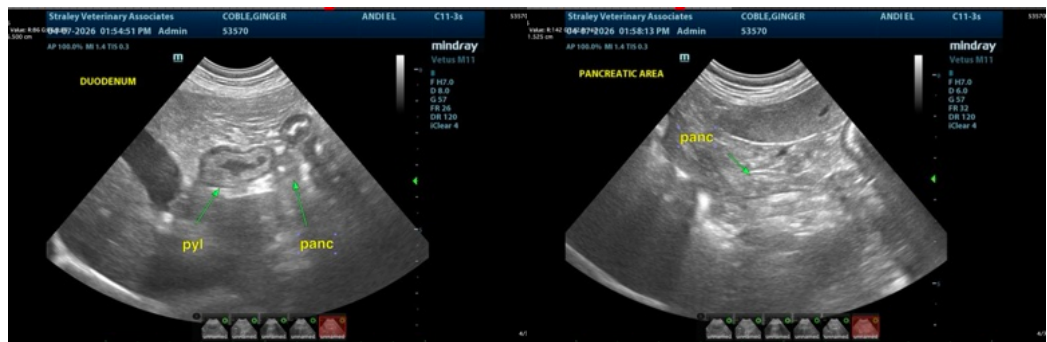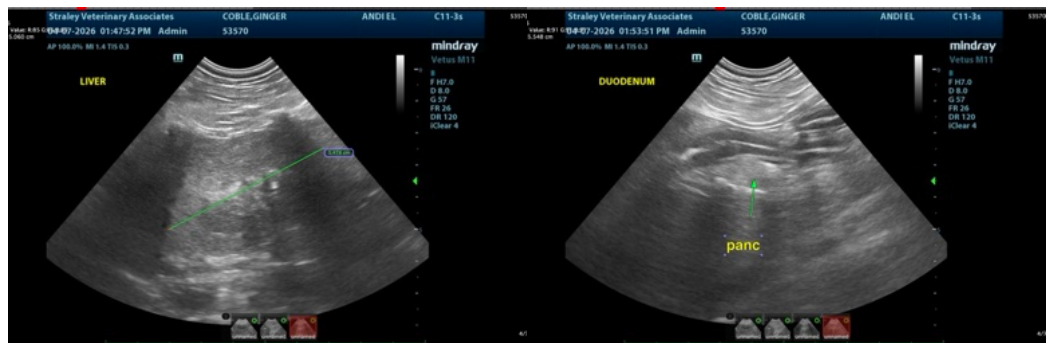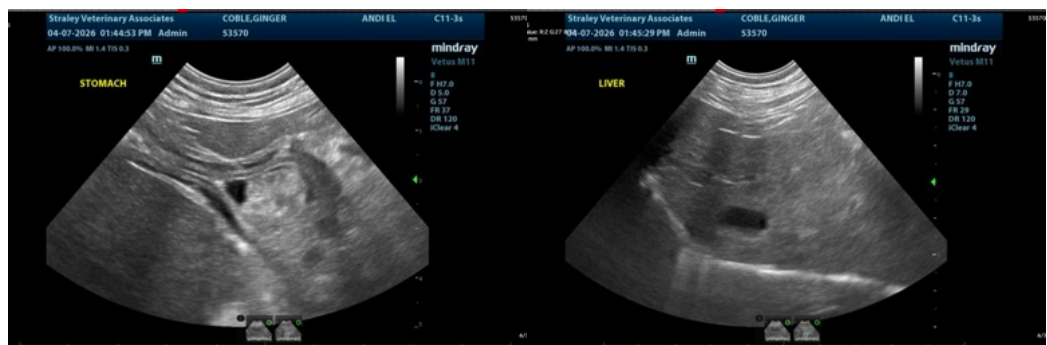
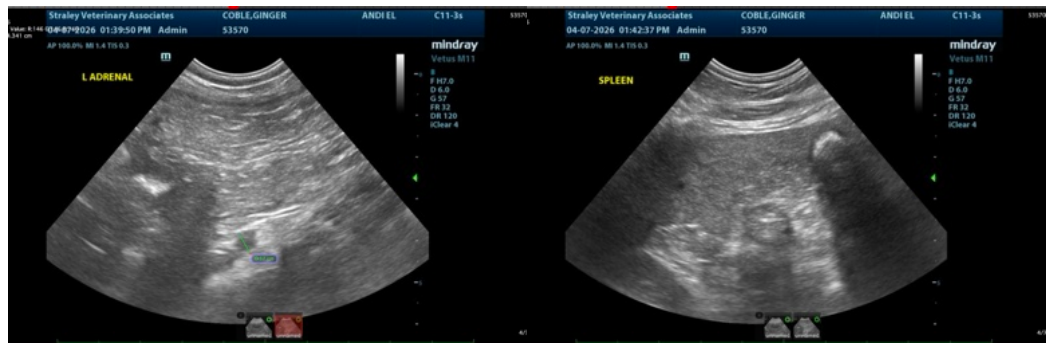
Dr. Shapira

INVOICE

74269

DATE

4/7/26



The information and recommendations provided are based on the images presented by the referring veterinarian/sonographer. No evaluation can be communicated regarding pathology that was not visible in the image/video clips provided.



PATIENT

Ginger Coble

SPECIES

Canine

BREED

Cocker Spaniel

SEX

Spayed female

AGE

15 years

WEIGHT

27.7 lbs

INTERPRETED BY

Eric Lindquist, DMV
DABVP, Cert. IVUSS

**IMAGING
PERFORMED BY**

Jenny Wenrich

HOSPITAL NAME

Straley VA

REFERRING VET

Dr. Shapira

INVOICE

74269

DATE

4/7/26

Thank you for this referral. If the clinical or image interpretation does not parallel your findings or if I can be of any further assistance please contact me.

Eric Lindquist, DMV, DABVP (CFM), Cert. IVUSS, CEO of SonoPath.com

info@SonoPath.com