



PATIENT

Bogdan Harrington

SPECIES

Canine

BREED

King Charles Cavalier
Spaniel

SEX

Neutered male

AGE

10 years

WEIGHT

30.6 lbs

INTERPRETED BY

Eric Lindquist, DMV
DABVP, Cert. IVUSS

IMAGING PERFORMED BY

Susan Lincoski

HOSPITAL NAME

University Drive VH

REFERRING VET

Dr. Lincoski

INVOICE

74274

DATE

4/7/26

PRESENTING CLINICAL SIGNS

- HM grade 4-5/6. Stable but will need recheck echo since starting heart meds about 3 months ago for Stage B-B2 mitral valve disease with minor volume overload (compensated). Currently on enalapril 5mg BID and Vetmedin 5mg 1/2 tablet BID. If all normal, ok to set up dental and oral lump removal.
- Grade 4-5/6 murmur.

ULTRASONOGRAPHIC EXAMINATION OF THE HEAR

The echocardiogram in this patient revealed mitral and tricuspid insufficiency. There was mild volume overload in the left atrium and left ventricle. The right atrium and right ventricle were unremarkable. There was no pericardial or pleural effusion.

CANINE CARDIAC PARAMETERS	MR VMAX (m/s)	TR VMAX (m/s)	LA/AO	LA/AO (Heart Base)	FS (%)	EF (%)	EPSS (cm)
NORMAL PARAMETER	4.5-5.5	<2.7	1.3	<1.6	28-40	40-100	<0.6
PATIENT	None	None	1.4	1.8	50	80	0.1
CANINE CARDIAC PARAMETERS	HR (BPM)	AV VMAX (m/s)	PV MAX (m/s)	BODY WEIGHT	LA 2D short axis Base view (cm)	LVIDd Avg; 2D and m-mode short axis (cm)	LVIDs Avg; 2D and m-mode short axis (cm)
NORMAL PARAMETER	50-100	0.7-1.7	0.7-1.6	BELOW	BELOW	BELOW	BELOW
PATIENT	110	None	None	30.6 lbs	4.7	3.3	

ULTRASONOGRAPHIC FINDINGS

Partially compensated valvular disease.

INTERPRETATION OF THE FINDINGS & FURTHER RECOMMENDATIONS

I recommend adding Spironolactone to the current protocol at 2 mg/kg s.i.d. along with Enalapril and Vetmedin. There is mild anesthetic risk. I recommend Torbutrol pre med, propofol induction and isoflurane maintenance. Monitoring with pulse oximetry, blood pressure measurements and EKG are all recommended. Minimal anesthetic time is indicated. A recheck echocardiogram is recommended in 6 months or earlier if clinical signs initiate.



PATIENT

Bogdan Harrington

SPECIES

Canine

BREED

King Charles Cavalier
Spaniel

SEX

Neutered male

AGE

10 years

WEIGHT

30.6 lbs

INTERPRETED BY

Eric Lindquist, DMV
DABVP, Cert. IVUSS

**IMAGING
PERFORMED BY**

Susan Lincoski

HOSPITAL NAME

University Drive VH

REFERRING VET

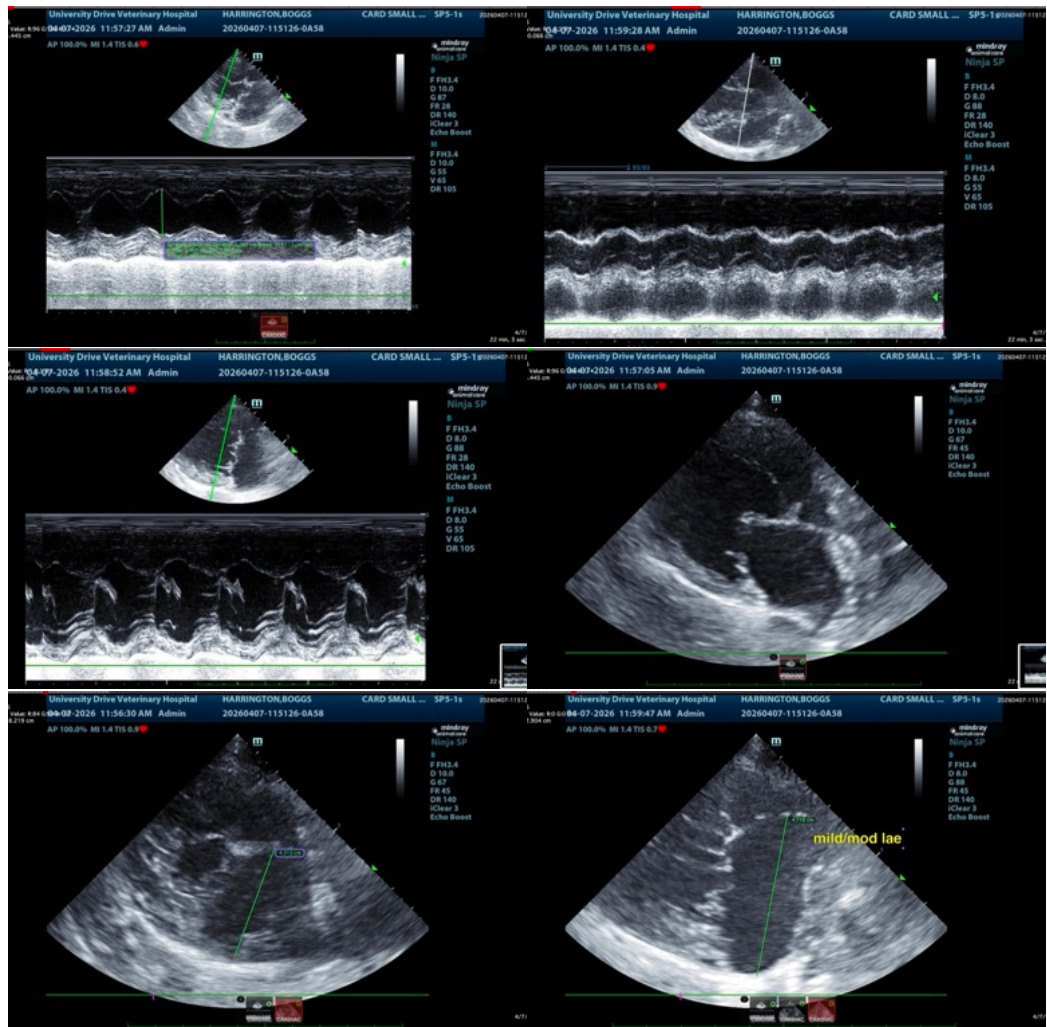
Dr. Lincoski

INVOICE

74274

DATE

4/7/26



The information and recommendations provided are based on the images presented by the referring veterinarian/sonographer. No evaluation can be communicated regarding pathology that was not visible in the image/video clips provided.

Thank you for this referral. If the clinical or image interpretation does not parallel your findings or if I can be of any further assistance please contact me.

Eric Lindquist, DMV, DABVP (CFM), Cert. IVUSS, CEO of SonoPath.com

info@SonoPath.com