



PATIENT

Kevin Rice

PRESENTING CLINICAL SIGNS

History: V/D gastric distention lethargy

SPECIES

Canine

ULTRASONOGRAPHIC EXAMINATION OF THE ABDOMEN

Urinary System

The **urinary bladder**, trigone, and pelvic urethra presented normal thicknesses and normal tone. The ureters were not visible which is normal. No uroliths or sediment were visualized and anechoic urine was present. No evidence of inflammatory or neoplastic changes were noted. Ureteral papillae were normal.

BREED

Russian Blue

SEX

Neutered Male

The **kidneys** presented a relatively uniform cortical hyperechogenicity when compared to the renal medulla, spleen and liver. No overt masses were noted. Corticomedullary definition was nebulous and the ratio favored the cortex slightly. The ureters were not visible and assumed to be normal. These changes are most consistent with chronic interstitial nephritis yet infiltrative disease could not be entirely ruled out without biopsy though neoplasia is not suspected. This is a moderate change. The left kidney measured 3.97 cm. The right kidney measured 4.02 cm. Minor cortical microinfarcts were noted in the right kidney. Blood flow to the kidneys appeared to be subnormal on power doppler assessment.

AGE

12

WEIGHT

8

Adrenal Glands

The regions of the **adrenal glands** revealed no evidence of pathology.

Spleen

The **spleen** presented a smooth homogeneous parenchyma hyperechoic to liver and renal cortical parenchyma. The capsule was smooth without noticeable expansion or deviation from within the spleen or adjacent pathology. The splenic vasculature demonstrated normal volume without signs of congestion or thrombosis. No sonographic evidence of acute or chronic inflammatory, neoplastic, or infarctual changes were noted.

INTERPRETED BY

Eric Lindquist, DMV
DABVP, Cert. IVUSS

IMAGING PERFORMED BY

Jenn

Liver

The **liver** images submitted revealed subjectively normal liver size, contour, and structure. Parenchymal echogenicity was naturally coarse and hypoechoic to the spleen. Vascular and biliary tracts were of normal volume with no evidence of congestion. The gallbladder presented acceptably thin walls with primarily anechoic content. The cystic and common bile ducts were normal. No pathological hepatic lymphadenopathy was evident. No overt structural evidence of inflammatory, infiltrative or regenerative pathology was evident.

HOSPITAL NAME

Rockaway AH

REFERRING VET

Dr. Maniar

Gastrointestinal

Some minor retention of ingesta or hair accumulation was noted in the **stomach**. The small intestine and colon were unremarkable.

INVOICE

21906

Pancreas

The base and limbs of the **pancreas** were observed to be largely isoechoic to surrounding omental fat. Pancreatic duct and capsular contour were acceptably normal and parenchyma respected normal curvilinear patterns. No overt evidence of active inflammatory or neoplastic disease was noted.

DATE

4/7/23



PATIENT

Kevin Rice

SPECIES

Canine

BREED

Russian Blue

SEX

Neutered Male

AGE

12

WEIGHT

8

INTERPRETED BY

Eric Lindquist, DMV
DABVP, Cert. IVUSS

IMAGING PERFORMED BY

Jenn

HOSPITAL NAME

Rockaway AH

REFERRING VET

Dr. Maniar

INVOICE

21906

DATE

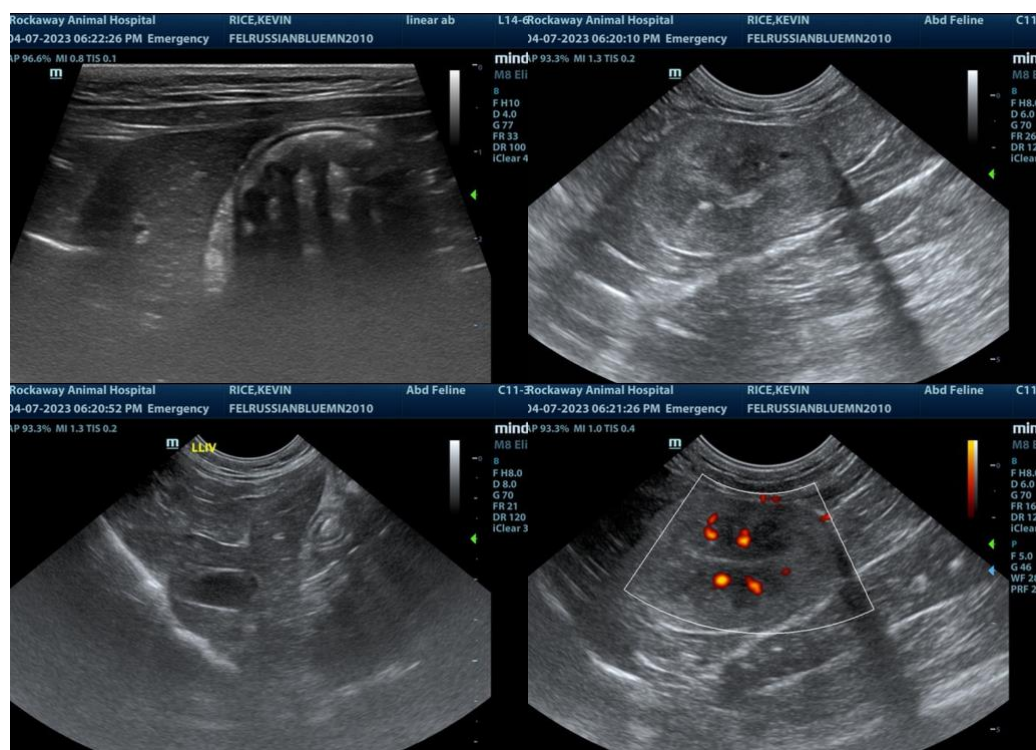
4/7/23

ULTRASONOGRAPHIC FINDINGS

- Moderate degenerative renal disease with minor right microinfarcts and subnormal blood flow to the kidneys
- Unremarkable abdomen otherwise
- Some minor retention of ingesta or hair accumulation in the stomach

INTERPRETATION OF THE FINDINGS & FURTHER RECOMMENDATIONS

No overt cause of the clinical signs was noted. Hairball therapy and supportive GI care is indicated.



The information and recommendations provided are based on the images presented by the referring veterinarian. No evaluation can be communicated regarding pathology that was not visible in the image/video clips provided.

Thank you for this referral. If the clinical or image interpretation does not parallel your findings or if I can be of any further assistance please contact me.

Eric Lindquist, DMV, DABVP, Cert. IVUSS, CEO of SonoPath.com
info@SonoPath.com