

PATIENT

Bob Marley Silva

SPECIES

Canine

BREED

Golden Retriever

SEX

Male

AGE

12 Years

WEIGHT

98 Pounds

INTERPRETED BY

Eric Lindquist, DMV
DABVP, Cert. IVUSS

IMAGING PERFORMED BY

Byron Cabrera

HOSPITAL NAME

All Creatures Great and
Small Denville

REFERRING VET

Llija Mitrovic

INVOICE

21916

DATE

4/7/23

PRESENTING CLINICAL SIGNS

History: hematuria, Stranguria,

Abnormal PE/Chem/CBC/UA Results: U/A sperm, protein 1+

ULTRASONOGRAPHIC EXAMINATION OF THE ABDOMEN

Urinary System

The **urinary bladder** was overdistended. The trigone, and pelvic urethra presented normal thicknesses and normal tone. The ureters were not visible which is normal. No uroliths or sediment were visualized and anechoic urine was present. No evidence of inflammatory or neoplastic changes were noted. Ureteral papillae were normal.

Minor heterogenous parenchymal changes were noted in the **prostate**. The prostate measured 4.0 cm. No evidence of neoplasia.

The **kidneys** revealed normal size and structure, corticomedullary definition and ratio for this age. The cortices presented largely uniform texture with normal echogenic relationship to liver and spleen. Medullary structure differed distinctly from the cortex and no evidence of pelvic dilation was present. The capsules were acceptably uniform without significant irregularities. The left kidney measured 7.5 cm. The right kidney measured 7.0 cm.

Adrenal Glands

Both **adrenal glands** were visualized and recognized as having normal shape, size, position and echogenicity for this breed. The phrenic vasculature, glandular echogenicity and detail were unremarkable. Capsule, cortex, and medullary definition were normal for this age patient. The left adrenal gland measured 0.5 cm. The right adrenal gland was visualized obliquely, measuring 0.6 cm at the cranial pole and 0.4 cm at the caudal pole.

Spleen

The **spleen** presented a smooth homogeneous parenchyma hyperechoic to liver and renal cortical parenchyma. The capsule was smooth without noticeable expansion or deviation from within the spleen or adjacent pathology. The splenic vasculature demonstrated normal volume without signs of congestion or thrombosis. No sonographic evidence of acute or chronic inflammatory, neoplastic, or infarctual changes were noted.

Liver

The **liver** images submitted revealed subjectively normal liver size, contour, and structure. Parenchymal echogenicity was naturally coarse and hypoechoic to the spleen. Vascular and biliary tracts were of normal volume with no evidence of congestion. The gallbladder presented acceptably thin walls with primarily anechoic content. The cystic and common bile ducts were normal. No pathological hepatic lymphadenopathy was evident. No overt structural evidence of inflammatory, infiltrative or regenerative pathology was evident.

Gastrointestinal

There was some residual chyme and gas was noted in the **stomach**, yet not pathological. This is consistent with end post prandial presentation. Transit of chyme into the small intestine was normal. Curvilinear patterns were maintained throughout the GI tract. No evidence of pathology. Small and



PATIENT

Bob Marley Silva

large intestine demonstrated normal luminal chyme and stool consistency respectively. No obstructive or overt infiltrative disease was noted. No associated abnormal lymphatic activity was noted.

Pancreas

SPECIES

Canine

The base and limbs of the **pancreas** were observed to be largely isoechoic to surrounding omental fat. Pancreatic duct and capsular contour were acceptably normal and parenchyma respected normal curvilinear patterns. No overt evidence of active inflammatory or neoplastic disease was noted.

BREED

Golden Retriever

ULTRASONOGRAPHIC FINDINGS

SEX

Male

- BPH prostate
- Overdistended urinary bladder
- Partially full stomach
- Unremarkable abdomen otherwise

AGE

12 Years

INTERPRETATION OF THE FINDINGS & FURTHER RECOMMENDATIONS

The prostate is likely the source of the clinical signs. Neutering should prove effective. Otherwise, if neutering is not an option, the following protocol (off-label) may prove effective.

WEIGHT

98 Pounds

Finasteride at 1 mg/kg/day can be utilized as an off-label approach to reducing prostatic size in BPH cases. Coverage for prostatitis would also likely be appropriate with Fluoroquinolone/Baytril or similar. A recheck sonogram is recommended in 3-4 weeks with reassessment of the urinalysis and evaluation of any inflammatory sediment.

INTERPRETED BY

Eric Lindquist, DMV
DABVP, Cert. IVUSS

IMAGING PERFORMED BY

Byron Cabrera

HOSPITAL NAME

All Creatures Great and
Small Denville

REFERRING VET

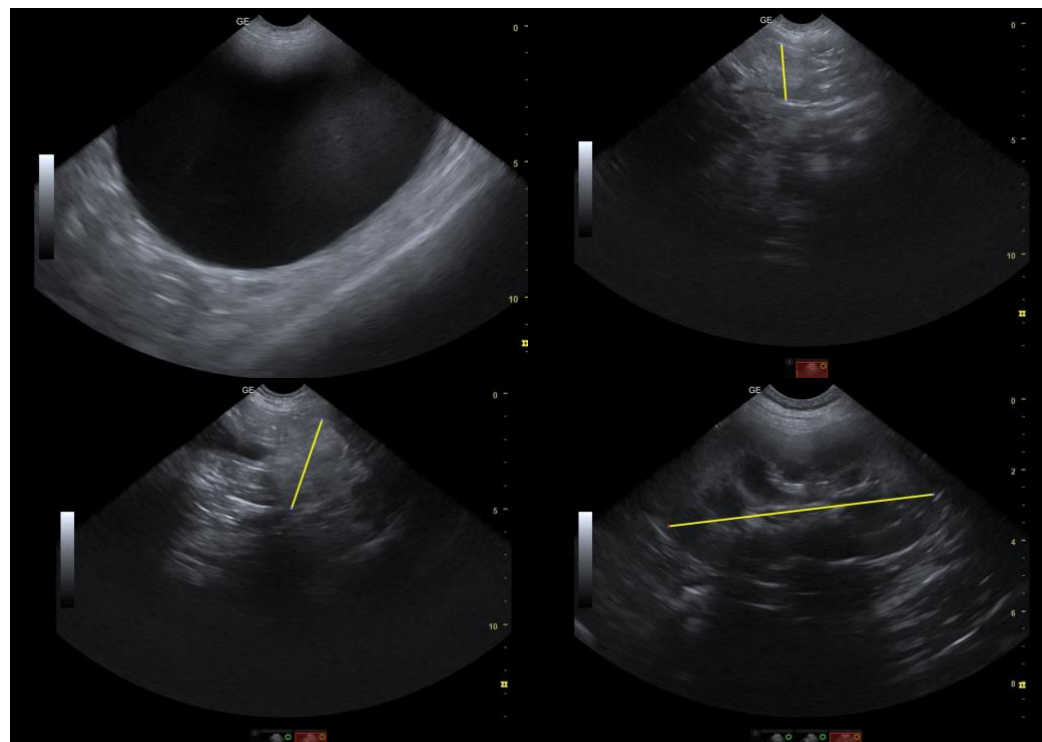
Llija Mitrovic

INVOICE

21916

DATE

4/7/23





PATIENT

Bob Marley Silva

SPECIES

Canine

BREED

Golden Retriever

SEX

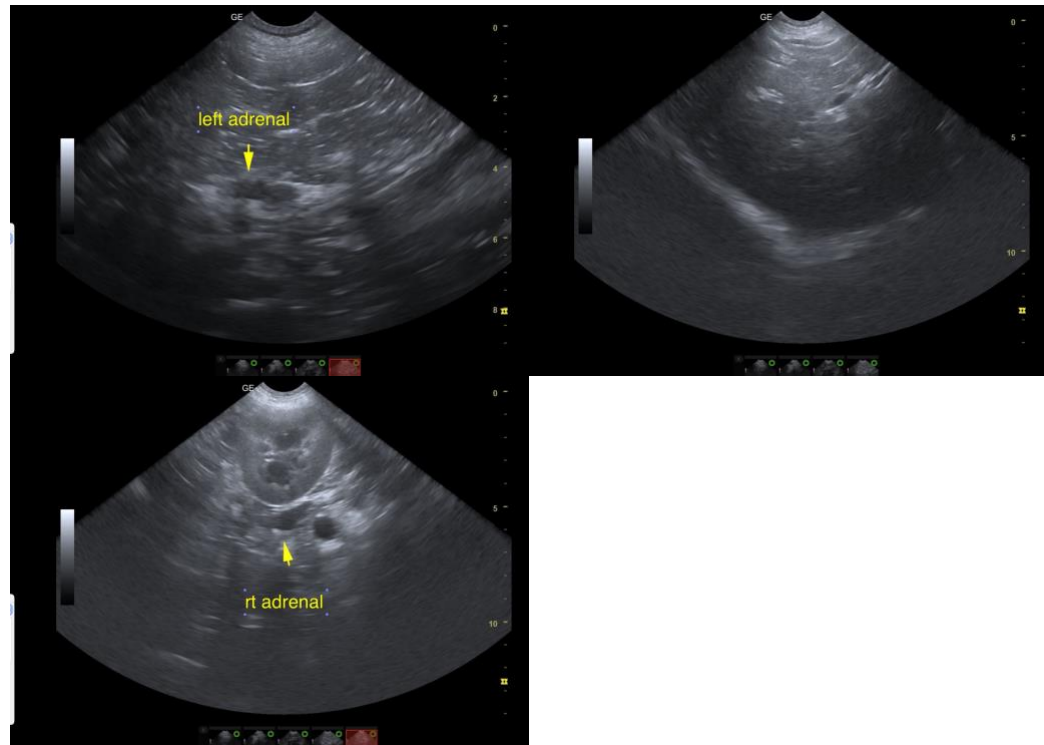
Male

AGE

12 Years

WEIGHT

98 Pounds



INTERPRETED BY

Eric Lindquist, DMV
DABVP, Cert. IVUSS

IMAGING PERFORMED BY

Byron Cabrera

HOSPITAL NAME

All Creatures Great and
Small Denville

REFERRING VET

Llija Mitrovic

INVOICE

21916

DATE

4/7/23

The information and recommendations provided are based on the images presented by the referring veterinarian. No evaluation can be communicated regarding pathology that was not visible in the image/video clips provided.

Thank you for this referral. If the clinical or image interpretation does not parallel your findings or if I can be of any further assistance please contact me.

Eric Lindquist, DMV, DABVP, Cert. IVUSS, CEO of SonoPath.com
info@SonoPath.com