



PATIENT

Regina Lawrence

SPECIES

Feline

BREED

Domestic Medium Hair

SEX

Spayed Female

AGE

2 years

WEIGHT

7.3 lbs

INTERPRETED BY

Eric Lindquist, DMV
DABVP, Cert. IVUSS

IMAGING PERFORMED BY

Shari Reffi, CVT

HOSPITAL NAME

Fredon AH

REFERRING VET

Dr. Grau

INVOICE

98120

DATE

4/7/22

PRESENTING CLINICAL SIGNS

History: Murmur detected on annual exam. O does feel tires easily.
Abnormal PE/Chem/CBC/UA Results: BNP 198

ULTRASONOGRAPHIC EXAMINATION OF THE HEART

The echocardiogram in this patient demonstrated normal **left atrial** size based on 3 separate LA measurements. The cranial and caudal **mitral** valve leaflets presented normal linear structure and kinetics. Minor, concentric **left ventricular** hypertrophy was noted in this patient and is not clinically significant. The **myocardium** presented normal echogenicity without subjective evidence of significant fibrotic or ischemic disease. **Contractility** of the ventricular walls was adequate and in normal range for this patient evidenced by the fractional shortening measurement and subjective evaluation of the different regions and angles of the myocardium. The **left ventricular outflow** tract demonstrated normal laminar flow and subjective structural integrity. The **right atrium** and auricle revealed normal size, structure and content. No evidence of masses was noted or chamber overload. **Tricuspid** valvular assessment demonstrated adequate linear morphology and kinetics. The **right ventricle** was of normal size (1/3 diameter of LV), chordae structure, myocardial echogenicity and thickness. **Pulmonic** tract assessment revealed normal valve structure, laminar flow, and diameter (approx. 1:1 pa/ao ratio). No visible **pericardial** or free pleura fluid was noted or extra cardiac pathology in the visible planes. The cranial **mediastinum** and **pericardial** regions were free of masses in the visible window.

FELINE CARDIAC PARAMETERS	BODY WEIGHT	HR (BPM)	IVSd (cm)	LVIDd (cm)	LVWd (cm)	FS (%)	EF (%)
NORMAL PARAMETER	-----	150-240	0.3-0.6	1.0-2.1	0.25-0.6	35-67	80-100
PATIENT	7.3 lbs	195	0.65	1.1	0.63	50	80
FELINE CARDIAC PARAMETERS	LA/AO (Boon)	LA/AO HEART BASE (Sisson)	LA 2D 4-chamber long axis AS to FW (Sisson) (cm)	LVOT VEL. (m/s)	RVOT VEL. (m/s)	IVRT (m/)	
NORMAL PARAMETER	<1.5	0.88-1.79	0.7-1.7	<1.6	<1.3	40-60	
PATIENT	1.16	1.16		1.3	0.93	NM	

Adapted from June Boon, Veterinary Echocardiography, 1998
Sisson D et al. JVIM 1991; 5: 232, Jacobs et al. Am J Vet Res 1985; 46:1705

ULTRASONOGRAPHIC FINDINGS

Minor for of HCM phenotype.



PATIENT

Regina Lawrence

SPECIES

Feline

BREED

Domestic Medium Hair

SEX

Spayed Female

AGE

2 years

WEIGHT

7.3 lbs

INTERPRETED BY

Eric Lindquist, DMV
DABVP, Cert. IVUSS

IMAGING PERFORMED BY

Shari Reffi, CVT

HOSPITAL NAME

Fredon AH

REFERRING VET

Dr. Grau

INVOICE

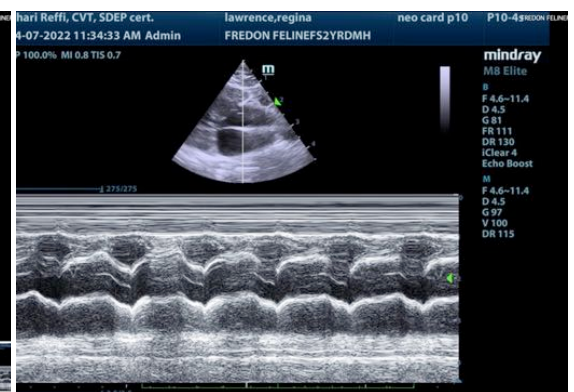
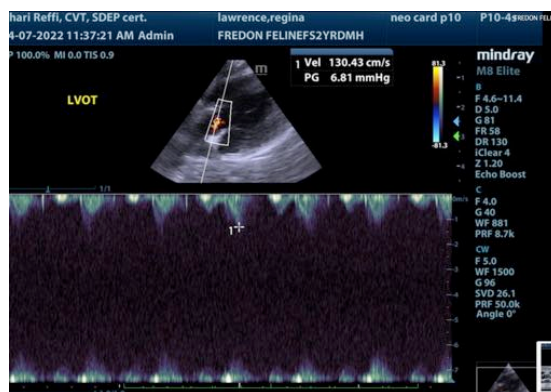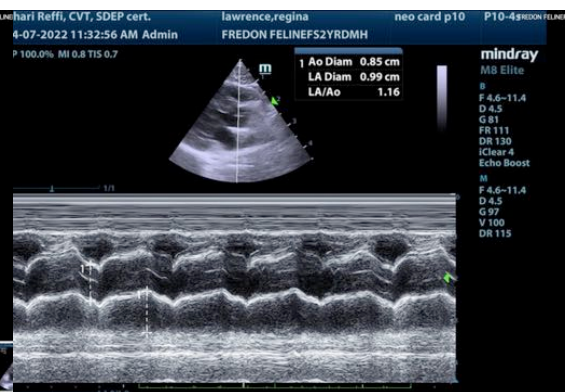
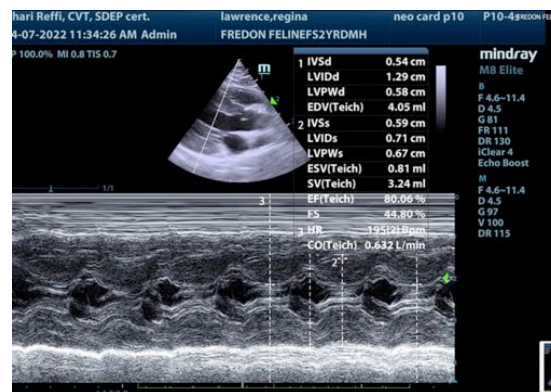
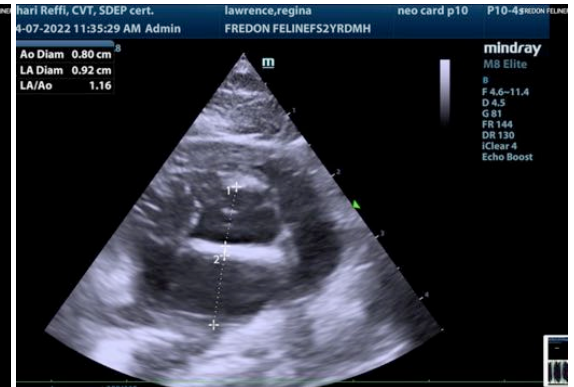
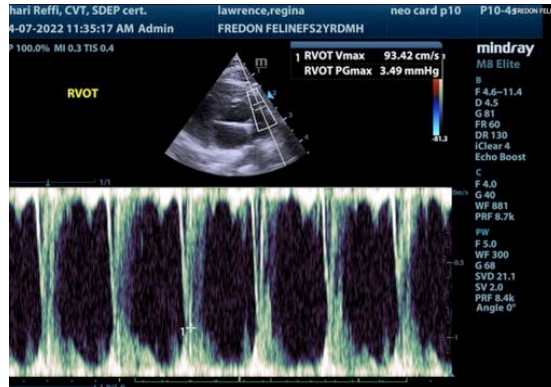
98120

DATE

4/7/22

INTERPRETATION OF THE FINDINGS & FURTHER RECOMMENDATIONS

I do not believe that the reported clinical signs of exercise intolerance is related to the heart. This is a minor form of HCM phenotype, yet not clinically significant. I cannot rule out a paroxysmal arrhythmia in this patient, yet no arrhythmogenic activity was noted at this time. No treatment is warranted at this time. A recheck echocardiogram is recommended in 6-12 months.





PATIENT

Regina Lawrence

SPECIES

Feline

BREED

Domestic Medium Hair

SEX

Spayed Female

AGE

2 years

WEIGHT

7.3 lbs

INTERPRETED BY

Eric Lindquist, DMV
DABVP, Cert. IVUSS

IMAGING PERFORMED BY

Shari Reffi, CVT

HOSPITAL NAME

Fredon AH

REFERRING VET

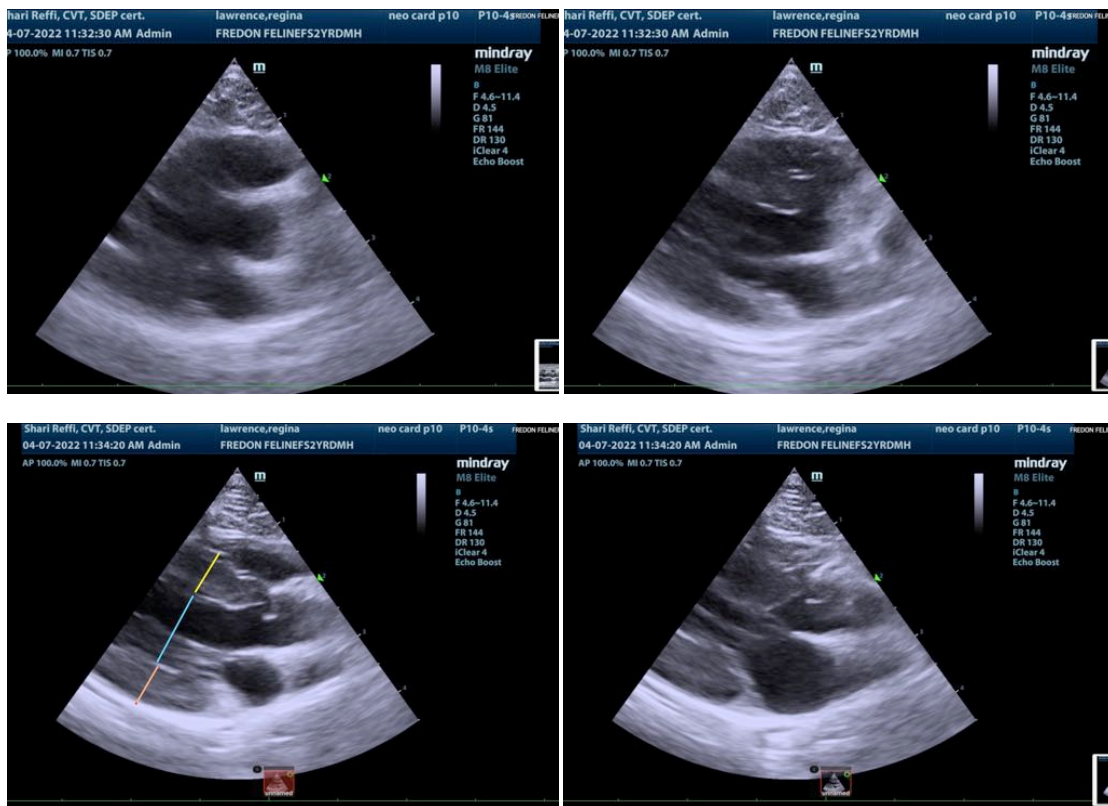
Dr. Grau

INVOICE

98120

DATE

4/7/22



The information and recommendations provided are based on the images presented by the referring veterinarian/sonographer. No evaluation can be communicated regarding pathology that was not visible in the image/video clips provided.

Thank you for this referral. If the clinical or image interpretation does not parallel your findings or if I can be of any further assistance please contact me.

Eric Lindquist, DMV, DABVP, Cert. IVUSS, CEO of SonoPath.com
Info@SonoPath.com