



**PATIENT PRESENTING CLINICAL SIGNS**

Max Lauri History: Recheck cardiac status and right adrenal mass. Current meds: Galliprant and Vetmedin.  
Abnormal PE/Chem/CBC/UA Results: CBC/Chem: WNL.

**SPECIES**

Canine

**ULTRASONOGRAPHIC EXAMINATION OF THE HEART**

**BREED**

Shih Tzu

**SEX**

Neutered male

**AGE**

12 years

**WEIGHT**

21 lbs

The echocardiogram in this patient demonstrated normal **left atrial** size based on 3 different LA measurement methods. Chamber volumes and echogenicity were normal. The cranial and caudal **mitral** valve leaflets presented vegetative thickening consistent with endocardiosis. Doppler indicated measurable insufficiency. The **left ventricle** presented thicknesses with linear contour and was not dilated nor restricted. The **myocardium** presented normal echogenicity without subjective evidence of significant fibrotic or ischemic disease. **Contractility** of the ventricular walls was adequate and in normal range for this patient evidenced by the fractional shortening measurement and subjective evaluation of the different regions of the myocardium. The **left ventricular outflow** tract demonstrated normal laminar flow and subjective structural integrity. The **right atrium** and auricle revealed normal size, structure and content. No evidence of masses was noted or chamber overload. Minor **tricuspid** insufficiency was noted at 2 m/sec. The **right ventricle** was of normal size (1/3 diameter of LV), chordae structure, myocardial echogenicity and thickness. **Pulmonic** tract assessment revealed normal valve structure, laminar flow, and diameter (approx. 1:1 pa/ao ratio). No visible **pericardial** or free pleura fluid was noted. No echographically detectable evidence of infiltrative disease was visible. The cranial **mediastinum** and **pericardial** regions were free of masses in the visible window.

**INTERPRETED BY**

Eric Lindquist, DMV,  
DABVP, Cert. IVUSS,  
CEO of SonoPath.com

**IMAGING PERFORMED BY**

Kelly Vazquez, CVT

**HOSPITAL NAME**

Marsh Hospital for  
Animals

**REFERRING VET**

Dr. Milwicki

CANINE	MR	TR	LA/AO	LA/AO	FS	EF	EPSS
CARDIAC	VMAX	VMAX	(Boon method)	(Heart Base; Swe)	(%)	(%)	(cm)
PARAMETERS	(m/s)	(m/s)					
NORMAL PARAMETER	4.5-5.5	<2.7	1.3	<1.6	28-40	40-100	<0.6
PATIENT	6.0		1.1	1.4	29	58	NM
CANINE	HR	AV	PV	BODY WEIGHT	LA	LVIDd	LVIDs
CARDIAC	(BPM)	VMAX	MAX	(kg)	2D short axis Base view	Avg; 2D and m-mode short axis	Avg; 2D and m-mode short axis
PARAMETERS		(m/s)	(m/s)		(cm)	(cm)	(cm)
NORMAL PARAMETER	50-100	0.7-1.7	0.7-1.6				
PATIENT	122	1.42	0.96	21	2.68 max	2.86	

**INVOICE**

98117

**DATE**

4/7/22



**PATIENT** **ULTRASONOGRAPHIC EXAMINATION OF THE ABDOMEN**

Max Lauri **Urinary System**

**SPECIES** The **urinary bladder**, trigone, and pelvic urethra presented normal thicknesses and normal tone. The pelvic urethra was imaged 3.0 cm beyond the cystourethral junction. The ureters were not visible which is normal. No uroliths or sediment were visualized and anechoic urine was present. No evidence of inflammatory or neoplastic changes was noted. Ureteral papillae were normal.

Canine

**BREED** The residual prostate measured 0.6 cm.

Shih Tzu

**SEX** The **kidneys** revealed normal size and structure, corticomedullary definition and ratio for this age. The cortices presented largely uniform texture with normal echogenic relationship to liver and spleen. Medullary structure differed distinctly from the cortex and no evidence of pelvic dilation was present. The capsules were acceptably uniform without significant irregularities. The right kidney measured 4.82 cm. The left kidney measured 4.48 cm.

Neutered male

**AGE** **Adrenal Glands**

12 years

The right **adrenal gland** has increased in size and measured 2.62 x 2.34 cm with capsular expansion. Mild pericapsular inflammatory pattern was noted. No capsular escape was noted by the right adrenal gland; however, it has increased significantly in size and is moderately vascular. The left adrenal gland was normal in size and contour and measured 1.17 x 0.36 cm at the caudal pole and 0.34 cm at the cranial pole.

**WEIGHT**

21 lbs

**INTERPRETED BY** **Spleen**

Eric Lindquist, DMV,  
DABVP, Cert. IVUSS,  
CEO of SonoPath.com

The **spleen** presented a smooth homogeneous parenchyma hyperechoic to liver and renal cortical parenchyma. The capsule was smooth without noticeable expansion or deviation from within the spleen or adjacent pathology. The splenic vasculature demonstrated normal volume without signs of congestion or thrombosis. No sonographic evidence of acute or chronic inflammatory, neoplastic, or infarctual changes was noted.

**IMAGING PERFORMED BY**

Kelly Vazquez, CVT

**HOSPITAL NAME** **Liver**

Marsh Hospital for  
Animals

The **liver** images from right and left intercostal as well as subcostal views revealed subjectively normal liver size, contour, and structure. Some age-related parenchymal remodeling was noted but likely not clinically significant at this time. The vena cava was free of evident pathology. The gallbladder presented some dependent debris with essentially normal contour. The cystic and common bile ducts were normal. No overt evidence of active inflammatory, infiltrative or regenerative pathology was noted but should be paired with current or past LE elevations regarding any clinical significance to this presentation. The hepatic lymph nodes were unremarkable.

**REFERRING VET**

Dr. Milwicki

**INVOICE**

98117

**Gastrointestinal**

**DATE**

4/7/22

Examination of the **gastrointestinal tract** revealed a stomach and intestine free of stasis, of normal wall thickness, acceptable curvilinear mural detail, and peristaltic activity. Small and large intestine



**PATIENT** demonstrated normal luminal chyme and stool consistency respectively. No obstructive or overt infiltrative disease was noted. No associated abnormal lymphatic activity was noted.

Max Lauri

**SPECIES** *Pancreas*

Canine The base and limbs of the **pancreas** were observed to be largely isoechoic to surrounding omental fat. Pancreatic duct and capsular contour were acceptably normal and parenchyma respected normal curvilinear patterns. No overt evidence of active inflammatory or neoplastic disease was noted.

**BREED**

Shih Tzu

**ULTRASONOGRAPHIC FINDINGS**

**SEX** Compensated mitral insufficiency.

Neutered male Progressive right adrenal gland.

Otherwise, geriatric abdomen.

**AGE**

12 years

**INTERPRETATION OF THE FINDINGS & FURTHER RECOMMENDATIONS**

**WEIGHT**

21 lbs

No adjustment of the current medications are recommended. EKG and blood pressure are warranted. Given the growth of the right adrenal gland I recommend right adrenalectomy. Serial blood pressure measurements +/- urine catecholamine is indicated to assess for pheochromocytoma, adenocarcinoma and adenoma are the main differentials.

**INTERPRETED BY**

Eric Lindquist, DMV, DABVP, Cert. IVUSS, CEO of SonoPath.com

**IMAGING PERFORMED BY**

Kelly Vazquez, CVT

**HOSPITAL NAME**

Marsh Hospital for Animals

**REFERRING VET**

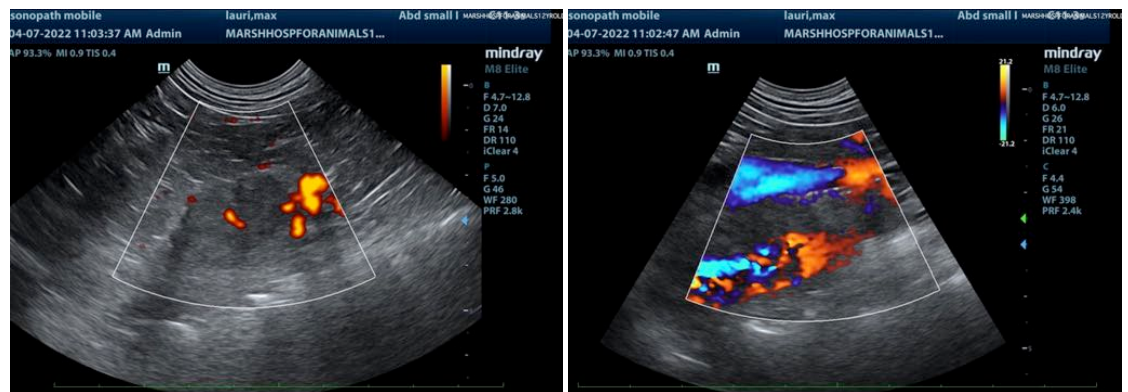
Dr. Milwicki

**INVOICE**

98117

**DATE**

4/7/22





**PATIENT**

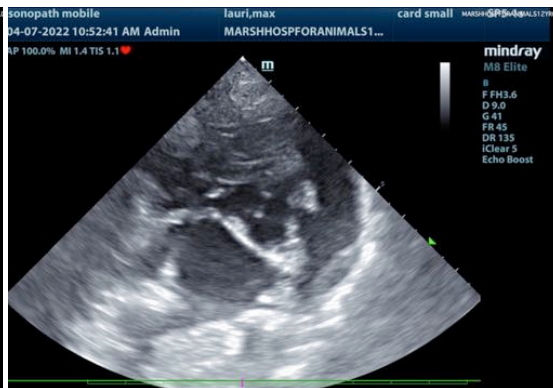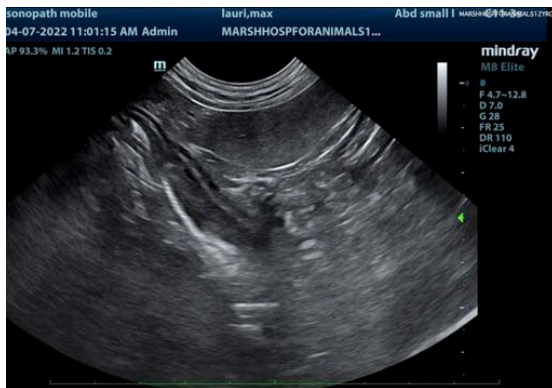Max Lauri

**SPECIES**

Canine

**BREED**

Shih Tzu



**SEX**

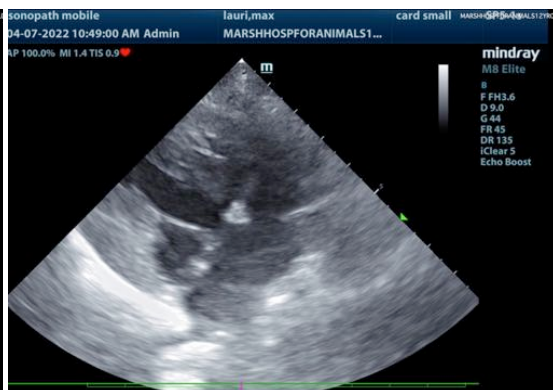
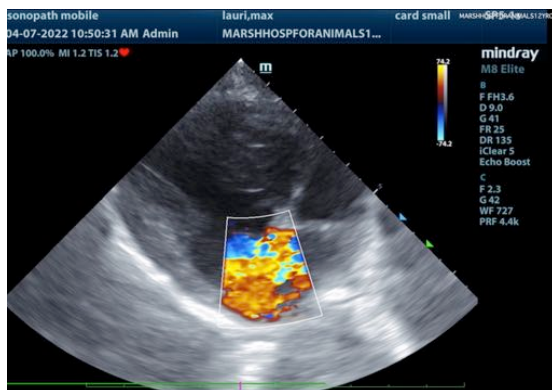
Neutered male

**AGE**

12 years

**WEIGHT**

21 lbs



**INTERPRETED BY**

Eric Lindquist, DMV,  
DABVP, Cert. IVUSS,  
CEO of SonoPath.com

**IMAGING PERFORMED BY**

Kelly Vazquez, CVT

**HOSPITAL NAME**

Marsh Hospital for  
Animals

**REFERRING VET**

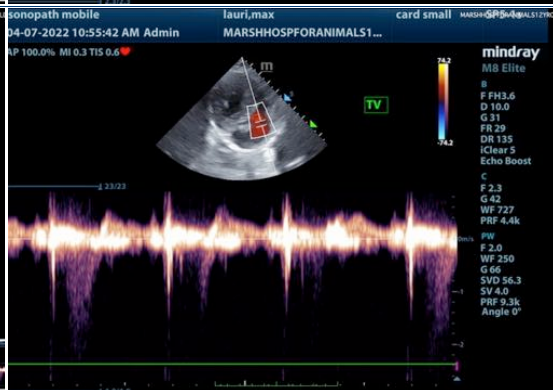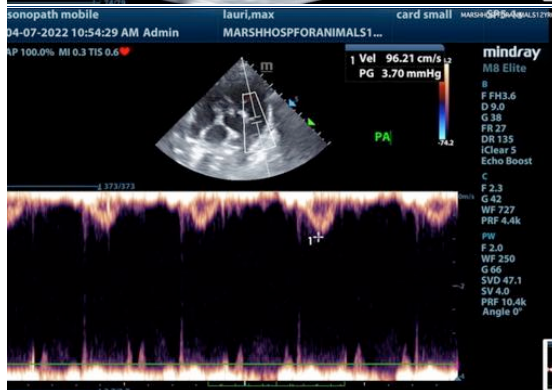
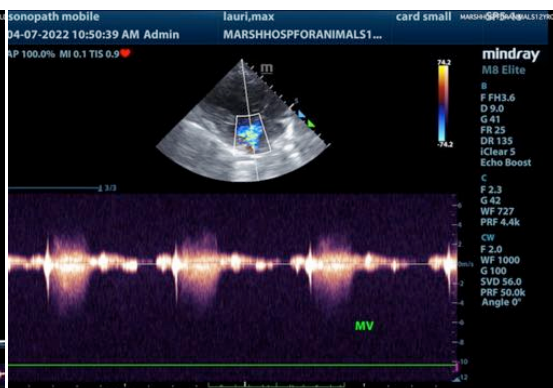
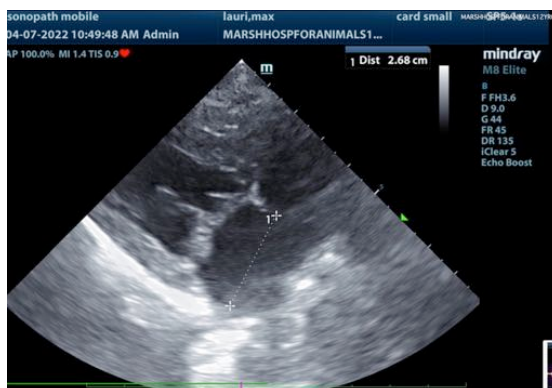Dr. Milwicki

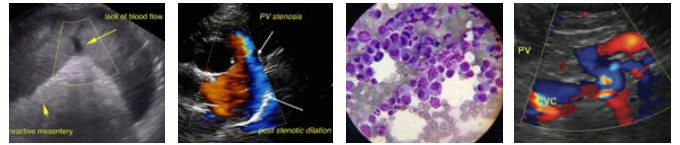
**INVOICE**

98117

**DATE**

4/7/22





**PATIENT**

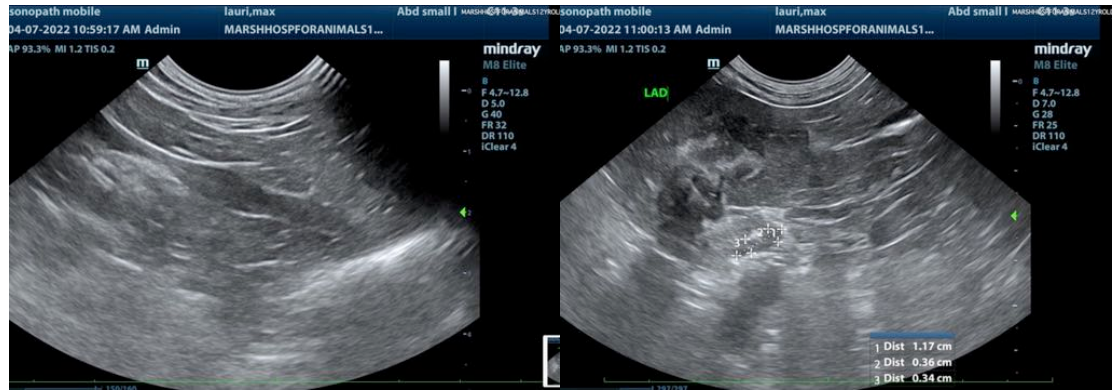
Max Lauri

**SPECIES**

Canine

**BREED**

Shih Tzu



**SEX**

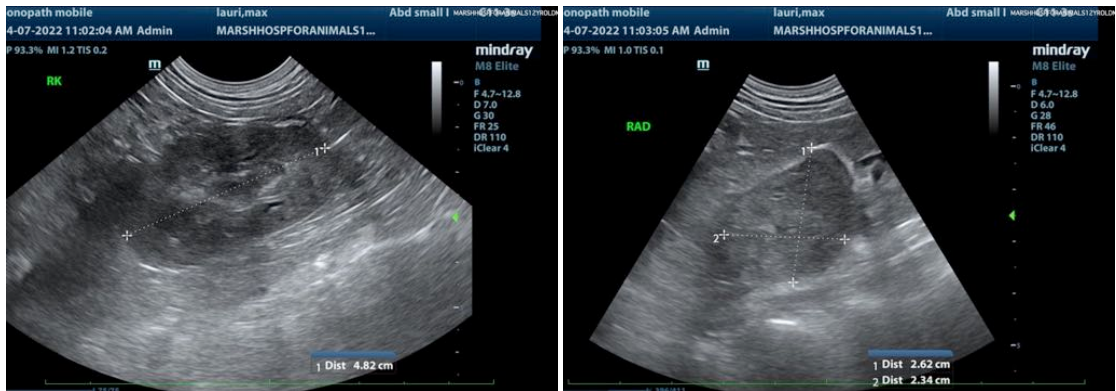
Neutered male

**AGE**

12 years

**WEIGHT**

21 lbs



**INTERPRETED BY**

Eric Lindquist, DMV, DABVP, Cert. IVUSS, CEO of SonoPath.com

**IMAGING PERFORMED BY**

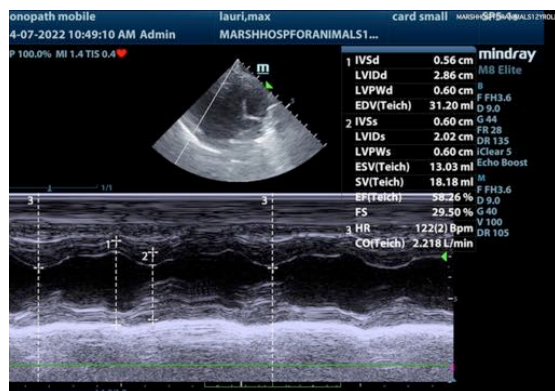
Kelly Vazquez, CVT

**HOSPITAL NAME**

Marsh Hospital for Animals

**REFERRING VET**

Dr. Milwicki



The information and recommendations provided are based on the images presented by the referring veterinarian/sonographer. No evaluation can be communicated regarding pathology that was not visible in the image/video clips provided.

Thank you for this referral. If the clinical or image interpretation does not parallel your findings or if I can be of any further assistance please contact me.

Eric Lindquist, DMV, DABVP, Cert. IVUSS, CEO of SonoPath.com

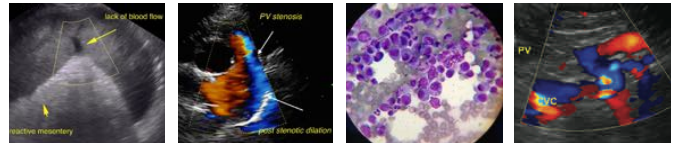
[Info@SonoPath.com](mailto:Info@SonoPath.com)

**INVOICE**

98117

**DATE**

4/7/22



**PATIENT**

Max Lauri

**SPECIES**

Canine

**BREED**

Shih Tzu

**SEX**


Neutered male

**AGE**

12 years

**WEIGHT**

21 lbs



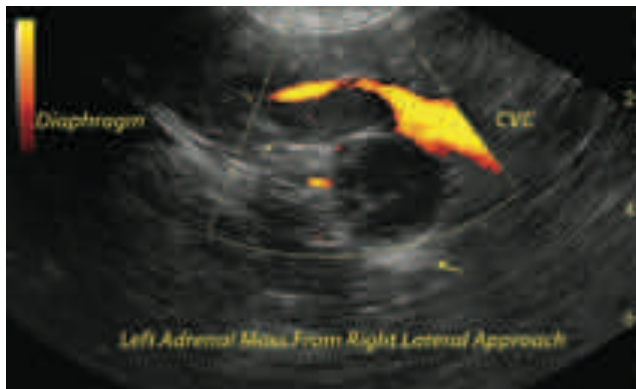
The following is an applicable excerpt from the *Curbside Guide to Diagnosis & Treatment of Sonographic Disease* offered by [SonoPath.com](http://sonopath.com) Lindquist, Frank, Lobetti, and Modler.

An essential quick guide for every general practitioner and sonographer.

<https://sonopath.com/products/curbside-guide-editing-due-release-12012015>

**Adrenal Tumors**

<http://www.sonopath.com/AdrenalTumor>



Long axis of the left adrenal gland using a right lateral approach in a dog with an adrenal adenocarcinoma (larger arrow) and caudal vena cava thrombosis. There is a complex mass lesion within the caudal pole of the adrenal gland and hyperechoic thrombus material (either tumor or mounted thrombus) within the caudal vena cava (between arrows). Note the displacement of the power Doppler signal within the caudal vena cava by the thrombus material.

**INTERPRETED BY**

Eric Lindquist, DMV,  
DABVP, Cert. IVUSS,  
CEO of SonoPath.com

**IMAGING PERFORMED BY**

Kelly Vazquez, CVT

**HOSPITAL NAME**

Marsh Hospital for  
Animals

**REFERRING VET**

Dr. Milwicki

**INVOICE**

98117

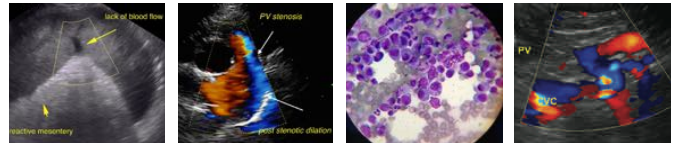
**DATE**

4/7/22

**Description:** An adrenal mass is suspected when the maximum width of the adrenal gland exceeds 1.5 cm, there is loss of normal architecture or shape, or the shape or size between the affected adrenal gland and the contralateral gland is asymmetrical. The latter comprise the initial criteria for diagnosis; however, a bulbous enlargement of the cranial or caudal pole of the adrenal gland is common in dogs with no adrenal pathology and can be misinterpreted as an adrenal mass. If the suspected mass is not precipitating obvious signs (i.e., aggressive behavior), then an abdominal ultrasound should be repeated to confirm that the mass is a consistent finding before pursuing further diagnostics or surgery. Large breeds (Poodles, German Shepherds, Retrievers, and Terriers) and females appear to be overrepresented in the clinical reviews of adrenal tumors. Adrenal tumors in cats are rare with minimal information to characterize the disease. However, adrenal carcinoma and aldosterone producing tumors are the more common adrenal masses in our archived feline population. More specific information regarding this pathology may be found in the Feline Hyperaldosterone chapter.

Incidental adrenal lesions should be investigated clinically if discovered on ultrasound. Non-neoplastic adrenal lesions, such as cysts or granulomas, are very rare in dogs and cats, and the high incidence of metastatic lesions justifies a thorough hormonal screening as well as evaluation for non-adrenal neoplasms. Although incidental adrenal masses may appear to be nonfunctional at the time of diagnosis, it seems more likely that they are in fact subclinically functional. The diagnosis of functional adrenal tumors is discussed below; however, the identification of a nonfunctional, incidental adrenal mass creates a management dilemma.

**Clinical Signs:** Clinical signs attributable to adrenal tumors are dependent on hormone secretion type. Please see below.



**PATIENT**

Max Lauri

**SPECIES**

Canine

**BREED**

Shih Tzu

**SEX**

Neutered male

**AGE**

12 years

**WEIGHT**

21 lbs

**INTERPRETED BY**

Eric Lindquist, DMV,  
DABVP, Cert. IVUSS,  
CEO of SonoPath.com

**IMAGING  
PERFORMED BY**

Kelly Vazquez, CVT

**HOSPITAL NAME**

Marsh Hospital for  
Animals

**REFERRING VET**

Dr. Milwicki

**INVOICE**

98117

**DATE**

4/7/22

**Diagnostics:** Cortical adrenal tumors, such as adenomas and adenocarcinomas, are responsible for 15-20% of hyperadrenocortical cases—what are commonly referred to as adrenal-dependent hyperadrenocortism (ADH)—in dogs. The remaining tumors are the result of pituitary-dependent secretions, which give rise to pituitary-dependent hyperadrenocortism (PDH). PDH cases tend to demonstrate bilateral hypertrophy with excessive adrenal length and, probably more importantly, width. These enlarged adrenal glands do not invade surrounding vascular structures and are defined by overstimulation resulting from excessive ACTH secretion from the pituitary gland. Yet, ADH cases are usually unilateral (bilateral in 10-20% of cases), may invade the aorta on the left or the vena cava on the right, and metastasize to the liver and lungs most frequently. Practitioners must differentiate ADH masses from hyperplastic, non-functional, benign adrenal tumors, as well as pheochromocytomas. Thus, dynamic function tests (ex. LDDS, HDDS, ACTH stimulation, ACTH baseline, urine cortisol-creatinine ratio) are essential, as is conducting routine biochemistry (ALP is elevated in more than 90% of cases) and urinalysis (true polyuria/polydipsia [PU/PD] with USG < 1.020) to determine adequately the need for surgical intervention or aggressive medical therapy. It is important to assess the following: blood pressure for hypertension; oscillating hyper- and hypotensive episodes in cases of pheochromocytomas; urine protein-creatinine ratios; and serum antithrombin III to determine the risk for thromboembolism. Moreover, it is essential to evaluate the entire clinical picture and objective probabilities of possessing a true hyperadrenocortism case. This further entails ruling out other sources of PU/PD, such as primary polydipsia, renal disease, electrolyte abnormalities, infections, and diabetes insipidus or mellitus.

*Malignant or Benign, Functional or Non-Functional: How to Decide?*

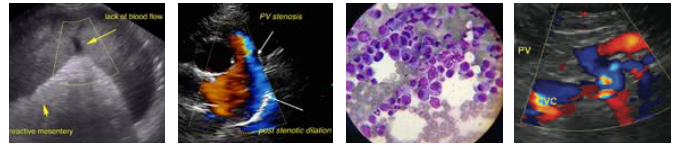
In some cases, it may be difficult to determine whether the mass is malignant or benign, functional or nonfunctional, prior to surgical removal and histopathological examination. A thorough review of the clinical signs, physical examination findings, routine blood work, urine tests, and appropriate hormonal tests should be conducted to determine the functional status of an incidental adrenal mass.

Malignancy is more often associated with larger masses. The larger the mass, the more likely metastasis has already occurred, in spite of a lack of detectable lesions on ultrasound and thoracic radiographs. Invasion of the mass into surrounding organs or blood vessels also supports malignancy, as does the detection of additional mass lesions with abdominal ultrasound and thoracic radiographs. Use of imaging modalities, such as CT and MRI, will likely provide additional data on the characteristics of specific adrenal lesions for use in diagnosis and treatment planning.

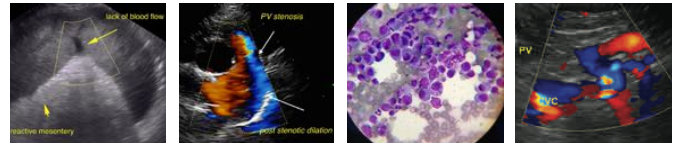
Ultrasonography is the primary instrument for assessing tumor size, aggressiveness, non-capsulated versus capsulated appearance, vascular invasion, and hepatic or other metastasis. Ideally, the patient will have fasted prior to the ultrasound; one may choose to administer an enema to enhance visibility around the ascending and descending colon. Ultrasound-guided biopsy or fine needle aspiration (FNA) may be possible on the larger masses, especially on the left side; however, adjacent vascular structures often prevent the feasibility of this procedure.

*Diagnosis of the Functional Adrenal Mass:*

- **Cortisol-Secreting:** It is very rare that a patient with hyperadrenocortism will have a repeatable urine specific gravity greater than 1.020, so it must be determined whether the patient is truly PU/PD. If yes, then dynamic function testing is appropriate. If the patient is not truly PU/PD, then a false positive result must be considered before treatment is initiated, as the resulting hypoadrenocortism can be life threatening. Other causes of dysuria, such as occult urinary tract infection, must then be considered. The most common functional adrenal tumor identified in dogs and cats results in hyperadrenocortism. Approximately 15% of hyperadrenocortism cases will be caused by a functional adrenal tumor, of which 50% of these will be malignant.
  - Clinical signs can include: PU/PD; polyphagia; abdominal distention; bilaterally symmetrical truncal alopecia; delayed fur regrowth; hyperpigmentation; comedones;



<b>PATIENT</b>	calcinosis cutis; excessive bruising; poor wound healing; ectopic calcification of kidneys and blood vessel walls; pyodermas; muscle weakness; exercise intolerance; hypertension; and panting.
Max Lauri	<ul style="list-style-type: none"> <li>○ Ultrasound usually reveals a small or atrophied contralateral adrenal gland as a result of suppressed pituitary ACTH secretion. Ten to twenty percent of cases have bilateral disease. Adenomas of the adrenal gland are generally less than 2 cm in diameter, and carcinomas can be any size (often they are &gt; 2 cm). Calcification does not appear to be predictive for either adenoma or carcinoma.</li> </ul>
<b>SPECIES</b>	
Canine	<ul style="list-style-type: none"> <li>○ Specific biochemical tests: Urine cortisol-creatinine ratio, ACTH stimulation test, and LDDS test.</li> </ul>
<b>BREED</b>	
Shih Tzu	<ul style="list-style-type: none"> <li>• Catecholamine-Producing: Pheochromocytoma is a tumor derived from the chromaffin cells of the adrenal medulla; it is relatively common in dogs, but quite rare in cats. These cases should be considered malignant until proven otherwise. Invasion/entrapment/compression of the caudal vena cava is common. Mural invasion or luminal narrowing of the aorta, renal vessels, adrenal vessels, and hepatic veins may also occur. <ul style="list-style-type: none"> <li>○ Clinical signs associated with this type of tumor are usually related to the invasion of local structures, metastases, or the secretion of catecholamines. The most common clinical signs of excess catecholamines include generalized weakness, episodic collapse, tachypnea, panting, tachycardia, and cardiac arrhythmias. Catecholamine release and hypertension tends to be episodic; thus, failure to document systemic hypertension does not rule out pheochromocytoma.</li> <li>○ Ultrasound: The contralateral adrenal gland is usually normal in size and shape. Pheochromocytomas do not typically calcify.</li> <li>○ Tests: Many of the clinical signs and blood pressure alterations are similar for pheochromocytoma and ADH. It is therefore important to rule out ADH before focusing on pheochromocytoma. The diagnosis prior to surgery is primarily one of exclusion. Specific hormonal tests, such as those that measure urinary catecholamine concentrations or their metabolites, are not routinely performed.</li> </ul> </li> </ul>
<b>SEX</b>	
Neutered male	
<b>AGE</b>	
12 years	
<b>WEIGHT</b>	
21 lbs	
<b>INTERPRETED BY</b>	
Eric Lindquist, DMV, DABVP, Cert. IVUSS, CEO of SonoPath.com	<ul style="list-style-type: none"> <li>• Aldosterone-Secreting (rare in dogs and cats): <ul style="list-style-type: none"> <li>○ Clinical signs (Conn's Syndrome) are related to excessive secretion of aldosterone, which causes sodium retention and potassium depletion. The resulting symptoms include lethargy, weakness, mild hypernatremia, severe hypokalemia (usually &lt; 3.0 mEq/L), and systemic hypertension.</li> <li>○ Ultrasound usually reveals a normal contralateral adrenal gland.</li> <li>○ Tests: Documenting increased plasma aldosterone concentrations before and after ACTH administration is a means of confirming the diagnosis. If weakness and severe hypokalemia are present, plasma aldosterone concentrations can be measured along with plasma cortisol concentrations during the ACTH stimulation test.</li> </ul> </li> <li>• Progesterone-Secreting: Although a functional tumor arising from the zona reticularis of the adrenal cortex could secrete excessive amounts of estrogen, progesterone, or testosterone, to date only progesterone-secreting adrenocortical tumors in cats have been documented. <ul style="list-style-type: none"> <li>○ Clinical signs include: diabetes mellitus and feline fragile skin syndrome, which is characterized by progressively worsening dermal and epidermal atrophy, patchy endocrine alopecia, and easily torn skin.</li> <li>○ Ultrasound usually reveals a normal contralateral adrenal gland.</li> <li>○ Tests: Diagnosis requires documenting an increased plasma progesterone concentration. The clinical features mimic feline hyperadrenocorticism, which is the primary differential diagnosis. Pituitary-adrenocortical axis test results are normal to suppressed in cats with progesterone-secreting adrenal tumors.</li> </ul> </li> <li>• Deoxycorticosterone-Secreting (rare): <ul style="list-style-type: none"> <li>○ Clinical signs are related to mineralocorticoid activity and include weakness, marked hypokalemia, and systemic hypertension.</li> <li>○ Tests: Increased plasma deoxycorticosterone and non-detectable plasma aldosterone concentrations have been documented in dogs.</li> </ul> </li> </ul>
<b>IMAGING PERFORMED BY</b>	
Kelly Vazquez, CVT	
<b>HOSPITAL NAME</b>	
Marsh Hospital for Animals	
<b>REFERRING VET</b>	
Dr. Milwicki	
<b>INVOICE</b>	
98117	
<b>DATE</b>	
4/7/22	



**PATIENT**

Max Lauri

- 17-OH-progesterone-Secreting (rare):
  - Clinical signs are similar to hyperadrenocorticism.
  - Tests: Pre- and post-ACTH stimulation plasma 17-OH-progesterone concentrations will be increased.

**SPECIES**

Canine

**BREED**

Shih Tzu

**SEX**

Neutered male

**AGE**

12 years

**WEIGHT**

21 lbs

**INTERPRETED BY**

Eric Lindquist, DMV,  
DABVP, Cert. IVUSS,  
CEO of SonoPath.com

**IMAGING PERFORMED BY**

Kelly Vazquez, CVT

**HOSPITAL NAME**

Marsh Hospital for  
Animals

**REFERRING VET**

Dr. Milwicki

**INVOICE**

98117

**DATE**

4/7/22

**Treatment:** If hormonal tests for ADH and serum electrolytes are normal and clinical signs suggestive of pheochromocytoma are present, one can assume the adrenal mass is a pheochromocytoma and begin treatment with an alpha-adrenergic antagonist (ex. phenoxybenzamine at 0.25 mg/kg PO BID initially) for at least 2 weeks to prevent severe clinical manifestations of hypertension and promote a smooth anesthetic induction if adrenalectomy is planned. Adjustments to the dose are based on clinical response; an increase in the dose should be considered if clinical signs do not improve after 2 weeks of treatment. If hormonal tests for ADH and serum electrolyte concentrations are normal, clinical signs suggestive of pheochromocytoma are not present, but an adrenalectomy is nevertheless planned, one should still assume the adrenal mass is a pheochromocytoma and begin phenoxybenzamine treatment prior to adrenalectomy.

When a cortisol-producing adrenal tumor has been documented, medical therapy with trilostane (5-20mg/kg PO Q24hr) or mitotane (25-50 mg/kg PO Q24hr for 10 days, then every 4-7 days) should be considered.

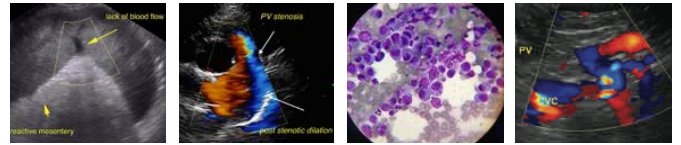
The biggest dilemma is whether to perform an adrenalectomy if hormonal tests for hyperadrenocorticism and serum electrolyte concentrations are normal, and clinical signs and systemic hypertension suggestive of pheochromocytoma are not present.

An aggressive approach—adrenalectomy—is based on the assumption that the mass is malignant until proven otherwise and should be removed before metastasis has occurred. In theory, this approach would offer the best chance for long-term survival; however, the age of the patient, the size of the mass, the presence of concurrent diseases, the level of invasion into other organs, and the probability that metastases already exist should factor into the decision. Poor surgical candidates generally include: dogs compromised from the effects of hypercortisolis; older animals; animals with concurrent disease; those for whom invasion has been aggressive and surgical or post-surgical complications are likely; animals with very large masses that have likely already metastasized; and those with documented potential metastatic disease. In addition, adrenalectomy may not be indicated when the mass is small (< 3 cm diameter) and nonfunctional, and the patient is healthy. Reports suggest that there is an approximate 45% success rate of surgical resection of adrenal masses, with a positive prognosis inversely proportionate to tumor size.

In cases of concurrent hepatic nodular changes, liver biopsy samples can be obtained at surgery in cases of suspicious lesions visualized by ultrasound. Hyperadrenocorticism often causes benign nodular hyperplasia of the liver and should not be automatically interpreted as a sign of hepatic metastasis during ultrasonographic examination. Rather, suspect lesions should be confirmed and biopsied either at surgery or via ultrasound-guided FNA or core biopsy. Post-operative complications include delayed wound healing due to excessive corticoid circulation and wasting, hemorrhage, sepsis, and thromboembolism.

When surgery is a risk and a functional adrenal tumor has been documented, medical therapy, as outlined above, should be considered. Medical therapy will not impede metastatic events. An alternative approach in these cases is to determine the rate of growth of the mass by repeating abdominal ultrasounds initially at 2, 4, and 6 months. If the adrenal mass does not change in size, the time between ultrasound evaluations can be increased to every 4-6 months; however, if the adrenal mass is increasing in size, adrenalectomy should be considered.

**Conclusion:** Any incidentally discovered adrenal tumor warrants investigation into functionality and metastasis. The course of treatment for each case depends largely on which hormones are secreted by



**PATIENT**

the adrenal tumor. Each case should be carefully evaluated on an individual basis before adrenalectomy is considered for aggressive tumors.

Max Lauri

**SPECIES**

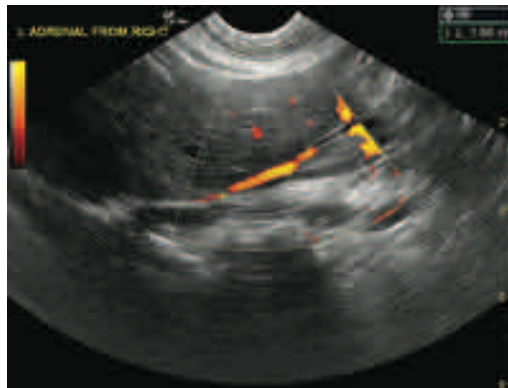
Canine

**BREED**

Shih Tzu

**SEX**

Neutered male



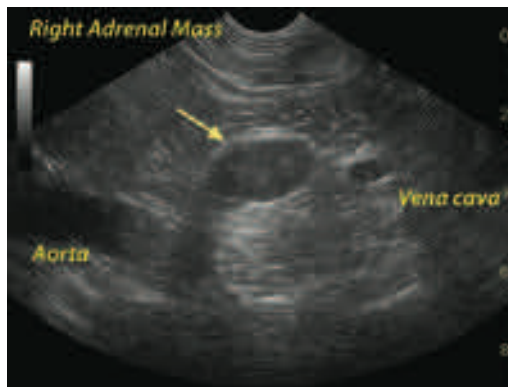Long axis of the caudal vena cava using a right lateral approach of the same dog as in the title image. Note the cranial extension of the hyperechoic thrombus material within the caudal vena cava. The liver is seen in the near field. The measurement line represents the distance from the tumor thrombus invasion to the diaphragmatic inlet

**AGE**

12 years

**WEIGHT**

21 lbs



Long axis of the right adrenal gland using a right lateral approach in a dog with a surgically resectable pheochromocytoma incidentally identified during a sonogram investigating proteinuria. The adrenal gland is enlarged, rounded and hypoechoic. Note the lack of parenchymal detail with no visible corticomedullary junction as well as the echogenic capsular expansion (arrow). The patient was found to have systemic hypertension after detecting the enlarged adrenal gland sonographically.

**INTERPRETED BY**

Eric Lindquist, DMV,  
DABVP, Cert. IVUSS,  
CEO of SonoPath.com

**IMAGING PERFORMED BY**

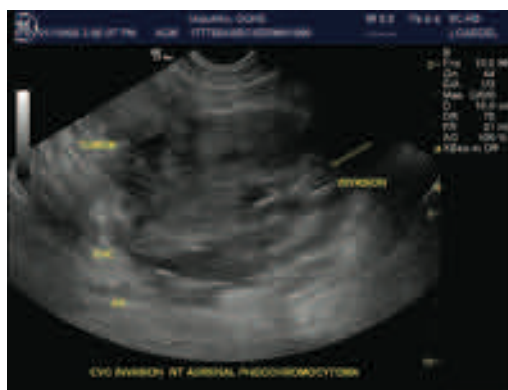Kelly Vazquez, CVT

**HOSPITAL NAME**

Marsh Hospital for  
Animals

**REFERRING VET**

Dr. Milwicki



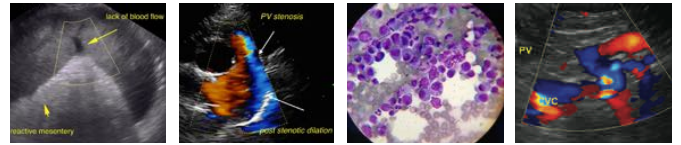
Long axis view of the caudal vena cava (CVC) in the prior invasive adrenal mass image. Landmarks are assessed cranial to the right adrenal gland (SDEP scanning position 13 & 14), such as the aorta, in order to identify the invasive adrenal mass occupying the CVC since a normal CVC cannot be found. Color Doppler assessment of the area shows the minor caval blood flow around the invading mass. Invasive adrenal tumors, by definition, are either pheochromocytoma or adenocarcinoma and can become very large and invasive over time, but can sometimes be medically managed to maintain quality of life. A lesion such as this had likely been growing for some time but clinical signs were relatively recent prior to the sonogram.

**INVOICE**

98117

**DATE**

4/7/22



**PATIENT**

Max Lauri

**SPECIES**

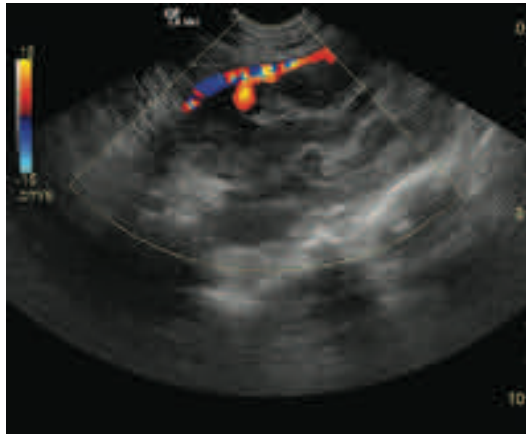
Canine

**BREED**

Shih Tzu

**SEX**

Neutered male



Geriatric Boxer dog presented with vague clinical signs and systemic hypertension. A large cranial abdominal mass is present when imaging the region of the vena cava and right adrenal area. A normal right adrenal could not be found. After scrupulous interrogation of the region and assessment of the regional structures, such as the aorta, the clinical sonographer can discover that the mass is likely of adrenal origin given the ominous vena caval invasion. US-guided 25 g FNA: Pheochromocytoma

**AGE**

12 years

**References:**

Behrend EN, Kooistra HS, Nelson R, et al. Diagnosis of Spontaneous Canine Hyperadrenocorticism: 2012 ACVIM Consensus Statement (Small Animal). *J Vet Intern Med* 2013;27:1292-1304.

**WEIGHT**

21 lbs

Heorauf A, Reusch C. Ultrasonographic characteristics of both adrenal glands in 15 dogs with functional adrenocortical tumors. *J Am Anim Hosp Assoc* 1999;35(3):193-99.

**INTERPRETED BY**

Eric Lindquist, DMV,  
DABVP, Cert. IVUSS,  
CEO of SonoPath.com

Herrara MA, Mehl ML, Kass PH, et al. Predictive factors and the effect of phenoxybenzamine on outcome in dogs undergoing adrenalectomy for pheochromocytoma. *J Vet Intern Med* 2008;22(6):1333-39.

Nelson, RW. Diagnostic approach to the incidental adrenal mass. World Small Animal Veterinary Association World Congress, Granada, Spain, 3-5 October, 2002.

**IMAGING PERFORMED BY**

Kelly Vazquez, CVT

Syme HM, Scott-Moncioeff JC, Treadwell NG, et al. Hyperadrenocorticism associated with excessive sex hormone production by an adrenocortical tumor in two dogs. *J Am Vet Med Assoc* 2001;219(12):1725-28.

**HOSPITAL NAME**

Marsh Hospital for  
Animals

Withrow, S. Management of endocrine neoplasia. World Small Animal Veterinary Association World Congress, Vancouver, BC, 8-11 August, 2001.

**REFERRING VET**

Dr. Milwicki

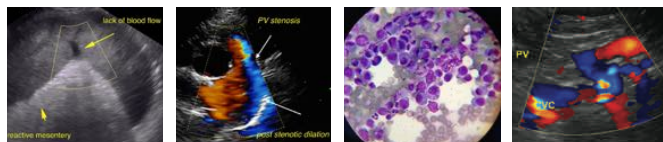
von Dehn BJ, Nelson RW, Feldman EC, Griffey SM. Pheochromocytoma and hyperadrenocorticism in dogs: six cases (1982-1992). *J Am Vet Med Assoc* 1995;207(3):322-24.

**INVOICE**

98117

**DATE**

4/7/22



**PATIENT**

Max Lauri

**SPECIES**

Canine

**BREED**

Shih Tzu

**SEX**

Neutered male

**AGE**

12 years

**WEIGHT**

21 lbs

**INTERPRETED BY**

Eric Lindquist, DMV,  
DABVP, Cert. IVUSS,  
CEO of SonoPath.com

**IMAGING  
PERFORMED BY**

Kelly Vazquez, CVT

**HOSPITAL NAME**

Marsh Hospital for  
Animals

**REFERRING VET**

Dr. Milwicki

**INVOICE**

98117

**DATE**

4/7/22