



PATIENT

Mutton Whitney

SPECIES

Canine

BREED

Bichon Frise

SEX

Spayed female

AGE

11 ½ years

WEIGHT

12.6 lbs

INTERPRETED BY

Eric Lindquist, DMV
DABVP, Cert. IVUSS

IMAGING PERFORMED BY

Kevin Moon, DVM

HOSPITAL NAME

Shiloh VH

REFERRING VET

Dr. Herr

INVOICE

74231

DATE

4/6/26

PRESENTING CLINICAL SIGNS

- Chronic diarrhea with elevated BUN

Abnormal PE/Chem/CBC/UA Results: BUN 60 Creat 1.1 SDMA 8.7

Total # of Files Uploaded: 42

User Name: ShilohVHSonoreport

ULTRASONOGRAPHIC EXAMINATION OF THE ABDOMEN

Images from 3/24/26

Urinary System

The **urinary bladder**, trigone, and pelvic urethra presented normal thicknesses and normal tone. The pelvic urethra was imaged 2.0 cm beyond the cystourethral junction and appeared normal. The ureters were not visible which is normal. No uroliths or sediment were visualized and anechoic urine was present. No evidence of inflammatory or neoplastic changes was noted. Ureteral papillae were normal.

The **kidneys** revealed normal size and structure, corticomedullary definition and ratio for this age. The cortices presented largely uniform texture with normal echogenic relationship to liver and spleen. Medullary structure differed distinctly from the cortex and no evidence of pelvic dilation was present. The capsules were acceptably uniform without significant irregularities. The right kidney measured 4.4 cm.

Adrenal Glands

Both **adrenal glands** were visualized and recognized as having normal shape, size, position and echogenicity for this breed. The phrenic vasculature, glandular echogenicity and detail were unremarkable. Capsule, cortex, and medullary definition were normal for this age patient. The left adrenal gland measured 0.45 cm. The right adrenal gland measured 0.6 cm.

Spleen

The **spleen** presented a smooth homogeneous parenchyma hyperechoic to liver and renal cortical parenchyma. The capsule was smooth without noticeable expansion or deviation from within the spleen or adjacent pathology. The splenic vasculature demonstrated normal volume without signs of congestion or thrombosis. No sonographic evidence of acute or chronic inflammatory, neoplastic, or infarctual changes was noted.



PATIENT

Mutton Whitney

SPECIES

Canine

BREED

Bichon Frise

SEX

Spayed female

AGE

11 ½ years

WEIGHT

12.6 lbs

INTERPRETED BY

Eric Lindquist, DMV
DABVP, Cert. IVUSS

IMAGING PERFORMED BY

Kevin Moon, DVM

HOSPITAL NAME

Shiloh VH

REFERRING VET

Dr. Herr

INVOICE

74231

DATE

4/6/26

Liver

The **liver** images submitted revealed subjectively normal liver size, contour, and structure. Parenchymal echogenicity was naturally coarse and hypoechoic to the spleen. Vascular and biliary tracts were of normal volume with no evidence of congestion. The gallbladder presented acceptably thin walls with primarily anechoic content. The cystic and common bile ducts were normal. No pathological hepatic lymphadenopathy was evident. No overt structural evidence of inflammatory, infiltrative or regenerative pathology was evident.

Gastrointestinal

The **gastric** wall was hypertrophied without loss of mural detail. Wall thickness measured up to 1.2 cm. The lumen was empty. Mucosal speckling was noted in portion of the small intestine. There was no loss of mural detail.

Pancreas

The base and limbs of the **pancreas** were observed to be largely isoechoic to surrounding omental fat. Pancreatic duct and capsular contour were acceptably normal and parenchyma respected normal curvilinear patterns. No overt evidence of active inflammatory or neoplastic disease was noted.

ULTRASONOGRAPHIC FINDINGS

Mild gastric hypertrophy and subtle mucosal speckling.

Age related abdominal changes otherwise.

INTERPRETATION OF THE FINDINGS & FURTHER RECOMMENDATIONS

Occult Addison's should be ruled out even though structurally the adrenal glands measure and appear normal.

Differentials for diarrhea include occult parasitism. Dietary indiscretion, dietary intolerance, antibiotic responsive colitis, intestinal dysbiosis and occult Addison's should all be considered as causes of diarrhea in this patient. A hydrolyzed diet trial may be in this patient's best interest +/- probiotics. 24-hour NPO and reintroduction of bland diet indicated. I recommend a baseline cortisol or ACTH stimulation test, a fresh fecal smear and fecal floatation analysis if not already performed



PATIENT

Mutton Whitney

SPECIES

Canine

BREED

Bichon Frise

SEX

Spayed female

AGE

11 ½ years

WEIGHT

12.6 lbs

INTERPRETED BY

Eric Lindquist, DMV
DABVP, Cert. IVUSS

IMAGING PERFORMED BY

Kevin Moon, DVM

HOSPITAL NAME

Shiloh VH

REFERRING VET

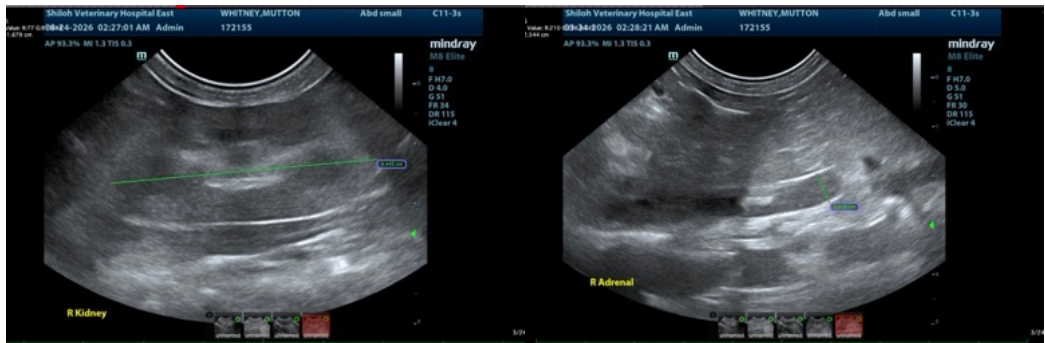
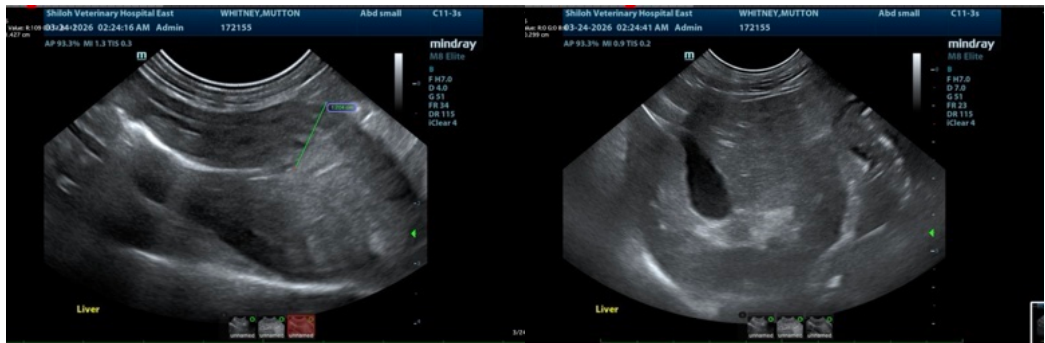
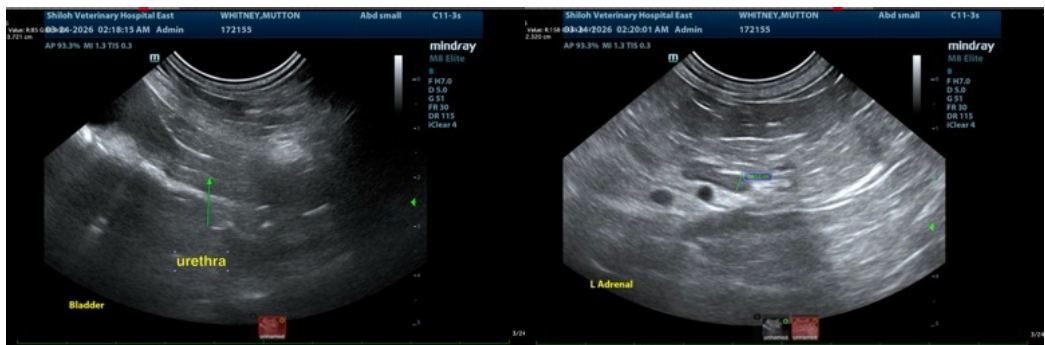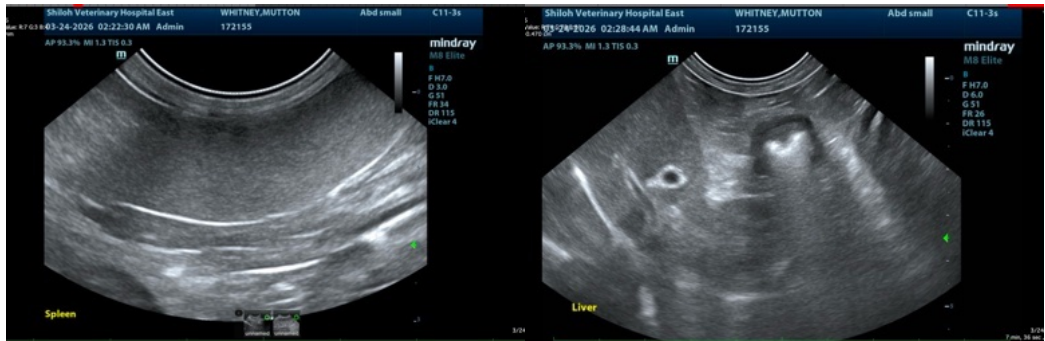
Dr. Herr

INVOICE

74231

DATE

4/6/26





PATIENT

Mutton Whitney

SPECIES

Canine

BREED

Bichon Frise

SEX

Spayed female

AGE

11 ½ years

WEIGHT

12.6 lbs

INTERPRETED BY

Eric Lindquist, DMV
DABVP, Cert. IVUSS

IMAGING PERFORMED BY

Kevin Moon, DVM

HOSPITAL NAME

Shiloh VH

REFERRING VET

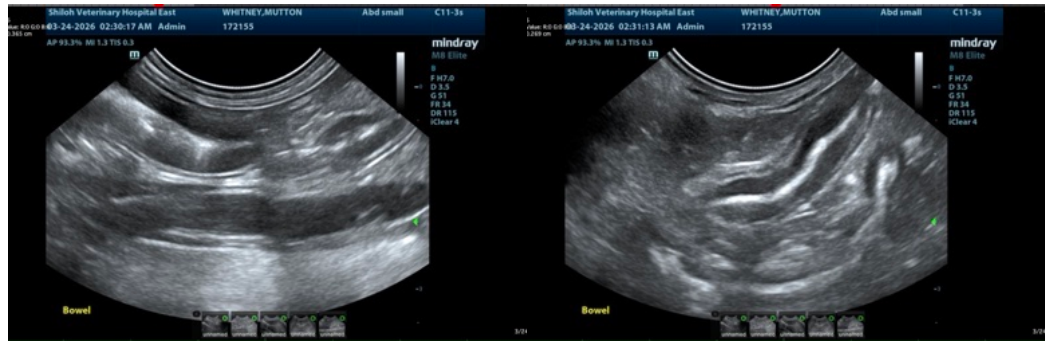
Dr. Herr

INVOICE

74231

DATE

4/6/26



The information and recommendations provided are based on the images presented by the referring veterinarian/sonographer. No evaluation can be communicated regarding pathology that was not visible in the image/video clips provided.

Thank you for this referral. If the clinical or image interpretation does not parallel your findings or if I can be of any further assistance please contact me.

Eric Lindquist, DMV, DABVP (CFM), Cert. IVUSS, CEO of SonoPath.com

info@SonoPath.com