



PATIENT

Bella Murphy

SPECIES

Canine

BREED

Mixed

SEX

Spayed Female

AGE

5 Months

WEIGHT

24 pounds

INTERPRETED BY

Eric Lindquist, DMV,
DABVP(CFM), Cert.
IVUSS

IMAGING PERFORMED BY

Meghan Morse LVT
CVT

HOSPITAL NAME

Hamptonburgh Animal
Hospital

REFERRING VET

Dr. Madaan

INVOICE

14897

DATE

04/06/26

PRESENTING CLINICAL SIGNS

Ataxia, collapsing after eating, lethargic, whining at end of eating. No current meds

Abnormal PE/Chem/CBC/UA Results: Labs WNL

ULTRASONOGRAPHIC EXAMINATION OF THE HEART & ABDOMEN

CANINE CARDIAC PARAMETERS	MR VMAX (m/s)	TR VMAX (m/s)	LA/AO (M-Mode)	LA/AO (Heart Base; Swe)	FS (%)	EF (%)	EPSS (cm)
NORMAL PARAMETER	4.5-5.5	<2.7	1.3	Up to 1.6	28-40	40-100	<0.6
PATIENT	--	--	1.0	1.3	33	62	0.2
CANINE CARDIAC PARAMETERS	HR (BPM)	AV VMAX (m/s)	PV MAX (m/s)	BODY WEIGHT (lbs)	LAD LA MAX 4 Chamber	LVIDd Avg; 2D and m-mode short axis (cm)	LVIDs Avg; 2D and m-mode short axis (cm)
NORMAL PARAMETER	50-100	0.7-1.7	0.7-1.6				
PATIENT	NM	1.6	0.87	24.0	2.7	3.4	--

Cardiac Presentation

The echocardiogram in this patient demonstrated normal **left atrial** size based on 3 separate methods of LA evaluation. The cranial and caudal **mitral** valve leaflets presented normal linear structure, extension in systole, and union in diastole with normal kinesis. The **left ventricle** presented normal thicknesses with linear contour and was not dilated nor restricted. The **myocardium** presented normal echogenicity without subjective evidence of significant fibrotic or ischemic disease. **Contractility** of the ventricular walls was adequate and in normal range for this patient evidenced by the fractional shortening measurement and subjective evaluation of the different regions of the myocardium. The **left ventricular outflow** tract demonstrated normal laminar flow and subjective structural integrity. The **right atrium** and auricle revealed normal size, structure and content. No evidence of masses was noted. **Tricuspid** valvular assessment demonstrated adequate linear morphology and kinesis. The **right ventricle** was of normal size (1/3 diameter of LV), chordae structure, myocardial echogenicity and thickness. **Pulmonary outflow** tract assessment revealed normal valve structure, laminar flow, and diameter (approx.1:1 pa/ao ratio). No visible **pericardial** or free pleura fluid was noted. The cranial **mediastinum and pericardial and extra-cardiac regions** were free of masses in the visible window. Periodic arrhythmia was noted in this patient.

Urinary System

The **urinary bladder**, trigone, and pelvic urethra presented normal thicknesses and normal tone. The ureters were not visible which is normal. No uroliths or sediment were visualized, and anechoic urine



PATIENT

Bella Murphy

SPECIES

Canine

BREED

Mixed

SEX

Spayed Female

AGE

5 Months

WEIGHT

24 pounds

INTERPRETED BY

Eric Lindquist, DMV,
DABVP(CFM), Cert.
IVUSS

IMAGING PERFORMED BY

Meghan Morse LVT
CVT

HOSPITAL NAME

Hamptonburgh Animal
Hospital

REFERRING VET

Dr. Madaan

INVOICE

14897

DATE

04/06/26

was present. No evidence of inflammatory or neoplastic changes were noted. Ureteral papillae were normal.

The **kidneys** revealed normal size and structure, corticomedullary definition and ratio for this age. The cortices presented largely uniform texture with normal echogenic relationship to liver and spleen. Medullary structure differed distinctly from the cortex and no evidence of pelvic dilation was present. The capsules were acceptably uniform without significant irregularities. The left kidney measured 5.27 cm in length. The right kidney measured 4.93 cm in length.

Adrenal Glands

Both **adrenal glands** were visualized and recognized as having normal shape, size, position and echogenicity for this breed. The phrenic vasculature, glandular echogenicity and detail were unremarkable. Capsule, cortex, and medullary definition were normal for this age patient. The left adrenal gland measured 2.06 cm x 0.39 cm width at the caudal pole and 0.45 cm width at the cranial pole. The right adrenal gland measured 1.52 cm x 0.76 cm width at the cranial pole and 0.41 cm width at the caudal pole.

Spleen

The **spleen** presented a smooth homogeneous parenchyma hyperechoic to liver and renal cortical parenchyma. The capsule was smooth without noticeable expansion or deviation from within the spleen or adjacent pathology. The splenic vasculature demonstrated normal volume without signs of congestion or thrombosis. No sonographic evidence of acute or chronic inflammatory, neoplastic, or infarctual changes were noted.

Liver

The **liver** images submitted revealed subjectively normal liver size, contour, and structure. Parenchymal echogenicity was naturally coarse and hypoechoic to the spleen. Vascular and biliary tracts were of normal volume with no evidence of congestion. The gallbladder presented acceptably thin walls with primarily anechoic content. The cystic and common bile ducts were normal. No pathological hepatic lymphadenopathy was evident. No overt structural evidence of inflammatory, infiltrative or regenerative pathology was evident. No evidence of portosystemic shunting. The portal vein/vena cava ratio was 1:1. The portal vein measured 0.62 cm. The vena cava measured 0.60 cm.

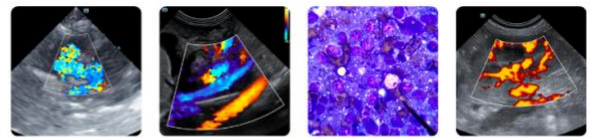
Gastrointestinal

Examination of the **gastrointestinal tract** revealed a stomach and intestine free of stasis, of normal wall thickness, acceptable curvilinear mural detail, and peristaltic activity. Small and large intestine demonstrated normal luminal chyme and stool consistency respectively. No obstructive or overt infiltrative disease was noted. No associated abnormal lymphatic activity was noted.

Pancreas

The base and limbs of the **pancreas** were observed to be largely isoechoic to surrounding omental fat. Pancreatic duct and capsular contour were acceptably normal and parenchyma respected normal curvilinear patterns. No overt evidence of active inflammatory or neoplastic disease was noted.

Free Abdomen



PATIENT

Bella Murphy

SPECIES

Canine

BREED

Mixed

SEX

Spayed Female

AGE

5 Months

WEIGHT

24 pounds

INTERPRETED BY

Eric Lindquist, DMV,
 DABVP(CFM), Cert.
 IVUSS

IMAGING PERFORMED BY

Meghan Morse LVT
 CVT

HOSPITAL NAME

Hamptonburgh Animal
 Hospital

REFERRING VET

Dr. Madaan

INVOICE

14897

DATE

04/06/26

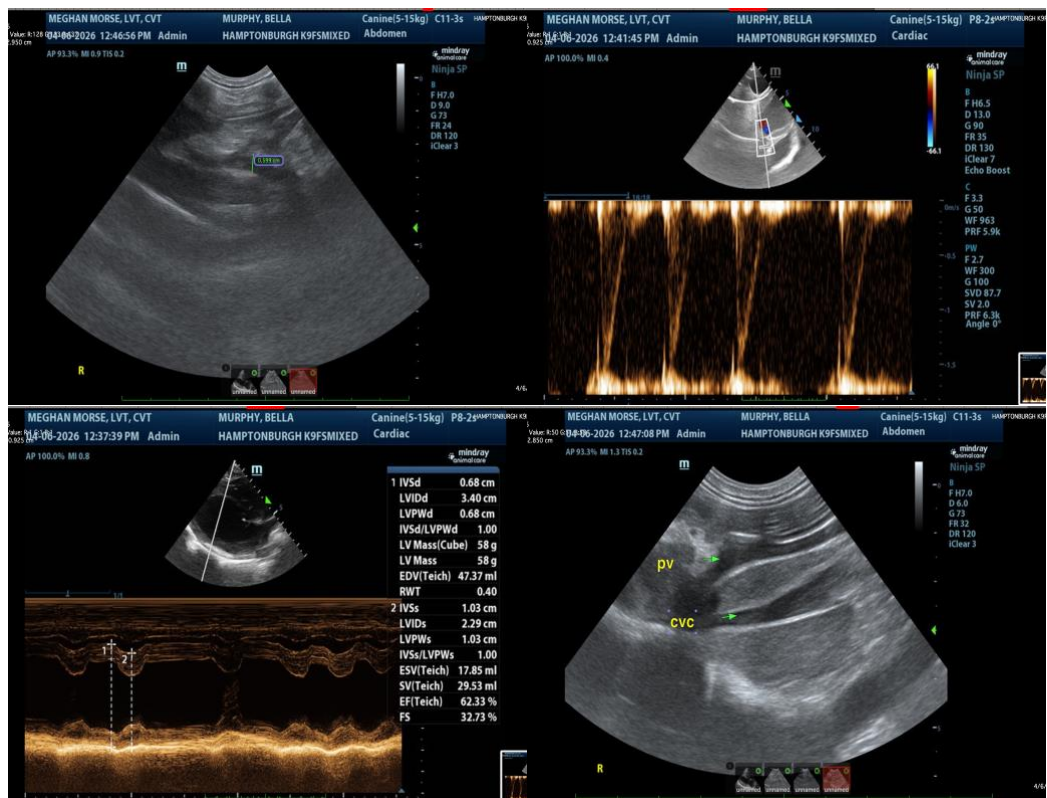
The mesenteric **lymph nodes** presented normal length to width ratio with slight, swollen contour. There was no loss of parenchymal detail. This is most consistent with reactive lymphadenitis or lymphatic hyperplasia. The largest lymph node measured 2.8 cm x 0.77 cm.

ULTRASONOGRAPHIC FINDINGS

- Normal echocardiogram with periodic arrhythmia.
- Structurally unremarkable abdomen.
- Slight mesenteric lymph nodes.

INTERPRETATION OF THE FINDINGS & FURTHER RECOMMENDATIONS

Paroxysmal arrhythmia may be the cause of the clinical signs in this patient. Underlying infectious agents or history of parvovirus should be considered as a potential in this patient, yet structurally and functionally at the time of the echocardiogram, there was no deficit, however irritability of the myocardium for various causes may be playing a role. A Holter monitor would be ideal which may be obtained from our office with cardiologist review.





PATIENT

Bella Murphy

SPECIES

Canine

BREED

Mixed

SEX

Spayed Female

AGE

5 Months

WEIGHT

24 pounds

INTERPRETED BY

Eric Lindquist, DMV,
 DABVP(CFM), Cert.
 IVUSS

IMAGING PERFORMED BY

Meghan Morse LVT
 CVT

HOSPITAL NAME

Hamptonburgh Animal
 Hospital

REFERRING VET

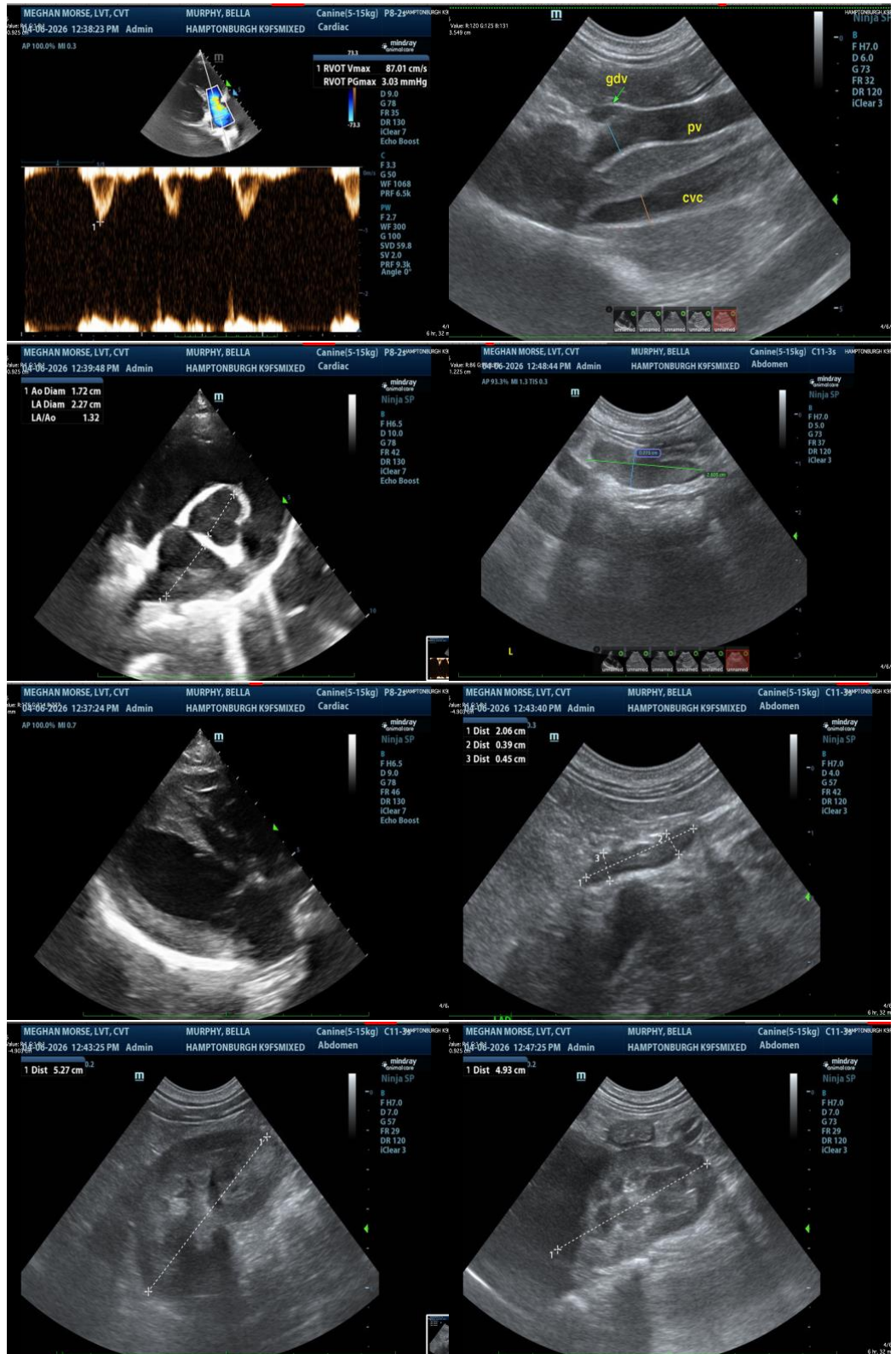
Dr. Madaan

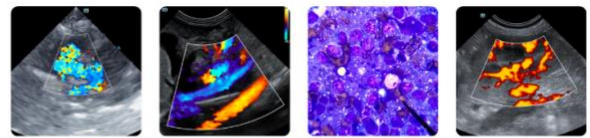
INVOICE

14897

DATE

04/06/26





PATIENT

Bella Murphy

SPECIES

Canine

BREED

Mixed

SEX

Spayed Female

AGE

5 Months

WEIGHT

24 pounds

INTERPRETED BY

Eric Lindquist, DMV,
 DABVP(CFM), Cert.
 IVUSS

IMAGING PERFORMED BY

Meghan Morse LVT
 CVT

HOSPITAL NAME

Hamptonburgh Animal
 Hospital

REFERRING VET

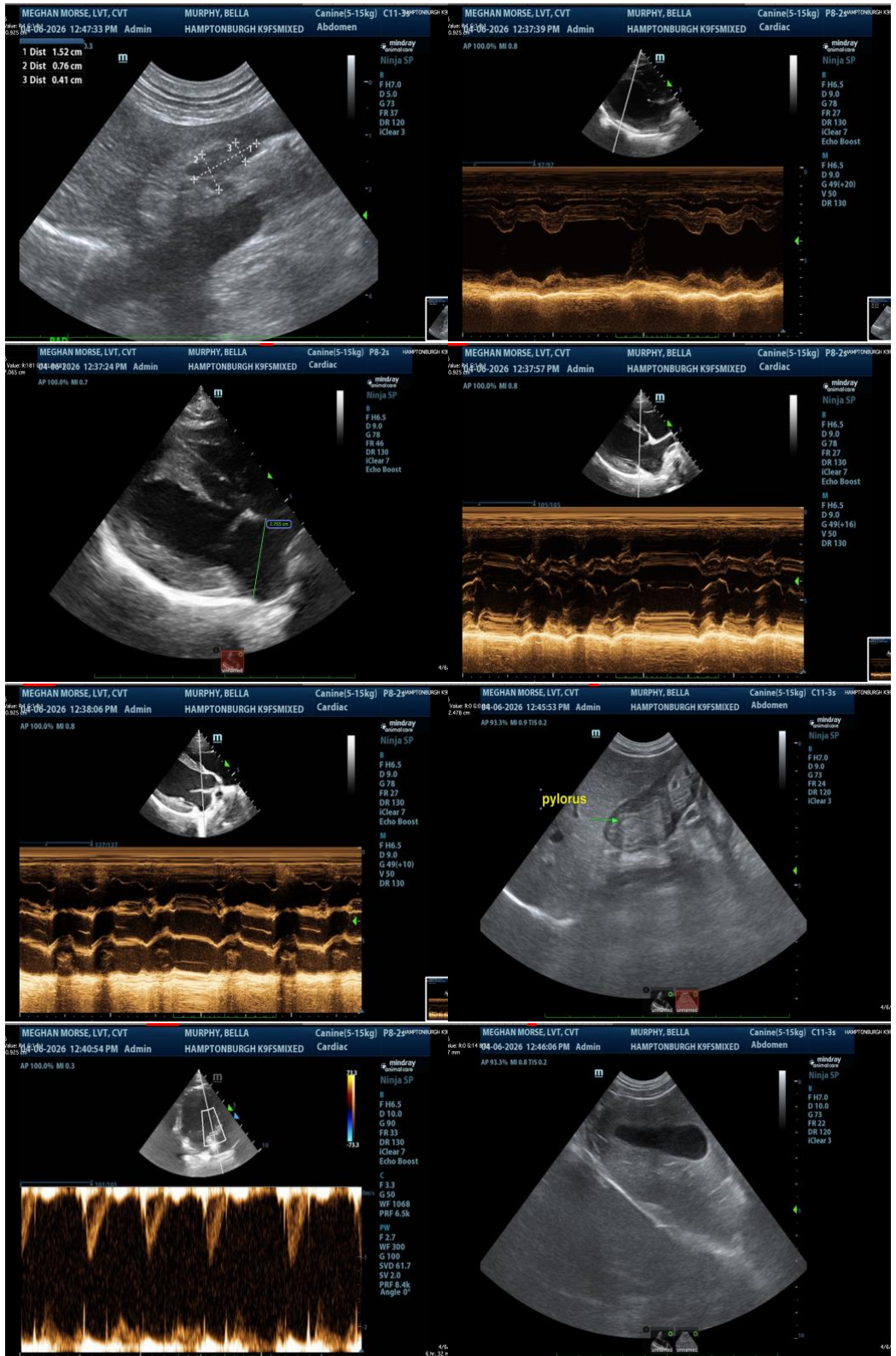
Dr. Madaan

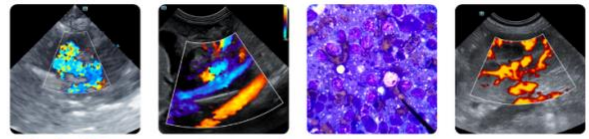
INVOICE

14897

DATE

04/06/26





PATIENT

Bella Murphy

The information and recommendations provided are based on the images presented by the referring veterinarian/sonographer. No evaluation can be communicated regarding pathology that was not visible in the image/video clips provided.

SPECIES

Canine

Thank you for this referral. If the clinical or image interpretation does not parallel your findings or if I can be of any further assistance, please contact me.

BREED

Mixed

Eric Lindquist, DMV, DABVP(CFM), Cert. IVUSS,

CEO, Owner, Founder -- SonoPath.com

info@SonoPath.com

SEX

Spayed Female

AGE

5 Months

WEIGHT

24 pounds

INTERPRETED BY

Eric Lindquist, DMV,
DABVP(CFM), Cert.
IVUSS

**IMAGING
PERFORMED BY**

Meghan Morse LVT
CVT

HOSPITAL NAME

Hamptonburgh Animal
Hospital

REFERRING VET

Dr. Madaan

INVOICE

14897

DATE

04/06/26