

DATE

4/6/23

PATIENT

Zoe Pereira

SPECIES

Canine

BREED

Shih Tzu

SEX

Spayed female

AGE

10/26/18

WEIGHT

18.4 lbs

INTERPRETED BY

Eric Lindquist, DMV
DABVP, Cert. IVUSS

HOSPITAL NAME

Banfield Towson

REFERRING VET

Dr. Mike

INVOICE

43740

PRESENTING CLINICAL SIGNS

Elevated AP and ALT since 2021. Per O not symptomatic for Cushings disease.
Current Medications: Denamarin long term.
Lab Results: 3/21/23 AP 321 (23-212), ALT 166 (10-123). Elevated bile acids pre 55.5, post 34.4.
Date of Previous IntraPet Ultrasound: No previous.
Sedation: Not required to complete full diagnostic ultrasound.
Stat Report: Not requested.
Imaging Performed By: Rachel Brillhart, RDMS.

ULTRASONOGRAPHIC EXAMINATION OF THE ABDOMEN

Urinary System

The **urinary bladder**, trigone, and pelvic urethra presented normal thicknesses and normal tone. The ureters were not visible which is normal. No uroliths or sediment were visualized and anechoic urine was present. No evidence of inflammatory or neoplastic changes was noted. Ureteral papillae were normal.

The **kidneys** revealed normal size and structure, corticomedullary definition and ratio for this age. The cortices presented largely uniform texture with normal echogenic relationship to liver and spleen. Medullary structure differed distinctly from the cortex and no evidence of pelvic dilation was present. The capsules were acceptably uniform without significant irregularities. The right kidney measured 4.47 cm. The left kidney measured 4.15 cm.

Adrenal Glands

Both **adrenal glands** were visualized and recognized as having normal shape, size, position and echogenicity for this breed. The phrenic vasculature, glandular echogenicity and detail were unremarkable. Capsule, cortex, and medullary definition were normal for this age patient. The right adrenal gland measured 1.8 x 0.53 cm at the caudal pole and 0.67 cm at the cranial pole. The left adrenal gland measured 1.73 x 0.453 cm at the caudal pole and 0.46 cm at the cranial pole.

Spleen

The **spleen** was uniform and folded upon itself caudally. There was no evidence of pathology.

Liver

The **liver** revealed slight coarse architecture and minor swelling. The portal vein to vena cava ratio was 1:1 with no evidence of intrahepatic and extrahepatic shunting. The gallbladder and common bile duct were unremarkable.

Gastrointestinal

Examination of the **gastrointestinal tract** revealed a stomach and intestine free of stasis, of normal wall thickness, acceptable curvilinear mural detail, and peristaltic activity. Small and large intestine demonstrated normal luminal chyme and stool consistency respectively. No obstructive or overt infiltrative disease was noted. No associated abnormal lymphatic activity was noted.

Pancreas

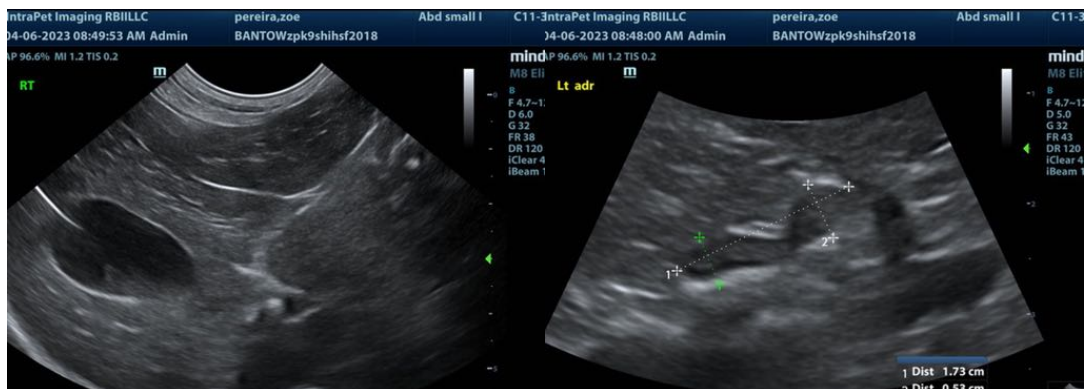
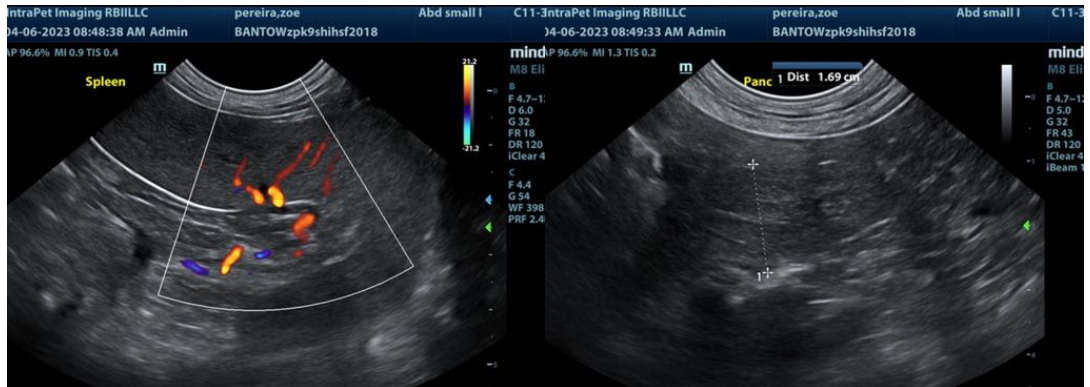
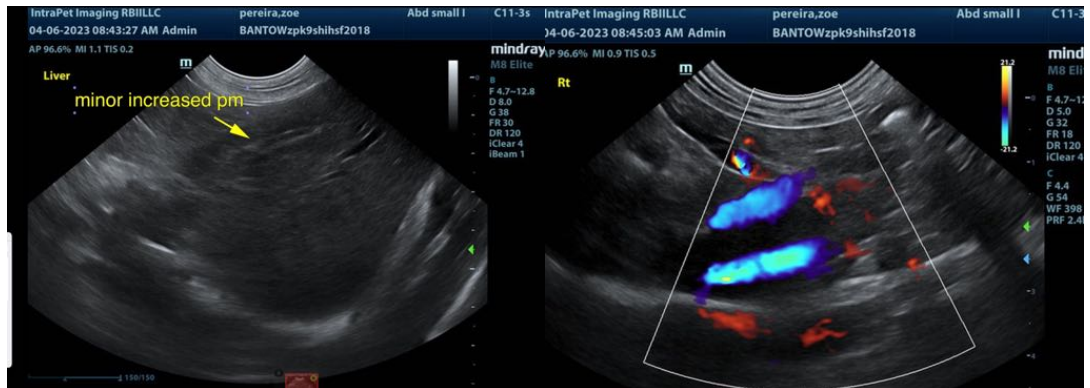
The **pancreas** was prominent and slightly hypoechoic to the surrounding fat. There was no evidence of active inflammation.

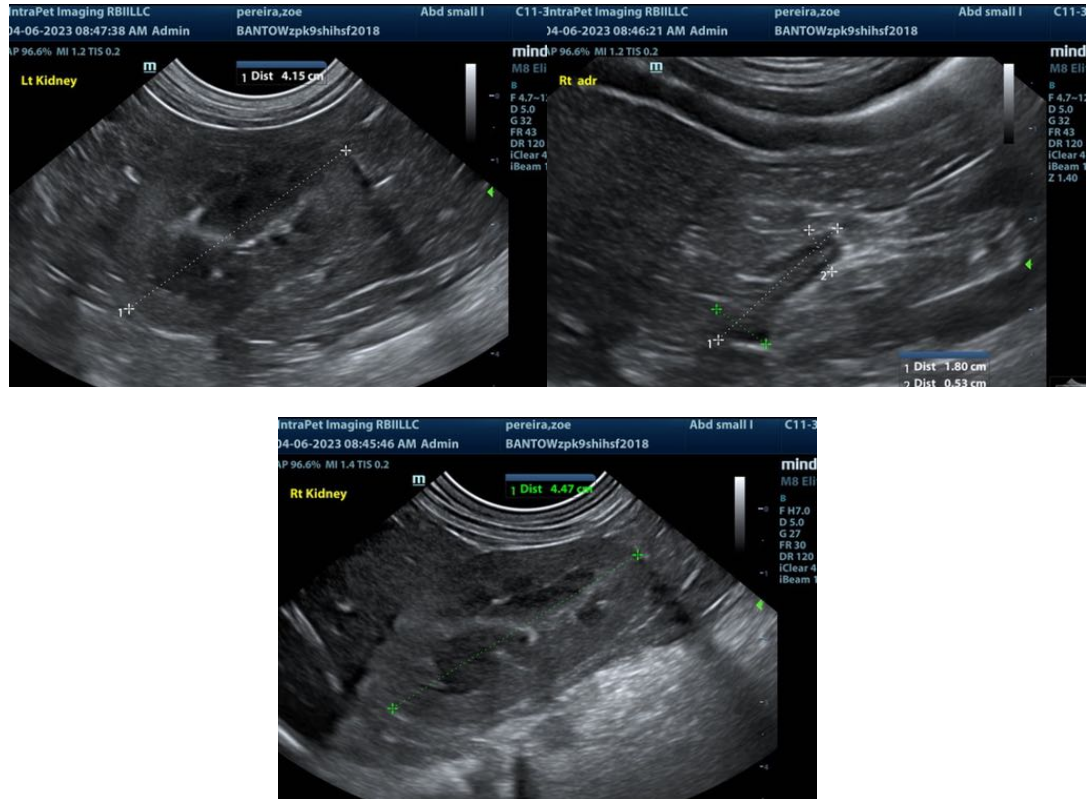
ULTRASONOGRAPHIC FINDINGS

Reactive hepatopathy or minor low-grade inflammatory hepatopathy.

INTERPRETATION OF THE FINDINGS & FURTHER RECOMMENDATIONS

There was no evidence of portosystemic shunting. FNA can be considered for further definition or core biopsy; however, structurally the liver appears benign. FNA would allow to assess inflammatory cell type. Core biopsy is necessary to assess for portal hypoplasia. Microvascular dysplasia. However, spurious elevation of bile acids may be the underlying tissue.





The information and recommendations provided are based on the images presented by the referring veterinarian. No evaluation can be communicated regarding pathology that was not visible in the image/video clips provided.

Thank you for this referral. If the clinical or image interpretation does not parallel your findings or if I can be of any further assistance please contact me.

Eric Lindquist, DMV, DABVP, Cert. IVUSS, CEO of SonoPath.com
Eric.Lindquist@SonoPath.com