



PATIENT PRESENTING CLINICAL SIGNS

Marshall Jagid

History: 15 yr old shih tzu- progressive lymphocytosis- pending immuno phenotyping and path review of blood smear. has a severe malessezia pyoderma and just rx fluconazole and medicated baths. hx of thymoma sx treated 1 yr ago. 6 months ago diagnosed with stage 2 crd and on abd u/s we saw degenerative renal changes and an incidental 2cm splenic mass. ultrasound repeated today to follow the mass/kidneys. chest rads 3 views wnl.

SPECIES

Canine

BREED

Shih Tzu

SEX

Neutered male

AGE

15 years

WEIGHT

14.1 lbs

ULTRASONOGRAPHIC EXAMINATION OF THE ABDOMEN

Urinary System

The **urinary bladder**, trigone, and pelvic urethra presented normal thicknesses and normal tone. The ureters were not visible which is normal. No uroliths or sediment were visualized and anechoic urine was present. No evidence of inflammatory or neoplastic changes was noted. Ureteral papillae were normal.

The **kidneys** revealed largely normal size and structure, corticomedullary definition and ratio (cortex 1/3 of medulla) were essentially maintained with some age-related loss of curvilinear patterns regarding the capsule and C/M junction. The cortices presented largely uniform texture with some increased echogenicity expected for his age patient. Medullary structure differed distinctly from that of the cortex. Slight pyelectasia was noted in both kidneys. Corticomedullary mineralization was noted in both kidneys. The left kidney measured 4.53 cm.

INTERPRETED BY

Eric Lindquist, DMV
DABVP, Cert. IVUSS

Adrenal Glands

The right **adrenal gland** revealed a hyperechoic, expansive nodule that measured 0.77 cm and 0.58 cm at the caudal pole. The nodule is consistent with an adenoma. Microcystic cortical changes were noted. The largest cyst measured 0.4 cm. The left adrenal gland measured 0.68 cm at the caudal pole and 0.7 cm at the cranial pole.

IMAGING PERFORMED BY

Dr. Salas

Spleen

HOSPITAL NAME

Tenafly VC

The **spleen** revealed multi-focal, hyperechoic nodular changes. This is consistent with lipogranulomas. The spleen revealed a hyperechoic, expansive 2.6 cm mass. This is consistent with granuloma or possible lipogranuloma or fibrosarcoma.

REFERRING VET

Dr. Salas

Liver

The **liver** images from right and left intercostal as well as subcostal views revealed subjectively normal liver size, contour, and structure. Some age-related parenchymal remodeling was noted but likely not clinically significant at this time. Vascular and biliary tracts were of normal volume and no evidence of congestion was noted. The gallbladder was mildly over distended with suspended and dependent debris, yet not to the level of emerging mucocele, yet sludge appears to be mildly excessive. No adjunctive inflammation was noted.

INVOICE

43731

DATE

4/6/23



PATIENT

Gastrointestinal

Marshall Jagid

Examination of the **gastrointestinal tract** revealed a stomach and intestine free of stasis, of normal wall thickness, acceptable curvilinear mural detail, and peristaltic activity. Small and large intestine demonstrated normal luminal chyme and stool consistency respectively. No obstructive or overt infiltrative disease was noted. No associated abnormal lymphatic activity was noted.

SPECIES

Canine

Pancreas

BREED

Shih Tzu

The base and limbs of the **pancreas** were observed to be largely isoechoic to surrounding omental fat. Pancreatic duct and capsular contour were acceptably normal and parenchyma respected normal curvilinear patterns. No overt evidence of active inflammatory or neoplastic disease was noted.

SEX

Neutered male

ULTRASONOGRAPHIC FINDINGS

AGE

15 years

Splenic mass.

Moderate degenerative renal changes with cortical cysts.

Right adrenal nodule, likely adenoma.

WEIGHT

14.1 lbs

INTERPRETATION OF THE FINDINGS & FURTHER RECOMMENDATIONS

FNA of the splenic mass is indicated. Splenectomy would be ideal; however, this is likely benign. Ultrasound-guided FNA is indicated for further definition. There was no overt evidence of pathology related to the lymphocytosis.

INTERPRETED BY

Eric Lindquist, DMV
DABVP, Cert. IVUSS

IMAGING PERFORMED BY

Dr. Salas

HOSPITAL NAME

Tenafly VC

REFERRING VET

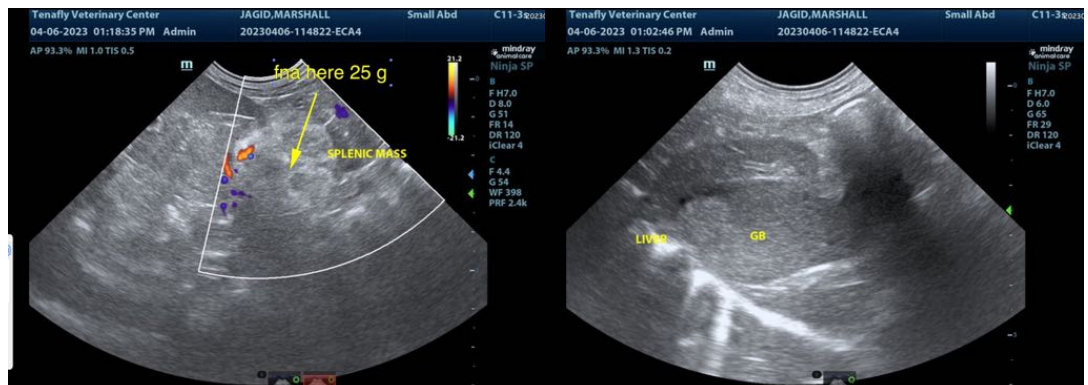
Dr. Salas

INVOICE

43731

DATE

4/6/23





PATIENT

Marshall Jagid

SPECIES

Canine

BREED

Shih Tzu

SEX

Neutered male

AGE

15 years

WEIGHT

14.1 lbs

INTERPRETED BY

Eric Lindquist, DMV
DABVP, Cert. IVUS

IMAGING PERFORMED BY

Dr. Salas

HOSPITAL NAME

Tenafly VC

REFERRING VET

Dr. Salas

INVOICE

43731

DATE

4/6/23

