

**DATE PRESENTING CLINICAL SIGNS**

4/6/23

Chronic elevated ALT.
Current Medications: Denamarin.
Lab Results: ALT 155.

PATIENT

Cooper Gilland

Date of Previous IntraPet Ultrasound: No previous.
Sedation: Not required to complete full diagnostic ultrasound.
Stat Report: Not requested.
Imaging Performed By: Rachel Brillhart, RDMS.

SPECIES

Canine

ULTRASONOGRAPHIC EXAMINATION OF THE ABDOMEN**BREED**

Yorkie

Urinary System

The **urinary bladder**, trigone, and pelvic urethra presented normal thicknesses and normal tone. The ureters were not visible which is normal. No uroliths or sediment were visualized and anechoic urine was present. No evidence of inflammatory or neoplastic changes was noted. Ureteral papillae were normal.

SEX

Neutered male

The **kidneys** revealed normal size and structure, corticomedullary definition and ratio for this age. The cortices presented largely uniform texture with normal echogenic relationship to liver and spleen. Medullary structure differed distinctly from the cortex and no evidence of pelvic dilation was present. The capsules were acceptably uniform without significant irregularities. The right kidney measured 3.3 cm. The left kidney measured 3.23 cm.

AGE

4/11/17

Adrenal Glands**WEIGHT**

2.93 lbs

Both **adrenal glands** were visualized and recognized as having normal shape, size, position and echogenicity for this breed. The phrenic vasculature, glandular echogenicity and detail were unremarkable. Capsule, cortex, and medullary definition were normal for this age patient. The right adrenal gland measured 1.5 x 0.5 cm at the caudal pole and 0.53 cm at the cranial pole. The left adrenal gland measured 1.61 x 0.47 cm at the caudal pole and 0.52 cm at the cranial pole.

INTERPRETED BYEric Lindquist, DMV
DABVP, Cert. IVUSS**Spleen**

The **spleen** presented a smooth homogeneous parenchyma hyperechoic to liver and renal cortical parenchyma. The capsule was smooth without noticeable expansion or deviation from within the spleen or adjacent pathology. The splenic vasculature demonstrated normal volume without signs of congestion or thrombosis. No sonographic evidence of acute or chronic inflammatory, neoplastic, or infarctual changes was noted.

HOSPITAL NAME

Banfield Towson

REFERRING VET

Dr. Chadha

Liver

The **liver** was coarse in architecture with increased portal markings. There was no evidence of portosystemic shunting. Slight, coarse, hepatic architecture was noted. The gallbladder revealed a minor amount of debris.

INVOICE

43742

Gastrointestinal

Examination of the **gastrointestinal tract** revealed a stomach with mild excessive gas and fluid/chyme accumulation. A 0.75 cm x 0.78 cm hypoechoic luminal structure was noted in the pylorus. This may be mucosal polyp or medication. Delayed outflow or underlying gastritis may be an issue. The intestines were free of stasis, of normal wall thickness, acceptable curvilinear mural detail, and peristaltic activity. Small and large intestine demonstrated normal luminal chyme and stool consistency respectively. No obstructive or overt infiltrative disease was noted. No associated abnormal lymphatic activity was noted.

Pancreas

The base and limbs of the **pancreas** were observed to be largely isoechoic to surrounding omental fat. Pancreatic duct and capsular contour were acceptably normal and parenchyma respected normal curvilinear patterns. No overt evidence of active inflammatory or neoplastic disease was noted.

ULTRASONOGRAPHIC FINDINGS

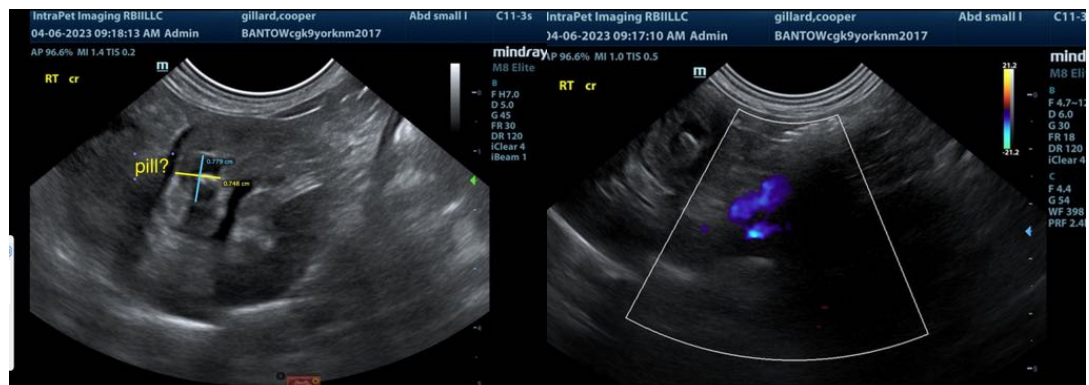
Minor hepatic remodeling. Non-specific. Inflammatory hepatopathy/reactive hepatopathy.
Minor, excessive gallbladder debris.

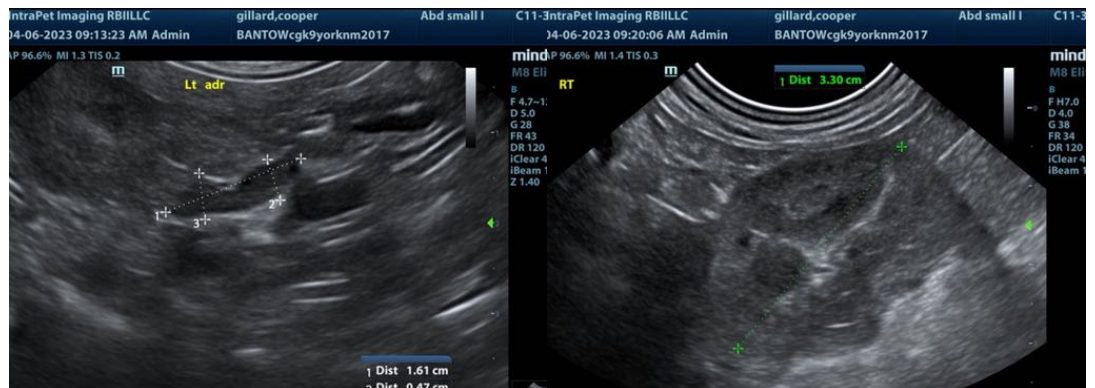
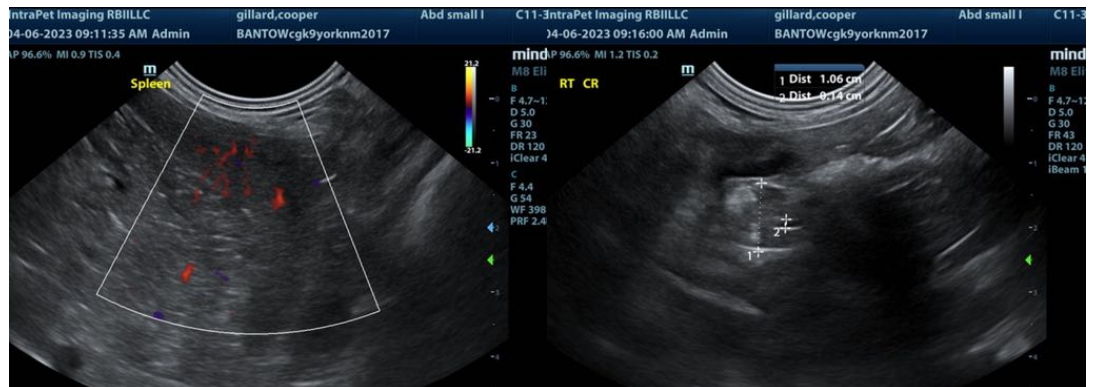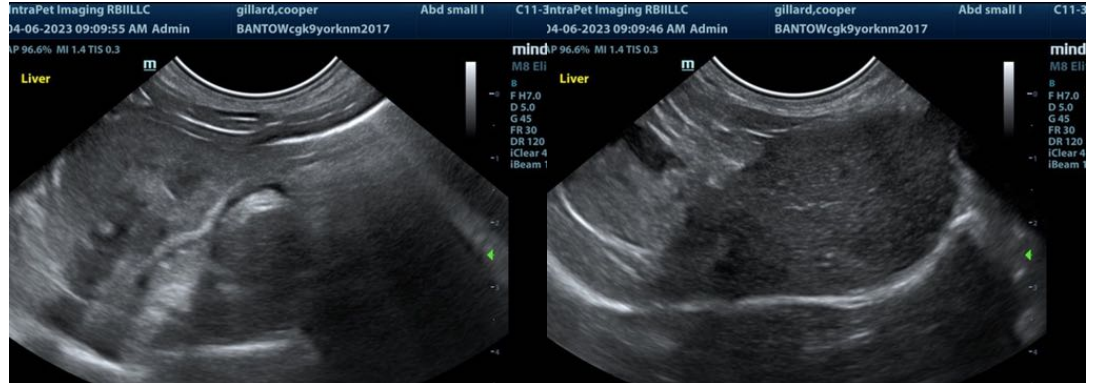
Possible low-grade gastritis or delayed outflow pattern. Luminal gastric structure. Possible dissolving medication or mucosal polyp with a minor potential for foreign matter.

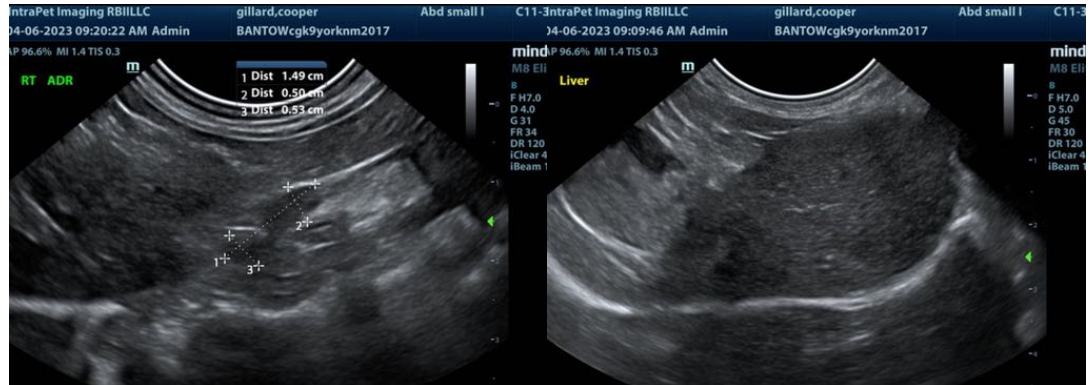
INTERPRETATION OF THE FINDINGS & FURTHER RECOMMENDATIONS

The hepatic clinical sonographic presentation is most consistent with Reactive Hepatopathy which is the most common cause of liver enzyme elevation in dogs and cats. The presumption is that gut and other organ antigen stimuli may be causing a low-grade immune response through portal system with which the liver is reacting to causing low-grade enzyme elevations. US-guided FNA could be performed to assess if low grade lymphoplasmacytic inflammation is present that would support this theory. If FNA is performed, please ask the cytologist to emphasize the primary inflammatory cell type. Empirical treatment measures to address this issue can include diet change to hydrolyzed diet, probiotics, deworming, nutraceuticals (SAME, Actigall...), dental exam and cleaning, and potentially antibiotics such as Clavamox. Metronidazole and Tylosin have traditionally been utilized for this purpose but new studies show that both these antibiotics can disrupt the normal intestinal bacterial flora (intestinal dysbiosis) for weeks and up to 4-6 months. Therefore, Metronidazole and Tylosin should be utilized as a last resort if other efforts have not been effective and sonographic organ appearance remains benign.

Recheck sonogram is recommended in a month.







The information and recommendations provided are based on the images presented by the referring veterinarian. No evaluation can be communicated regarding pathology that was not visible in the image/video clips provided.

Thank you for this referral. If the clinical or image interpretation does not parallel your findings or if I can be of any further assistance please contact me.

Eric Lindquist, DMV, DABVP, Cert. IVUSS, CEO of SonoPath.com
Eric.Lindquist@SonoPath.com