



PATIENT

Teddy Mullaney

PRESENTING CLINICAL SIGNS

Thrombocytopenia, PLT 30k, 4dx neg, fecal neg.
Abnormal PE/Chem/CBC/UA Results: ALP 305, WBC 18.2, MCH 26.8, PLT 29

SPECIES

Canine

ULTRASONOGRAPHIC EXAMINATION OF THE ABDOMEN

Urinary System

BREED

Goldendoodle

The **urinary bladder**, trigone, and pelvic urethra presented normal thicknesses and normal tone. The ureters were not visible which is normal. No uroliths or sediment were visualized and anechoic urine was present. No evidence of inflammatory or neoplastic changes were noted. Ureteral papillae were normal. The residual prostate was uniform at 0.77 cm. The pelvic urethra was imaged 3.0 cm beyond the cystourethral junction.

SEX

Neutered Male

The **kidneys** revealed normal size and structure, corticomedullary definition and ratio for this age. The cortices presented largely uniform texture with normal echogenic relationship to liver and spleen. Medullary structure differed distinctly from the cortex and no evidence of pelvic dilation was present. The capsules were acceptably uniform without significant irregularities. The right kidney measured 6.73 cm. The left kidney measured 6.03 cm.

AGE

5 Years

Adrenal Glands

WEIGHT

78.6 Pounds

Both **adrenal glands** were visualized and recognized as having normal shape, size, position and echogenicity for this breed. The phrenic vasculature, glandular echogenicity and detail were unremarkable. Capsule, cortex, and medullary definition were normal for this age patient. The right adrenal gland measured 2.05 cm x 1.27 cm at the cranial pole and 0.52 cm at the caudal pole. The left adrenal gland measured 2.87 cm x 0.58 cm at the cranial pole and 0.53 cm at the caudal pole.

INTERPRETED BY

Eric Lindquist, DMV

Spleen

DABVP, Cert. IVUSS

The **spleen** presented a smooth homogeneous parenchyma hyperechoic to liver and renal cortical parenchyma. The capsule was smooth without noticeable expansion or deviation from within the spleen or adjacent pathology. The splenic vasculature demonstrated normal volume without signs of congestion or thrombosis. No sonographic evidence of acute or chronic inflammatory, neoplastic, or infarctual changes were noted.

IMAGING PERFORMED BY

Shari Reffi, CVT

Liver

HOSPITAL NAME

Shohola Vet Hospital

The **liver** images submitted revealed subjectively normal liver size, contour, and structure. Parenchymal echogenicity was naturally coarse and hypoechoic to the spleen. Vascular and biliary tracts were of normal volume with no evidence of congestion. The gallbladder presented acceptably thin walls with primarily anechoic content. The cystic and common bile ducts were normal. No pathological hepatic lymphadenopathy was evident. No overt structural evidence of inflammatory, infiltrative or regenerative pathology was evident.

REFERRING VET

Dr. DeMeo

Gastrointestinal

INVOICE

36767

Examination of the **gastrointestinal tract** revealed a stomach and intestine free of stasis, of normal wall thickness, acceptable curvilinear mural detail, and peristaltic activity. Small and large intestine demonstrated normal luminal chyme and stool consistency respectively. No obstructive or overt infiltrative disease was noted. No associated abnormal lymphatic activity was noted.

DATE

4/6/22



PATIENT

Pancreas

Teddy Mullaney

The base and limbs of the **pancreas** were observed to be largely isoechoic to surrounding omental fat. Pancreatic duct and capsular contour were acceptably normal and parenchyma respected normal curvilinear patterns. No overt evidence of active inflammatory or neoplastic disease was noted.

SPECIES

Canine

ULTRASONOGRAPHIC FINDINGS

- Structurally normal abdomen

BREED

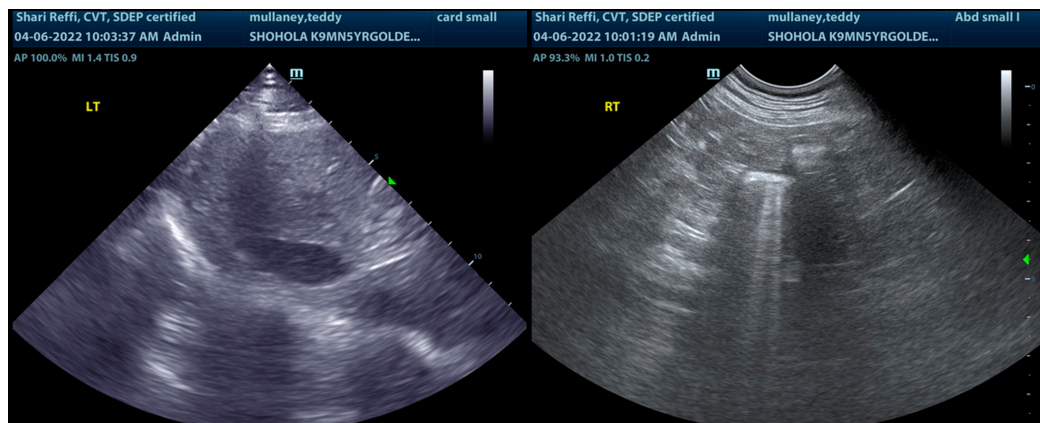
Goldendoodle

INTERPRETATION OF THE FINDINGS & FURTHER RECOMMENDATIONS

The cause of the thrombocytopenia is not related to any visceral disease. CBC path review +/- bone marrow aspirate would be appropriate. Immune mediated versus infectious agents, ehrlichia titers would be appropriate. Doxycycline trial would be appropriate.

SEX

Neutered Male



AGE

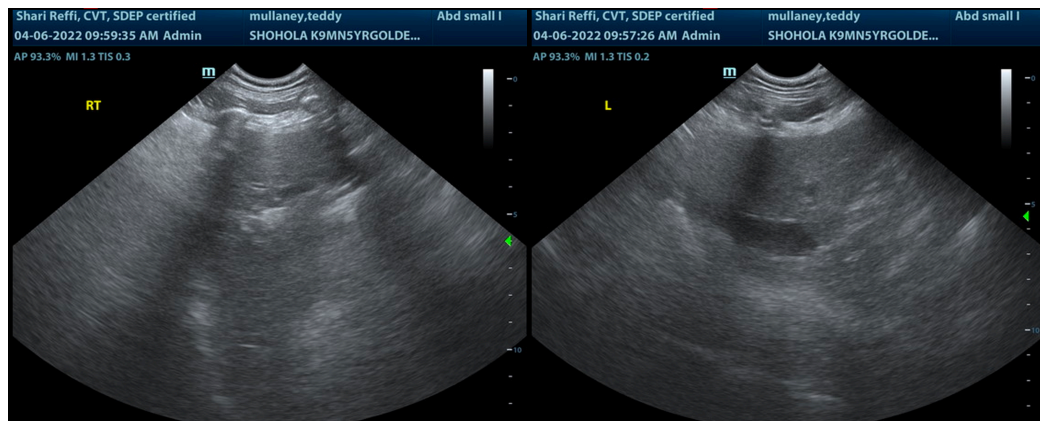
5 Years

WEIGHT

78.6 Pounds

INTERPRETED BY

Eric Lindquist, DMV



DABVP, Cert. IVUSS

IMAGING PERFORMED BY

Shari Reffi, CVT

HOSPITAL NAME

Shohola Vet Hospital

REFERRING VET

Dr. DeMeo

INVOICE

36767

DATE

4/6/22



PATIENT

Teddy Mullaney

SPECIES

Canine

BREED

Goldendoodle

SEX

Neutered Male

AGE

5 Years

WEIGHT

78.6 Pounds

INTERPRETED BY

Eric Lindquist, DMV

DABVP, Cert. IVUSS

IMAGING PERFORMED BY

Shari Reffi, CVT

HOSPITAL NAME

Shohola Vet Hospital

REFERRING VET

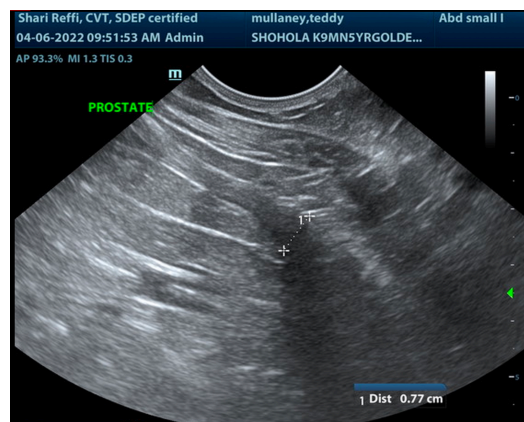
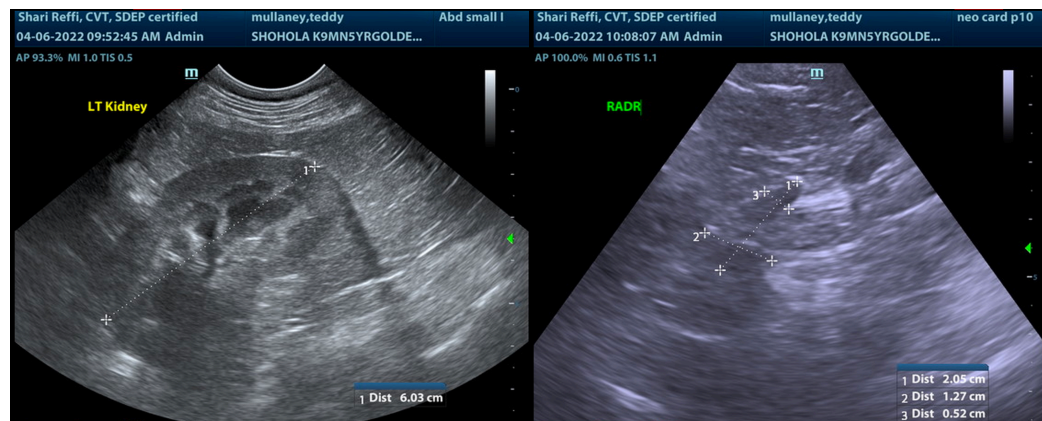
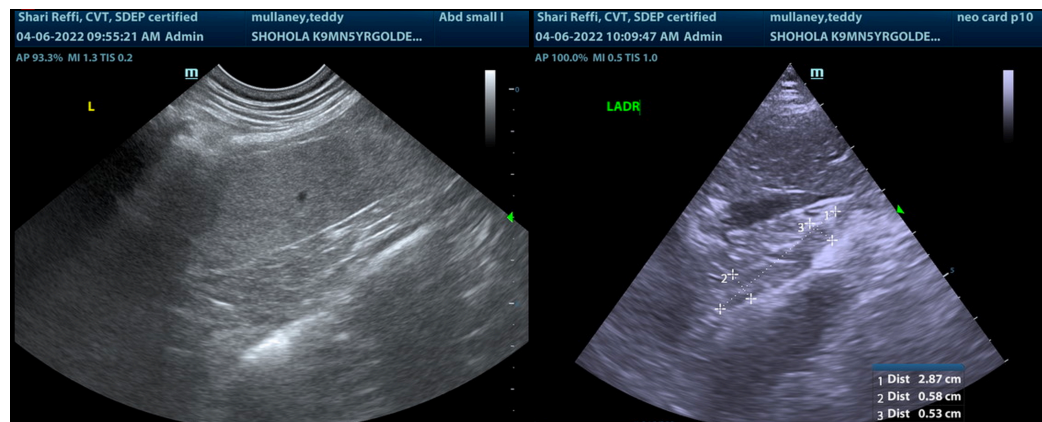
Dr. DeMeo

INVOICE

36767

DATE

4/6/22



The information and recommendations provided are based on the images presented by the referring veterinarian/sonographer. No evaluation can be communicated regarding pathology that was not visible in the image/video clips provided.

Thank you for this referral. If the clinical or image interpretation does not parallel your findings or if I can be of any further assistance please contact me.

Eric Lindquist, DMV, DABVP, Cert. IVUSS, CEO of SonoPath.com

info@SonoPath.com